

Case studies of children and adults with atopic eczema being treated under the Aron Regimen

Prepared by: Parents of patients of Dr Richard Aron (GMC ref no. 3151727)
September 2017

Dr Aron's website: www.draron.com

Other relevant websites: www.eczemasense.org
www.draroneczema.wordpress.com

Facebook support group for patients undergoing or interested in Dr Aron's treatment regime: <https://www.facebook.com/groups/draron/>

Email enquiries on case studies: aronregimen@gmail.com

Please note: with the exception of Dr Aron's website, the rest of the above are run by parents of patients of Dr Aron and not by Dr Aron himself.

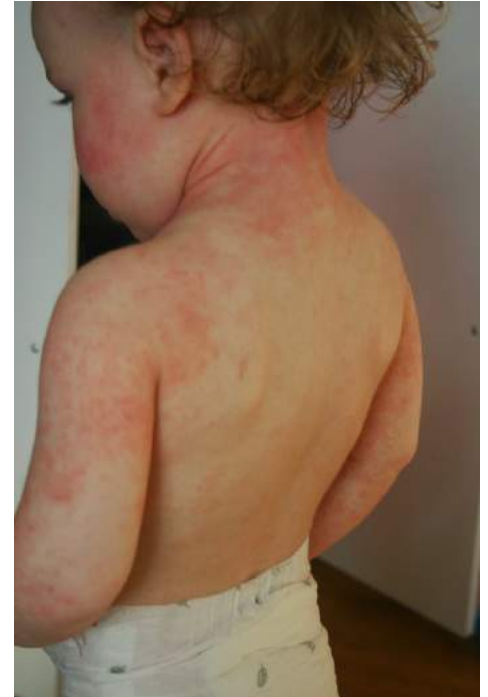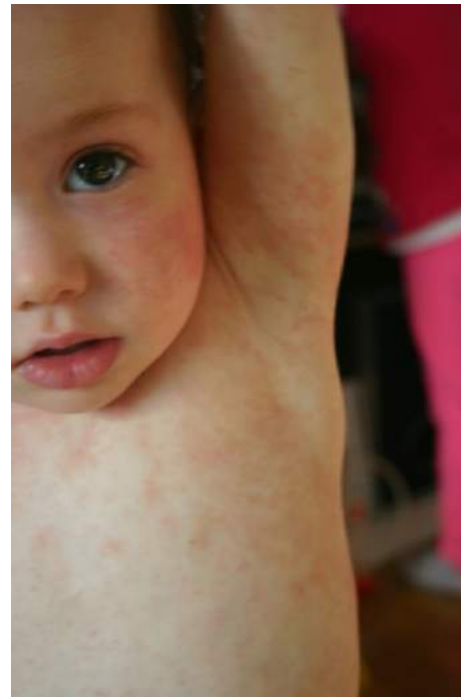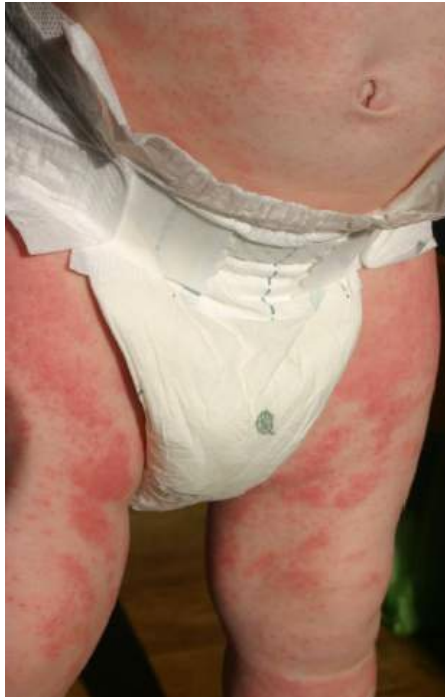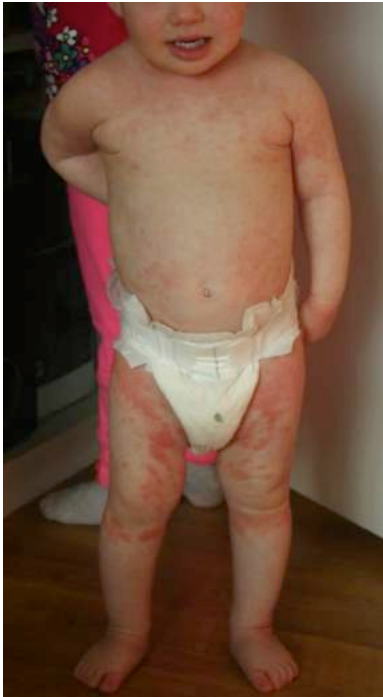Case study 1 (Dec 2014)

Female, aged 20 months when started on Aron Regimen

Prior to commencing Aron Regimen	Age when diagnosed with atopic eczema	8 months
	Under treatment of GP or Dermatologist prior to commencing Aron Regimen	GP
	Most recent treatment prior to commencing Aron Regimen (immunosuppressants: any time; rest: previous year)	Topical steroids: Betnovate, Eumovate, Hydrocortisone 1% Oral steroids: No Topical immunosuppressants: No Oral immunosuppressants: No Antihistamines: No
	Any hospital emergency or elective admissions related to atopic eczema since diagnosis? If yes, how many?	No
	Any absences from school due to eczema (other than clinic appointments)?	N/A
Since commencing Aron Regimen	Date started the Aron Regimen	Feb 2014
	Current treatment	September 2017: Crooks of elbows/behind knees and on fingers, used random and infrequent September 2016: A few fingers only now, 2-3 x per week February 2016: Hands 2-3 x per week, nowhere else. Treat flares as necessary. July 2015: Only only small areas (hands/wrists, left ankle, right knee) every 3 days Feb 2015: Antibiotic removed from the mix Dec 2014: Applied once every 3 days Mix of steroid, antibiotic and moisturiser creams
	Any hospital emergency or elective admissions related to atopic eczema since commencing Aron Regimen?	No
	Any absences from school due to eczema (other than clinic appointments or initial week of Aron Regimen)?	N/A

Case study 1 – female, aged 20 months

Photos before commencing Aron Regimen

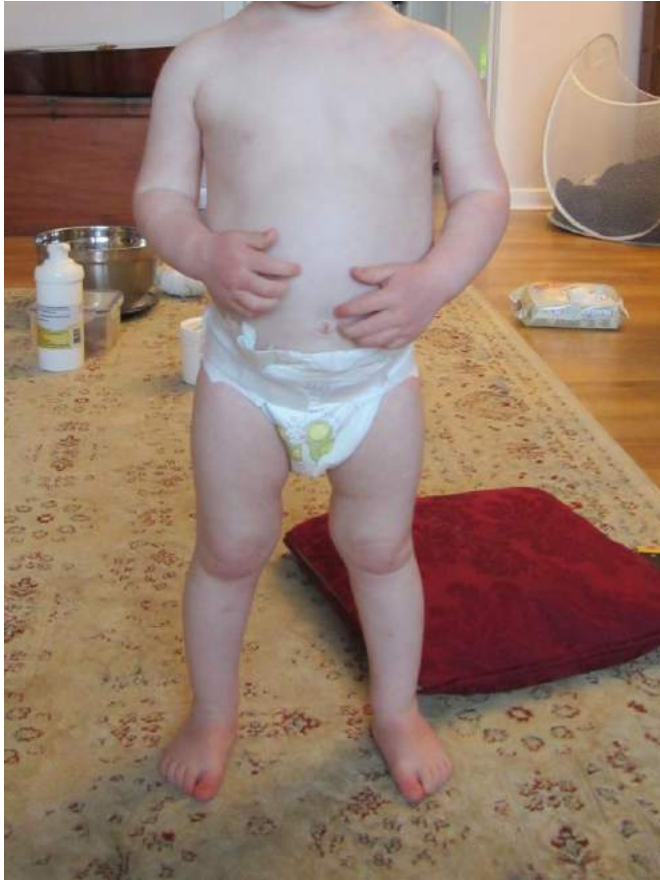

Note from parents:

She was covered head to ankle and could not sleep more than 2 hours at a time. We were all miserable.

Case study 1 – female, aged 20 months

Photos after commencing Aron Regimen



Note from parents:

She sleeps all night, every night. Flares are manageable and she is happy.

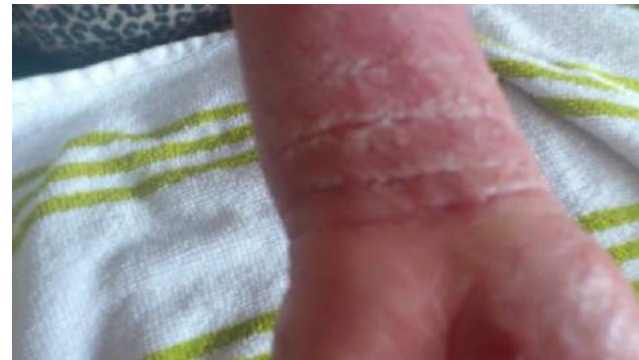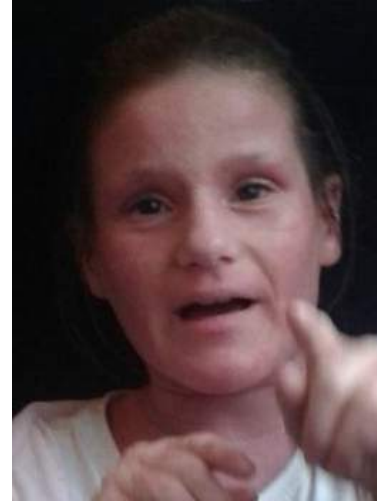
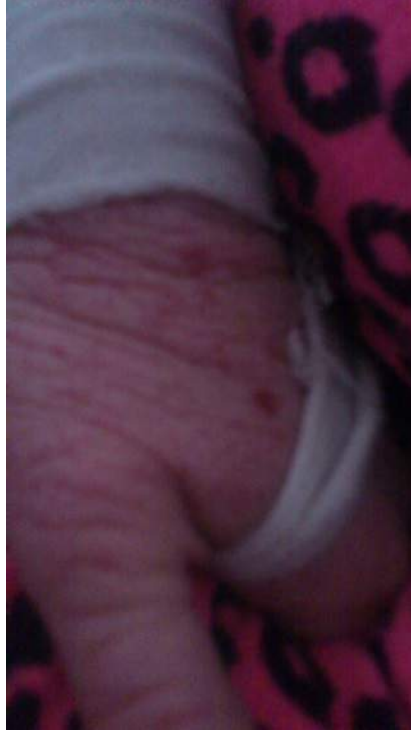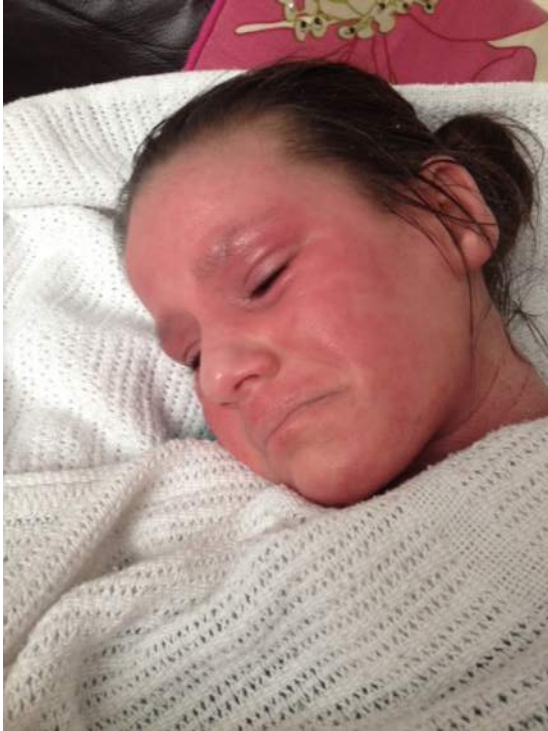Case study 2 (Dec 2014)

Female, aged 12 when started on Aron Regimen

Prior to commencing Aron Regimen	Age when diagnosed with atopic eczema	3 months
	Under treatment of GP or Dermatologist prior to commencing Aron Regimen	Dermatologist
	Most recent treatment prior to commencing Aron Regimen (immunosuppressants: any time; rest: previous year)	Topical steroids: Elocon Oral steroids: Predisonole Topical immunosuppressants: Protopic Oral immunosuppressants: No Antihistamines: Yes
	Any hospital emergency or elective admissions related to atopic eczema since diagnosis? If yes, how many?	Yes, 8 admissions
	Any absences from school due to eczema (other than clinic appointments)?	Yes
Since commencing Aron Regimen	Date started the Aron Regimen	Jan 2014
	Current treatment	September 2017: 1 app per day legs/arms and face September 2016: 1 app per day over summer due to allergens February 2016: Just used for flares now July 2015: Applied twice per week all over body Feb 2015: No. of applications reduced to twice a week on legs/lower body and 3 times a week on top half/face Dec 2014: Applied twice a day to body and once every 2 days to face Mix of steroid, antibiotic and moisturiser creams
	Any hospital emergency or elective admissions related to atopic eczema since commencing Aron Regimen?	No
	Any absences from school due to eczema (other than clinic appointments or initial week of Aron Regimen)?	No

Case study 2 – female, aged 12

Photos before commencing Aron Regimen

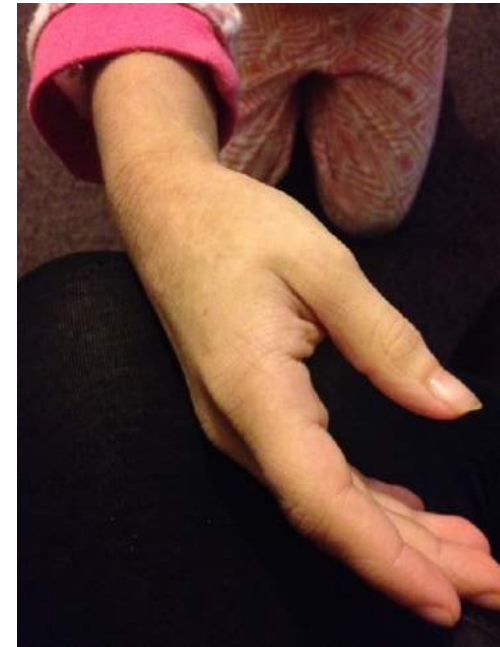
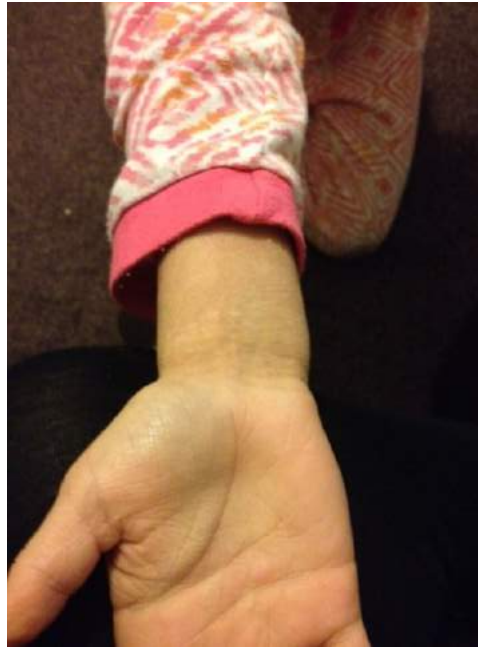
Note from parents:

Constantly flared skin. Constant itch. No sleep. Unable to attend school. Massive impact on family. No quality of life.

Case study 2 – female, aged 12

Photos after commencing Aron Regimen



Note from parents:

No itch. Normal family life. Normal sleep. Back to school full time. Normal quality of life.

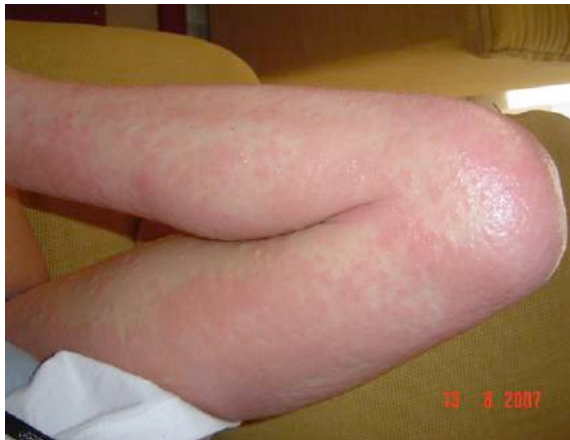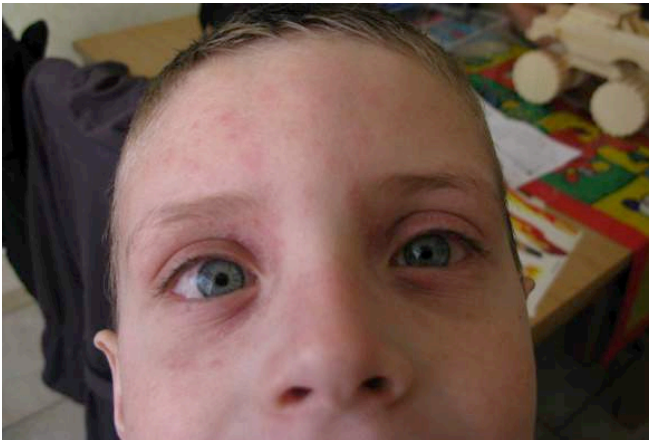
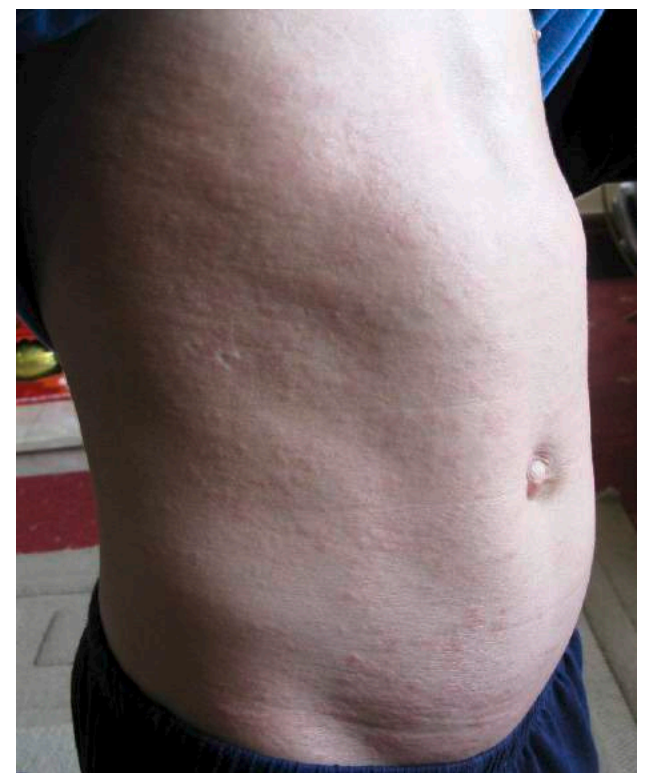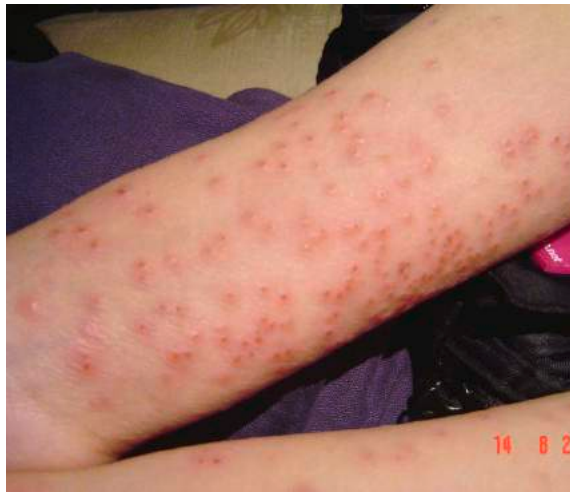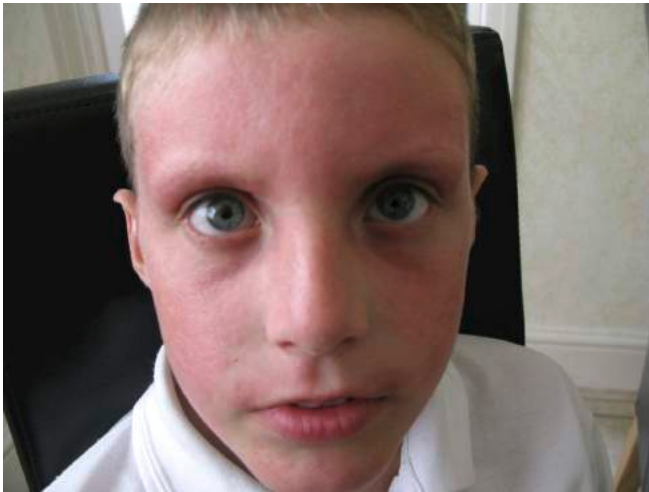
Case study 3 (August 2015)

Male, aged 8 years when started on Aron Regimen

Prior to commencing Aron Regimen	Age when diagnosed with atopic eczema	First few weeks of life
	Under treatment of GP or Dermatologist prior to commencing Aron Regimen	Dermatologist
	Most recent treatment prior to commencing Aron Regimen (immunosuppressants: any time; rest: previous year)	Topical steroids: Eumovate, Lociod Oral steroids: Yes Topical immunosuppressants: Yes Oral immunosuppressants: No Antihistamines: Yes
	Any hospital emergency or elective admissions related to atopic eczema since diagnosis? If yes, how many?	Yes – 4 or more admissions
	Any absences from school due to eczema (other than clinic appointments)?	Yes
Since commencing Aron Regimen	Date started the Aron Regimen	April 2008
	Current treatment	September 2017: still as below September 2016: still as below, in remission Use of creams ceased 2010 (except for flares). Now just Diprobase and antihistamine. Mix of steroid, antibiotic and moisturiser creams
	Any hospital emergency or elective admissions related to atopic eczema since commencing Aron Regimen?	No
	Any absences from school due to eczema (other than clinic appointments or initial week of Aron Regimen)?	Yes

Case study 3 – male, aged 8 years

Photos before commencing Aron Regimen



Note from parents:

He was a sad, itchy, tired, unhealthy little boy who told me he hated his life. Constant infections and relentless itching!

Case study 3 – male, 8 years

Photos after commencing Aron Regimen



Note from parents:

He slept through very soon after starting with Dr Aron. He had energy and grew more confident. He became sociable, no severe itchiness and thriving! Any flares soon brought under control but his eczema currently in remission and he's HAPPY! Looking forward to his future!

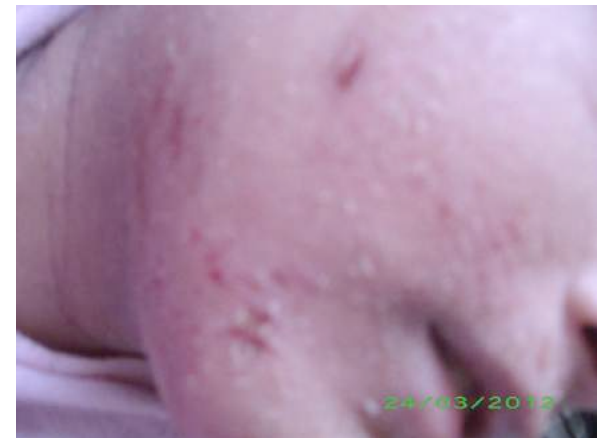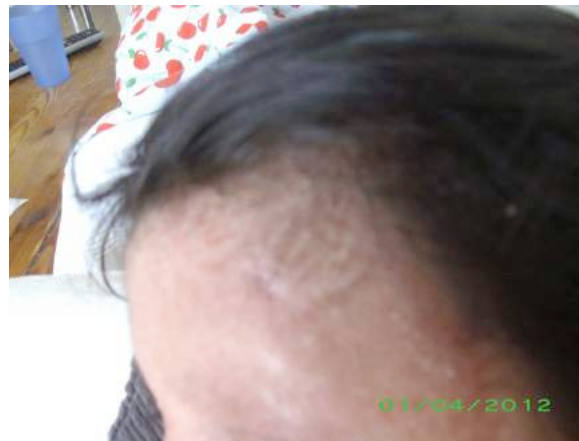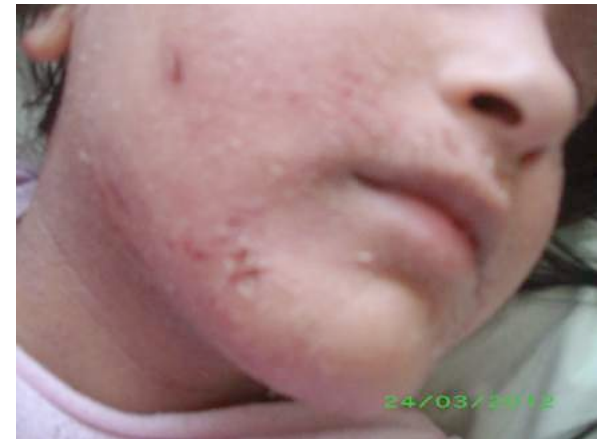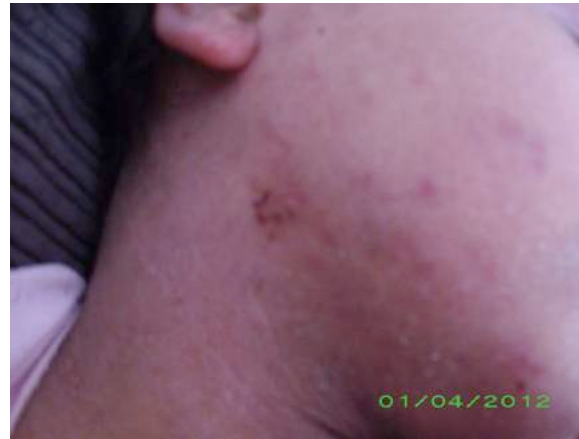Case study 4 (August 2015)

Female, aged 8 years, 11 months when started on Aron Regimen

Prior to commencing Aron Regimen	Age when diagnosed with atopic eczema	2 years
	Under treatment of GP or Dermatologist prior to commencing Aron Regimen	GP
	Most recent treatment prior to commencing Aron Regimen (immunosuppressants: any time; rest: previous year)	Topical steroids: Eumovate Cream, Elocon, Trimovate Ointment Oral steroids: No Topical immunosuppressants: Yes. Elidel Protopic used very briefly, discontinued due to burning sensation. Oral immunosuppressants: No Antihistamines: Yes
	Any hospital emergency or elective admissions related to atopic eczema since diagnosis? If yes, how many?	Yes - 2 admissions
	Any absences from school due to eczema (other than clinic appointments)?	Yes
Since commencing Aron Regimen	Date started the Aron Regimen	April 2012
	Current treatment	September 2017: Still in remission September 2016: Still in remission, no creams used Use of creams ceased October 2012 Mix of steroid, antibiotic and moisturiser creams
	Any hospital emergency or elective admissions related to atopic eczema since commencing Aron Regimen?	No
	Any absences from school due to eczema (other than clinic appointments or initial week of Aron Regimen)?	No

Case study 4 – female, aged 8 years, 11 months


Photos before commencing Aron Regimen



Note from parents:

No quality of life. Child did not want to go on living. We were in Hell.

Case study 4 – female, 8 years, 11 months
Photos after commencing Aron Regimen



Note from parents:

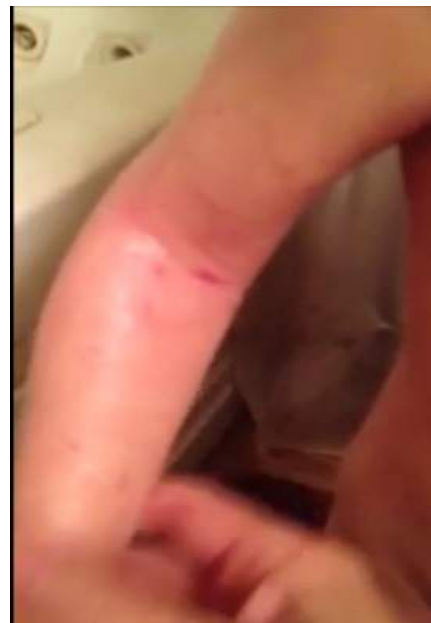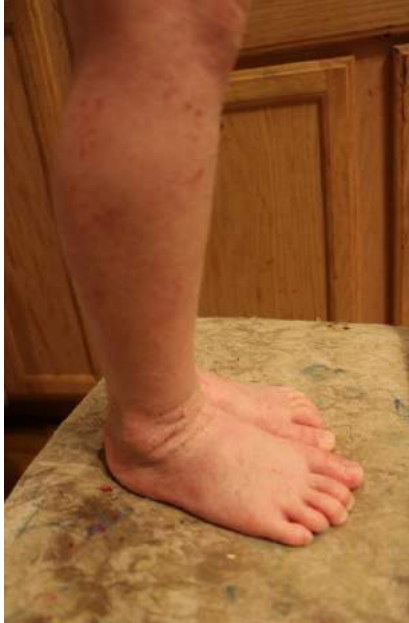A miraculous rebirth of my child within 24 hours. No itching, sleeping properly, concentration improved at school, healthy, happy and thriving.

Case study 5 (Feb 2015)

Male, aged 5½ when started on Aron Regimen

Prior to commencing Aron Regimen	Age when diagnosed with atopic eczema	8 weeks
	Under treatment of GP or Dermatologist prior to commencing Aron Regimen	Dermatologist
	Most recent treatment prior to commencing Aron Regimen (immunosuppressants: any time; rest: previous year)	Topical steroids: Desoximetasone 0.05% Oral steroids: Yes Topical immunosuppressants: No Oral immunosuppressants: No Antihistamines: Yes
	Any hospital emergency or elective admissions related to atopic eczema since diagnosis? If yes, how many?	Yes, 5 admissions
	Any absences from school due to eczema (other than clinic appointments)?	N/A
Since commencing Aron Regimen	Date started the Aron Regimen	Nov 2013
	Current treatment	September 2017: In remission September 2016: Use of cream ceased February 2016: Used the cream once in January 2016 and that's all. July 2015: 1-2 times every couple of weeks Feb 2015: Applied once every 2 weeks in the winter as his skin is drier (applied no cream for 3 months in summer 2014) Mix of steroid, antibiotic and moisturiser creams
	Any hospital emergency or elective admissions related to atopic eczema since commencing Aron Regimen?	No
	Any absences from school due to eczema (other than clinic appointments or initial week of Aron Regimen)?	No

Case study 5 – male, aged 5½
Photos before commencing Aron Regimen

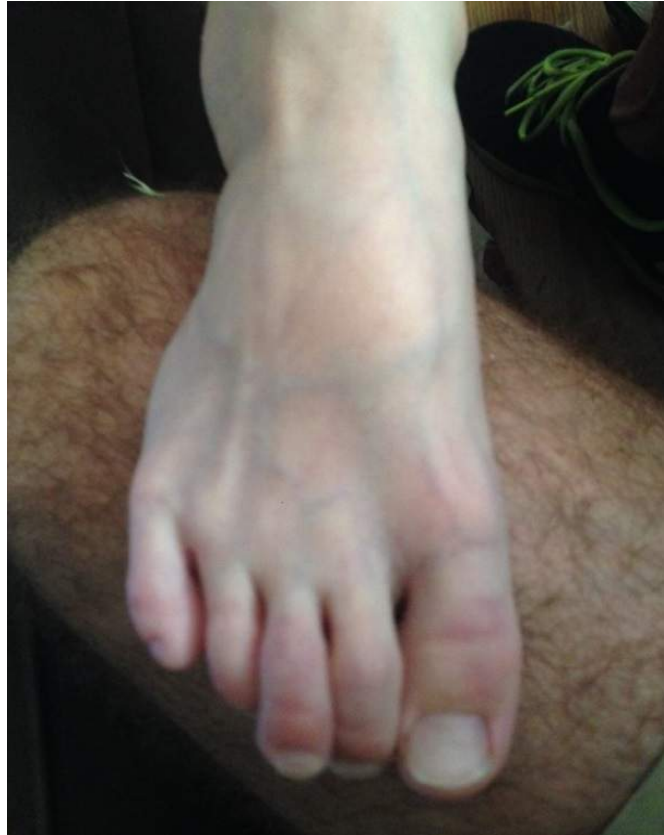
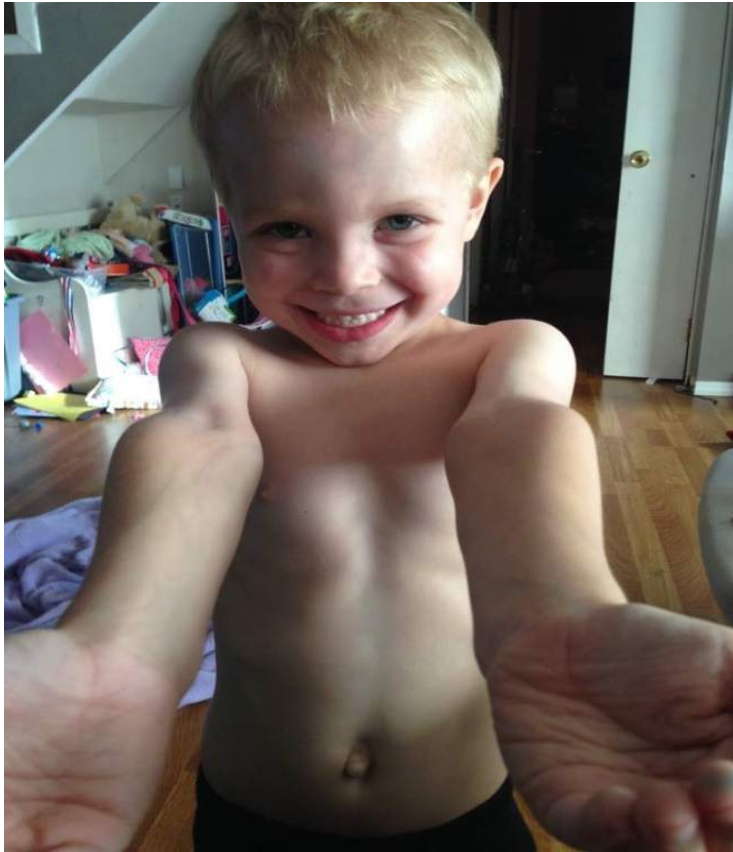

Note from parents:

My son suffered with full-body eczema since birth and always complained of the burning, itching and pain, rarely sleeping more than 2 or 3 hours at a time without waking and scratching for long periods. We had many trips to urgent care and the hospital when the pain seemed too much for him to bear.

Case study 5 – male, aged 5½

Photos after commencing Aron Regimen



Note from parents:

In the first week, my son was sleeping through the entire night on consecutive nights, which he had never previously done since birth. The itching and scratching went from very severe to very mild in the first 48 hours and only continued to get better every month.

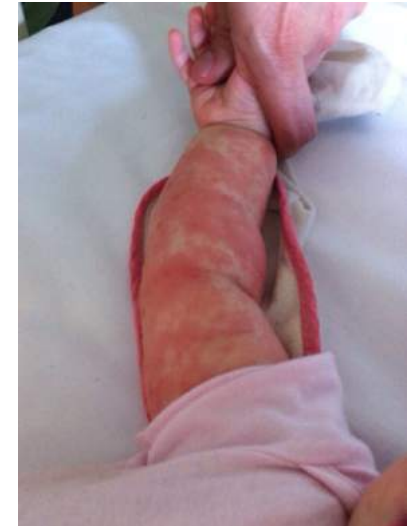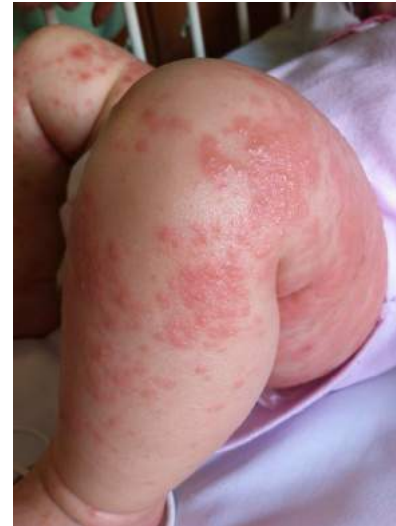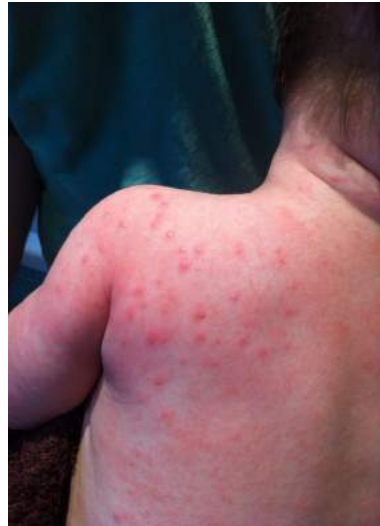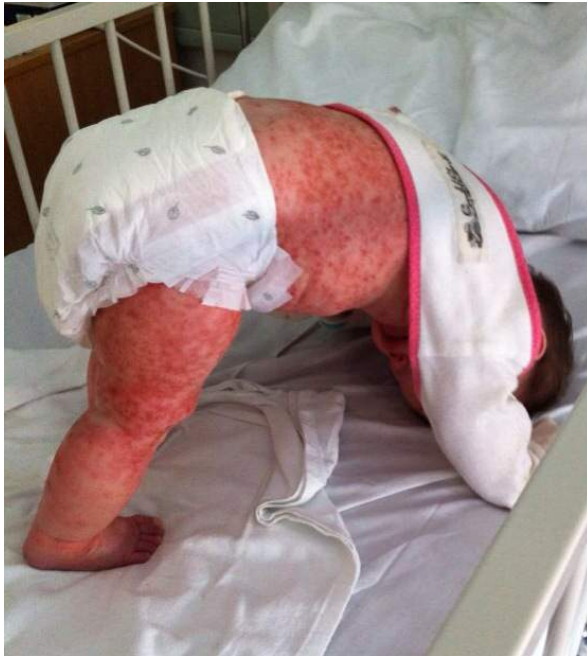Case study 6 (Feb 2015)

Female, aged 9 months when started on Aron Regimen

Prior to commencing Aron Regimen	Age when diagnosed with atopic eczema	8 weeks
	Under treatment of GP or Dermatologist prior to commencing Aron Regimen	GP
	Most recent treatment prior to commencing Aron Regimen (immunosuppressants: any time; rest: previous year)	Topical steroids: Hydrocortisone 1% Oral steroids: No Topical immunosuppressants: No Oral immunosuppressants: No Antihistamines: Yes
	Any hospital emergency or elective admissions related to atopic eczema since diagnosis? If yes, how many?	Yes, 2 admissions
	Any absences from school due to eczema (other than clinic appointments)?	N/A
Since commencing Aron Regimen	Date started the Aron Regimen	Sept 2013
	Current treatment	September 2017: Spot treating and further dilution of steroid September 2016: Spot treating only 1-2 apps per week February 2016: Diluted from 1:7 to 1:10 (steroid-moisturizer). No antibiotic in it. This has been since September 2015. Applied 1 x day. Eye area, only when flares up (with eye cream) July 2015: Applied every 2-3 days. Eye area -1 x weekly Feb 2015: Applied once every 3 days Mix of steroid, antibiotic and moisturiser creams Special cream for eyelid and eye area (1-2 times per month as maintenance)
	Any hospital emergency or elective admissions related to atopic eczema since commencing Aron Regimen?	N/A
	Any absences from school due to eczema (other than clinic appointments or initial week of Aron Regimen)?	No

Case study 6 – female, aged 9 months

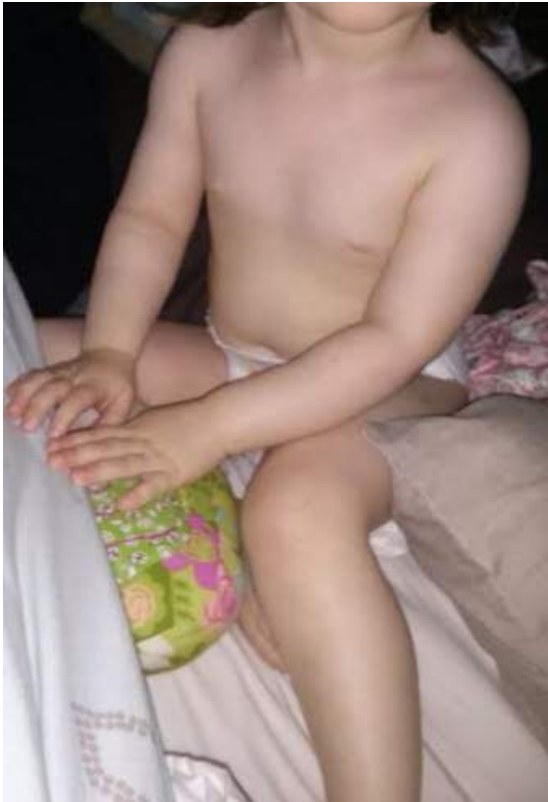Photos before commencing Aron Regimen



Note from parents:

Constant itch; hands covered 24 hours; bad temperament and only focused on scratching. Sleep deprived even under antihistamines twice a day for a 6 month old baby when they are not recommended to give before 1 year of age (so her mood was completely affected as she was dizzy and constantly sleepy). Very irritable. Not being able to learn how to grab things as her hands were covered. Not enough appetite. Not being able to stand on grass, nor crawling on the floor.

Case study 6 – female, aged 9 months (now 27 months) Photos after commencing Aron Regimen



Note from parents:

Itching immediately stopped. Sleeping improved since day 2. Brighter eyesight and laughing and enjoying life for the first time. My daughter started showing her true self and interest for things she wasn't before. Was surprised at seeing her hands and enjoyed starting to grab things. Her knowledge of everyday activities and playtime increased enormously.

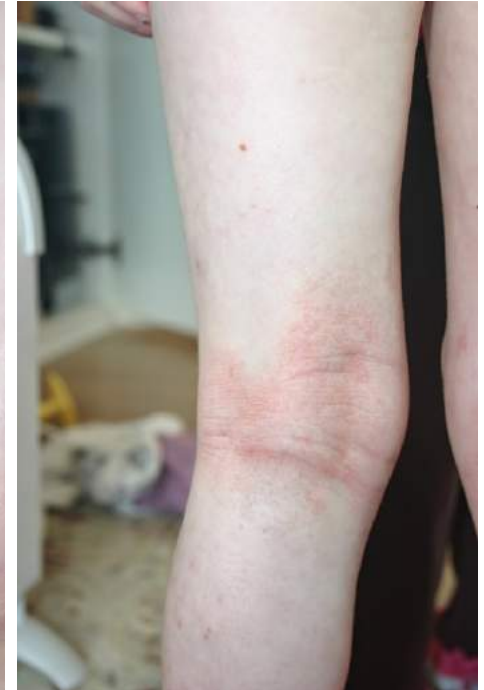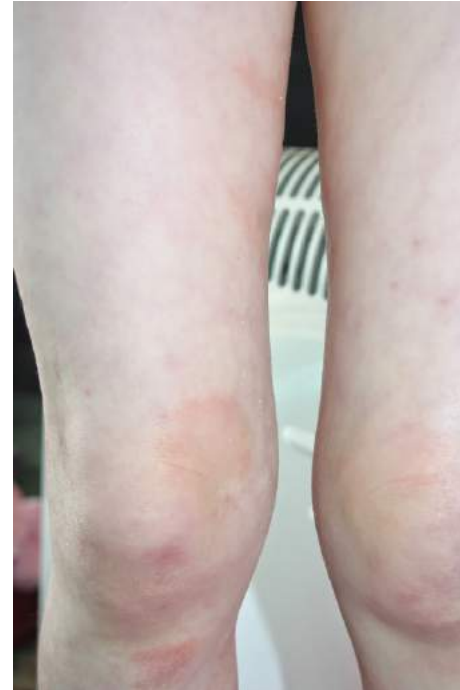
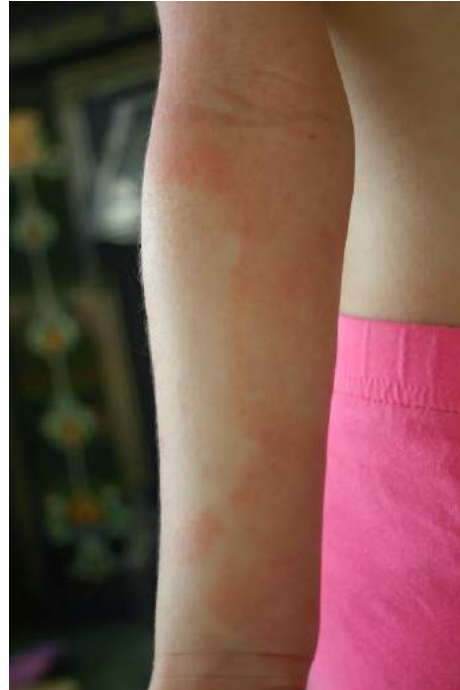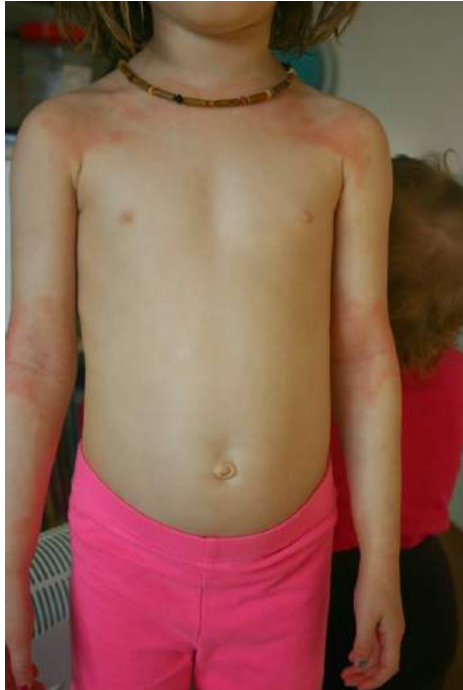Case study 7 (Dec 2014)

Female, aged 4½ when started on Aron Regimen

Prior to commencing Aron Regimen	Age when diagnosed with atopic eczema	6 months
	Under treatment of GP or Dermatologist prior to commencing Aron Regimen	GP
	Most recent treatment prior to commencing Aron Regimen (immunosuppressants: any time; rest: previous year)	Topical steroids: Betnovate, Eumovate, Hydrocortisone 1% Oral steroids: No Topical immunosuppressants: No Oral immunosuppressants: No Antihistamines: No
	Any hospital emergency or elective admissions related to atopic eczema since diagnosis? If yes, how many?	No
	Any absences from school due to eczema (other than clinic appointments)?	No
Since commencing Aron Regimen	Date started the Aron Regimen	Feb 2014
	Current treatment	September 2017: Still in remission September 2016: Still in remission July 2015: Still no cream used Feb 2015: Regular use of cream ceased altogether Dec 2014: Applied once every 5 days to elbows, lower arms/wrists, upper legs and buttocks Mix of steroid, antibiotic and moisturiser creams
	Any hospital emergency or elective admissions related to atopic eczema since commencing Aron Regimen?	No
	Any absences from school due to eczema (other than clinic appointments or initial week of Aron Regimen)?	No

Case study 7 – female, aged 4½

Photos before commencing Aron Regimen

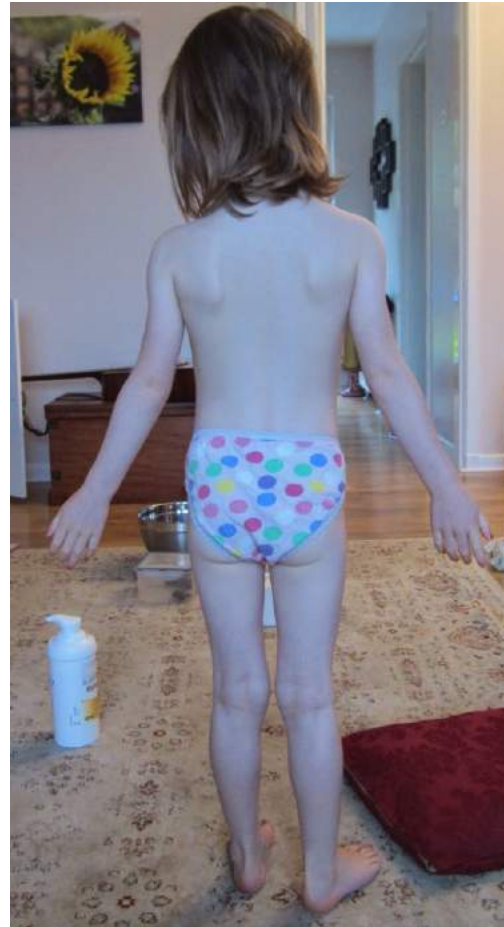
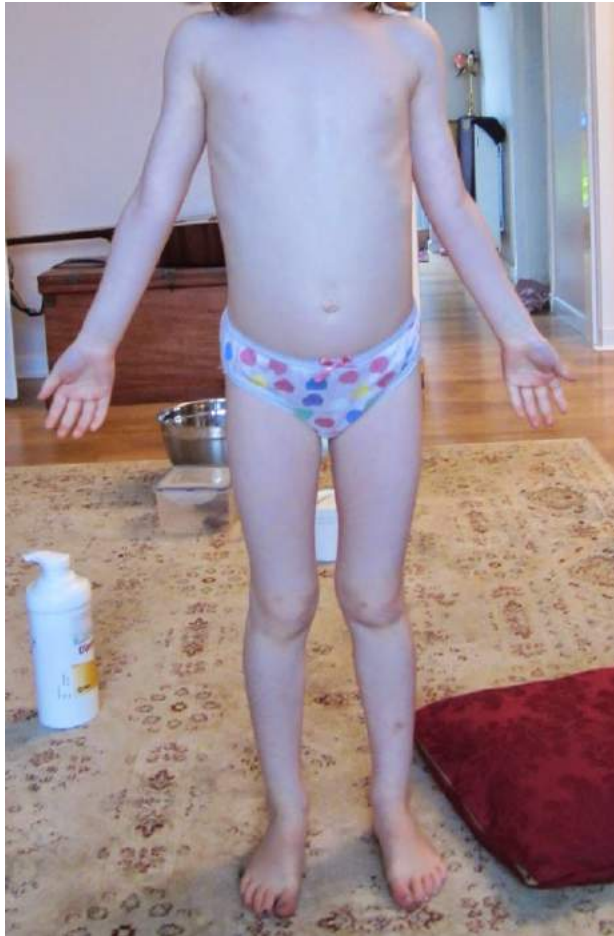
Note from parents:

She was constantly scratching and being told not to scratch. We could not stop the steroid without terrible rebound. The eczema was spreading to places she had never had it and it was breaking through even whilst on steroid treatment.

Case study 7 – female, age 4½

Photos after commencing Aron Regimen



Note from parents:

She is transformed. She hasn't had a spot of eczema for 9 months and appears to be in remission.

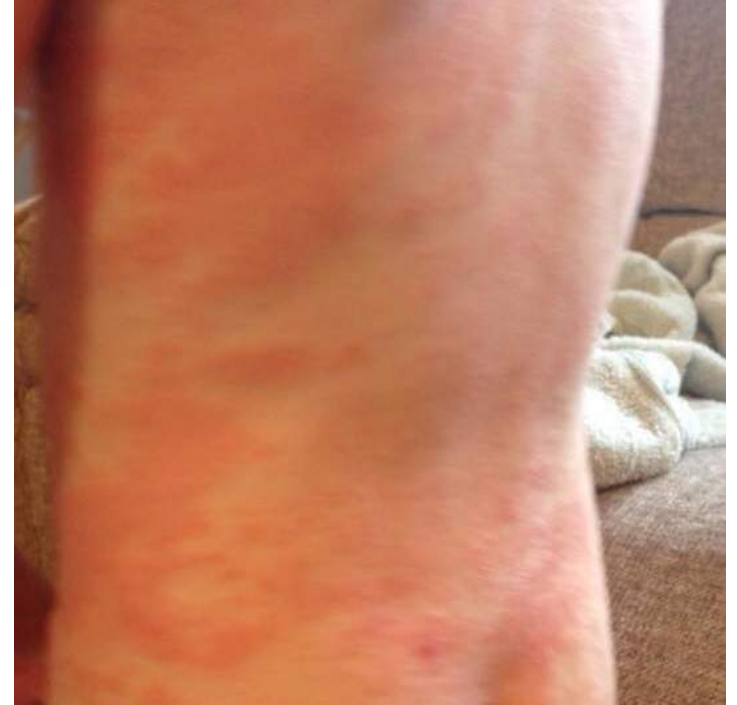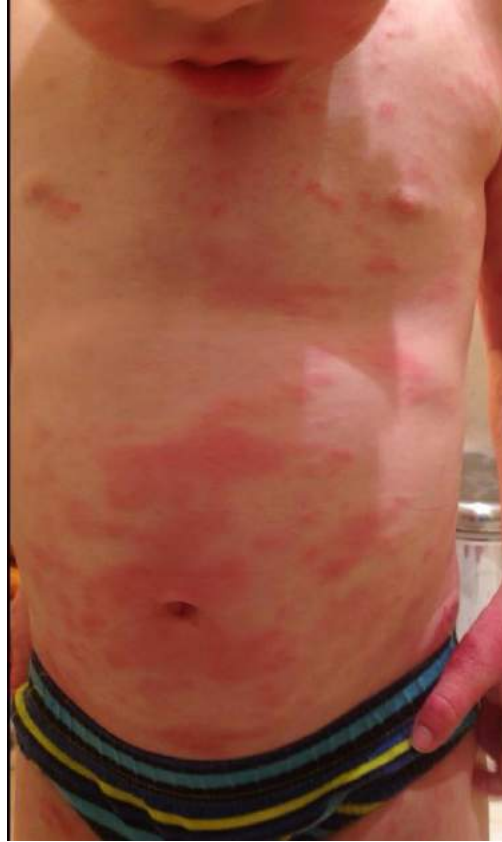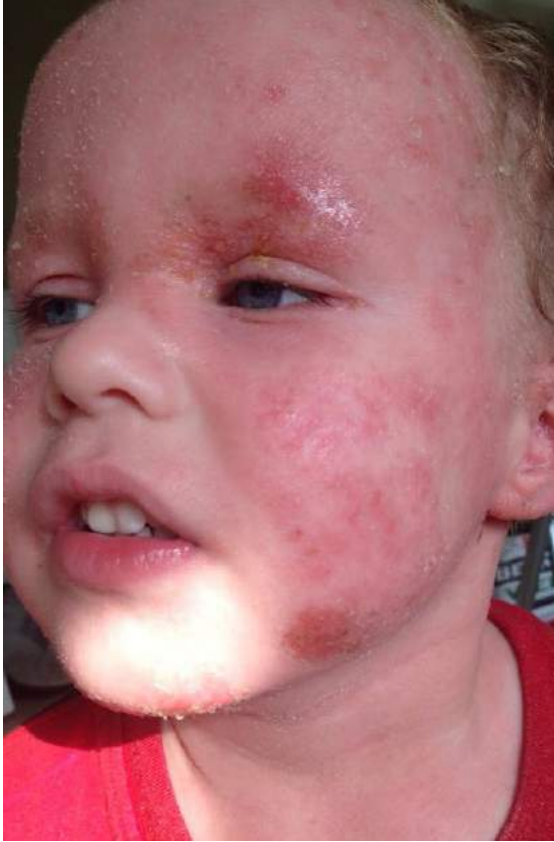Case study 8 (Dec 2014)

Male, aged 4 when started on Aron Regimen

Prior to commencing Aron Regimen	Age when diagnosed with atopic eczema	3 months
	Under treatment of GP or Dermatologist prior to commencing Aron Regimen	Dermatologist
	Most recent treatment prior to commencing Aron Regimen (immunosuppressants: any time; rest: previous year)	Topical steroids: Betnovate, Eumovate, Hydrocortisone Oral steroids: No Topical immunosuppressants: No Oral immunosuppressants: No Antihistamines: No
	Any hospital emergency or elective admissions related to atopic eczema since diagnosis? If yes, how many?	No
	Any absences from school due to eczema (other than clinic appointments)?	Yes
Since commencing Aron Regimen	Date started the Aron Regimen	Sept 2014
	Current treatment	September 2017: Spot treating as required, fingers more often (currently flaring) September 2016: Applied 1 x daily to legs and arms only, the rest of the body nothing February 2016: Nothing on body, applied every 3rd day on legs/arms July 2015: Nothing on body, applied every 2 nd day on legs/arms Feb 2015: No. of applications reduced to once a day December 2014: Applied 1-2 times a day Mix of steroid, antibiotic and moisturiser creams
	Any hospital emergency or elective admissions related to atopic eczema since commencing Aron Regimen?	No
	Any absences from school due to eczema (other than clinic appointments or initial week of Aron Regimen)?	No

Case study 8 – male, aged 4

Photos before commencing Aron Regimen

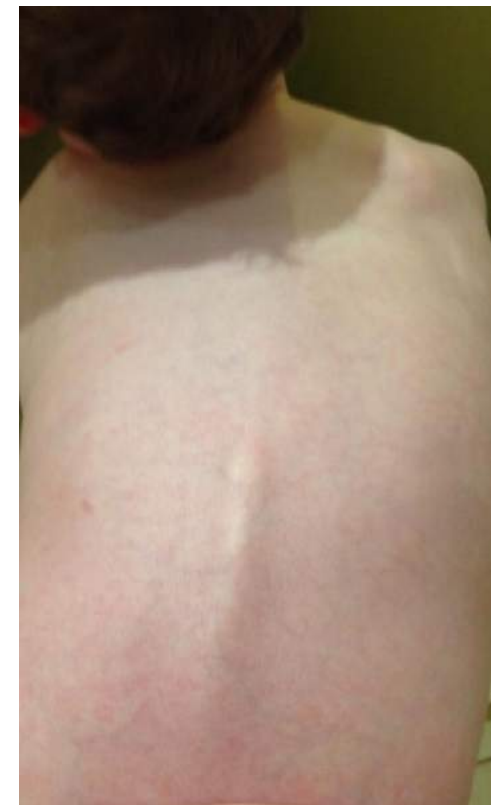
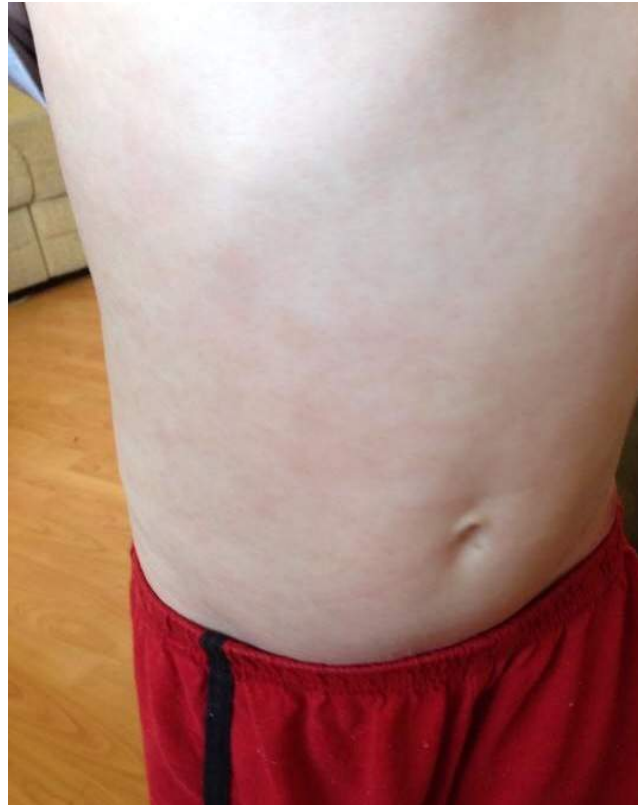
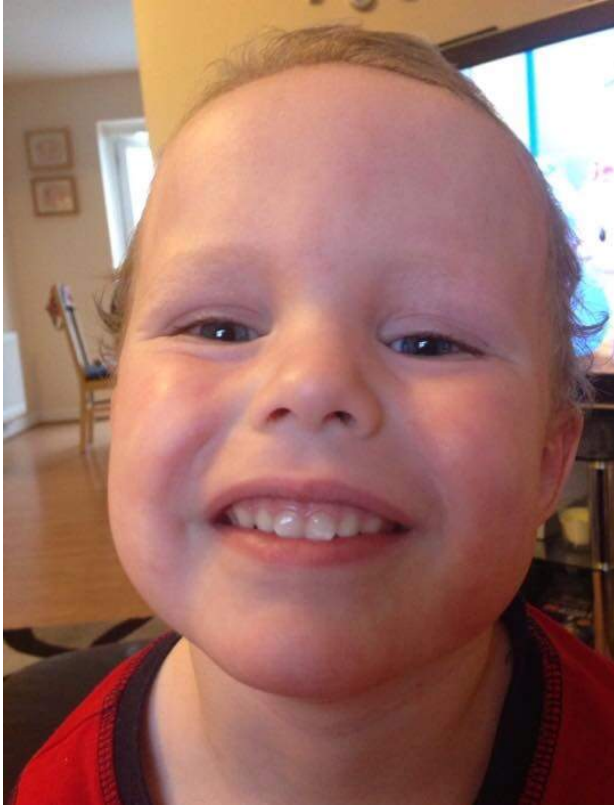
Note from parents:

My son was constantly itching, had little sleep, sore weeping skin, lack of appetite and he would cry over little things. Our night time routine would take an hour due to bandaging him before bed.

Case study 8 – male, aged 4

Photos after commencing Aron Regimen



Note from parents:

He very rarely itches now, he has uninterrupted sleep, a great appetite and he is a much happier child. His skin is soft and clear other than stubborn areas like ankles and wrists/fingers and no more bandaging at night.

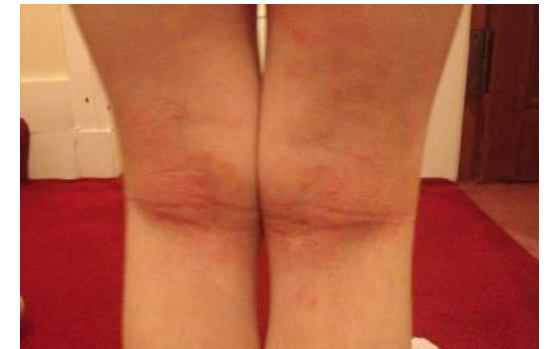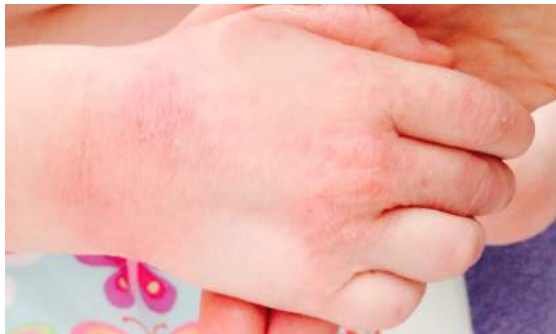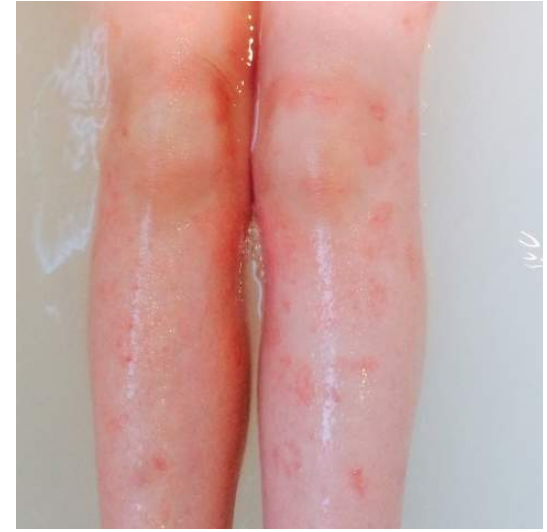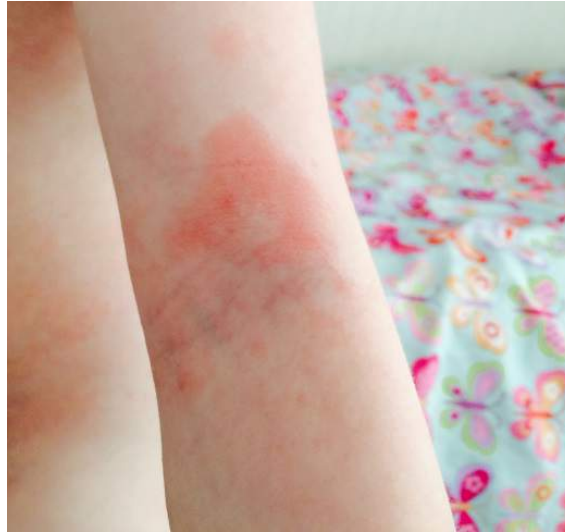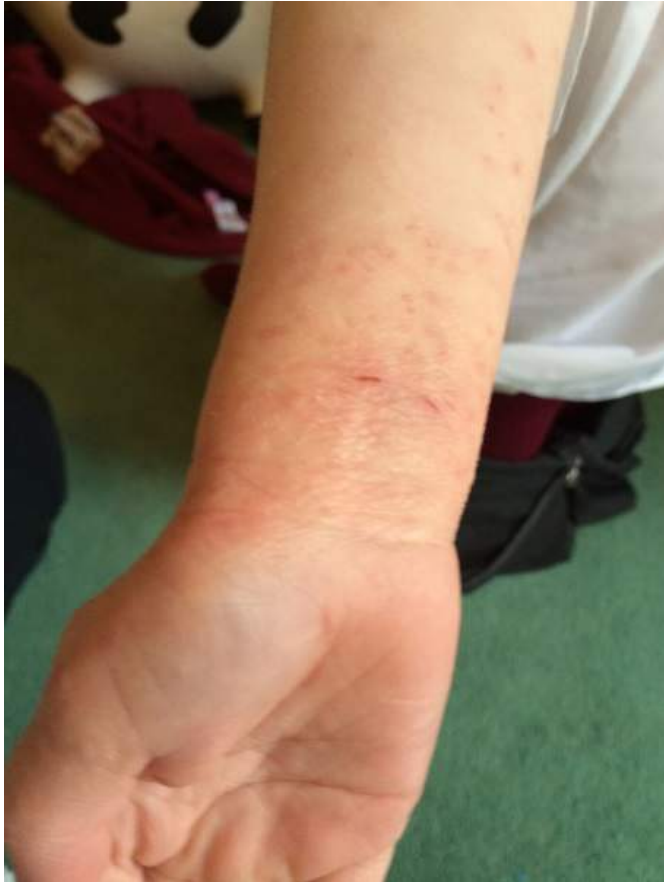Case study 9 (Dec 2014)

Female, aged 5 when started on Aron Regimen

Prior to commencing Aron Regimen	Age when diagnosed with atopic eczema	3 months
	Under treatment of GP or Dermatologist prior to commencing Aron Regimen	Dermatologist
	Most recent treatment prior to commencing Aron Regimen (immunosuppressants: any time; rest: previous year)	Topical steroids: Elocon Oral steroids: No Topical immunosuppressants: No Oral immunosuppressants: No Antihistamines: Yes
	Any hospital emergency or elective admissions related to atopic eczema since diagnosis? If yes, how many?	No
	Any absences from school due to eczema (other than clinic appointments)?	No
Since commencing Aron Regimen	Date started the Aron Regimen	July 2014
	Current treatment	September 2017: Same, applied every 9 days to body, fingers 2 x weekly September 2016: Applied every 9 days to body, fingers 2 x weekly February 2016: Applied 1 x weekly to body, 3 x weekly to fingers July 2015: Antibiotic removed. Applied 1 x weekly to body, 3 x weekly to fingers Feb 2015: No. of applications reduced to once every 6 days to torso & back and once every 3 days to arms & legs December 2014: Applied once every 4 days to torso & back and once a day to arms & legs Mix of steroid, antibiotic and moisturiser creams
	Any hospital emergency or elective admissions related to atopic eczema since commencing Aron Regimen?	No
	Any absences from school due to eczema (other than clinic appointments or initial week of Aron Regimen)?	No

Case study 9 – female, aged 5

Photos before commencing Aron Regimen

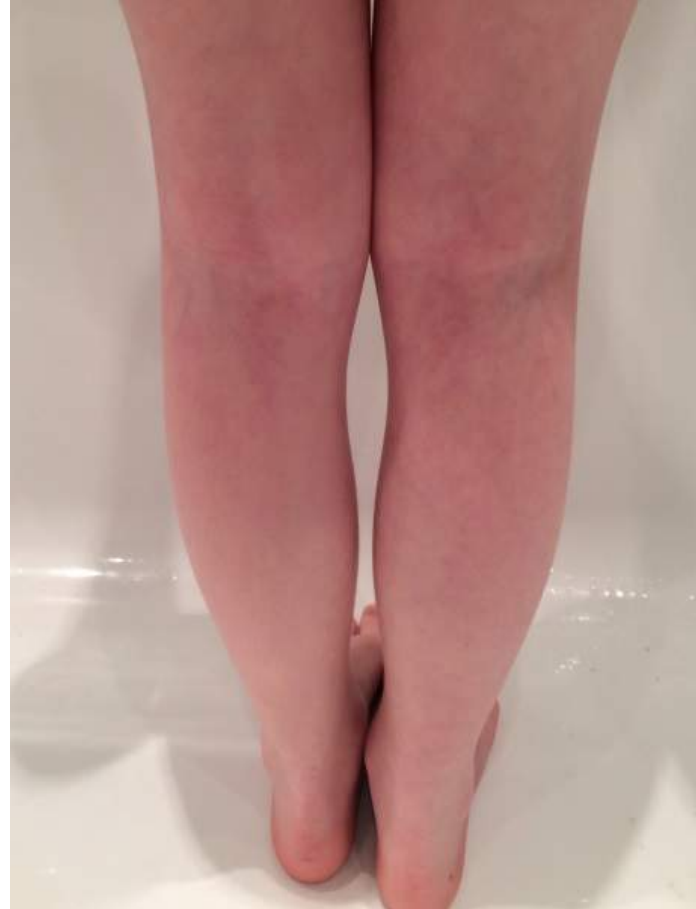
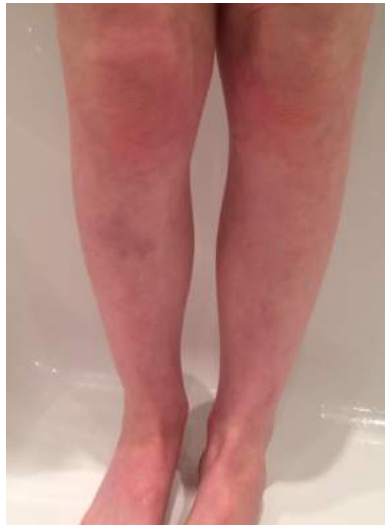
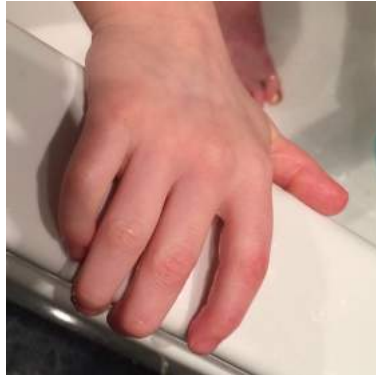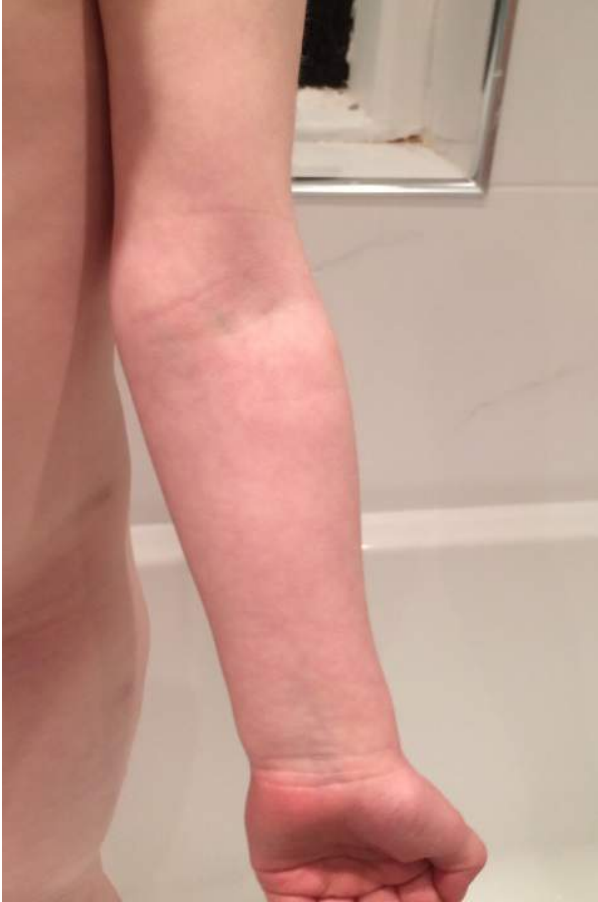Note from parents:

Even using Elocon at least weekly, our daughter's skin wasn't clearing. What people noticed more though was her always scratching because of the incessant itch.

Case study 9 – female, aged 5

Photos after commencing Aron Regimen



Note from parents:

Most of the time, you would no longer know that our daughter has eczema. She is rarely itchy these days and her quality of life is drastically improved.

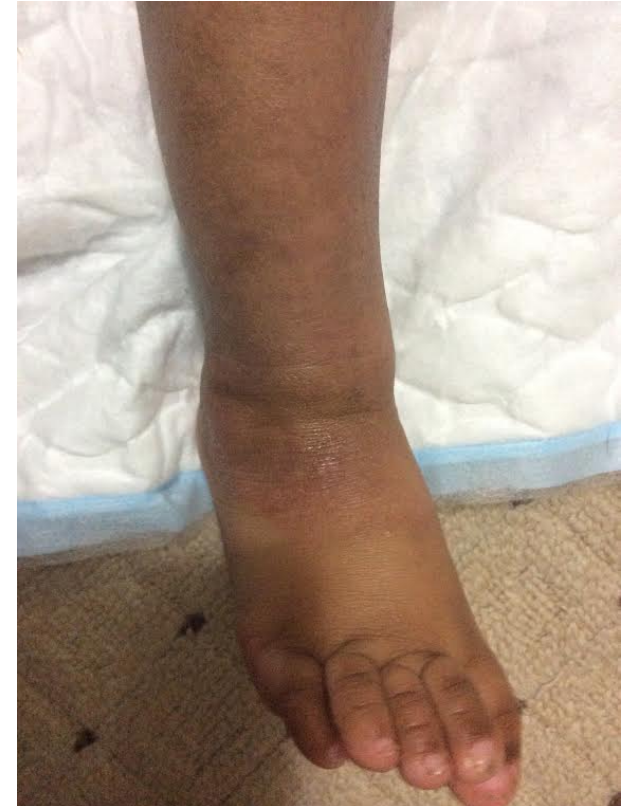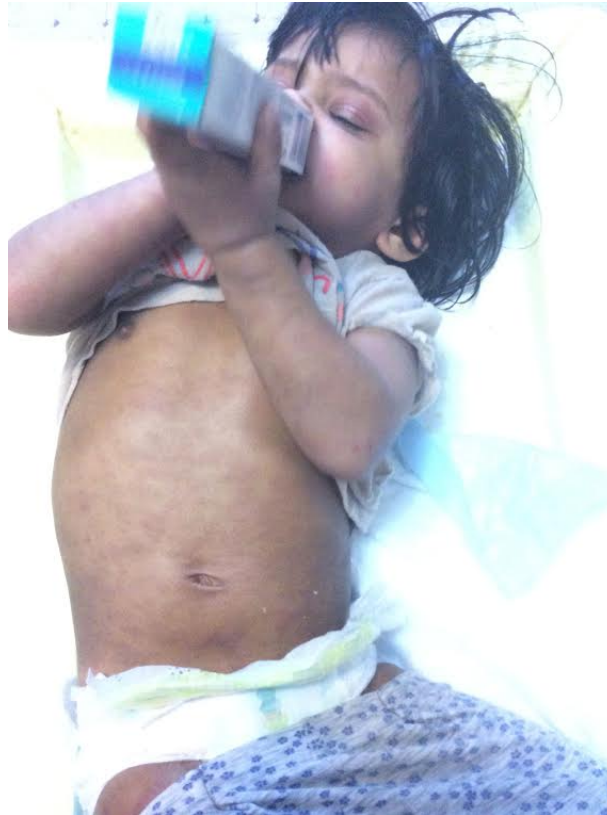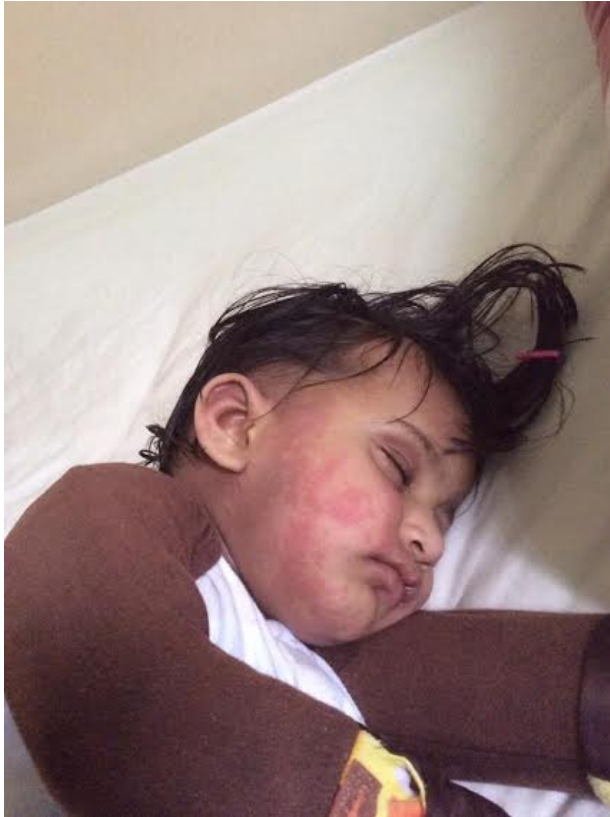Case study 10 (Dec 2014)

Female, aged 18 months when started on Aron Regimen

Prior to commencing Aron Regimen	Age when diagnosed with atopic eczema	8 weeks
	Under treatment of GP or Dermatologist prior to commencing Aron Regimen	Dermatologist
	Most recent treatment prior to commencing Aron Regimen (immunosuppressants: any time; rest: previous year)	Topical steroids: Clobetasone Oral steroids: No Topical immunosuppressants: No Oral immunosuppressants: No Antihistamines: Yes
	Any hospital emergency or elective admissions related to atopic eczema since diagnosis? If yes, how many?	No
	Any absences from school due to eczema (other than clinic appointments)?	N/A
Since commencing Aron Regimen	Date started the Aron Regimen	Oct 2014
	Current treatment	September 2017: Spot treatment approx. fortnightly September 2016: 1 x application twice a week February 2016: 1 x application every 3 days July 2015: 1 x application per day March 2015: Antibiotic removed Feb 2015: No. of applications reduced to once a day Dec 2014: Applied 2 x daily Mix of steroid, antibiotic and moisturiser creams
	Any hospital emergency or elective admissions related to atopic eczema since commencing Aron Regimen?	No
	Any absences from school due to eczema (other than clinic appointments or initial week of Aron Regimen)?	N/A

Case study 10 – female, aged 18 months

Photos before commencing Aron Regimen

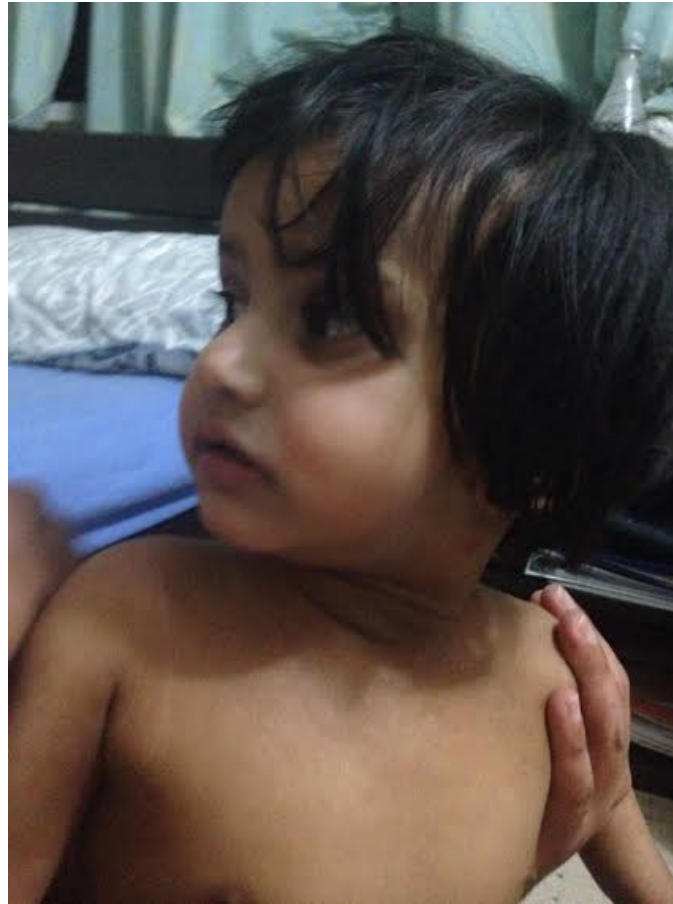
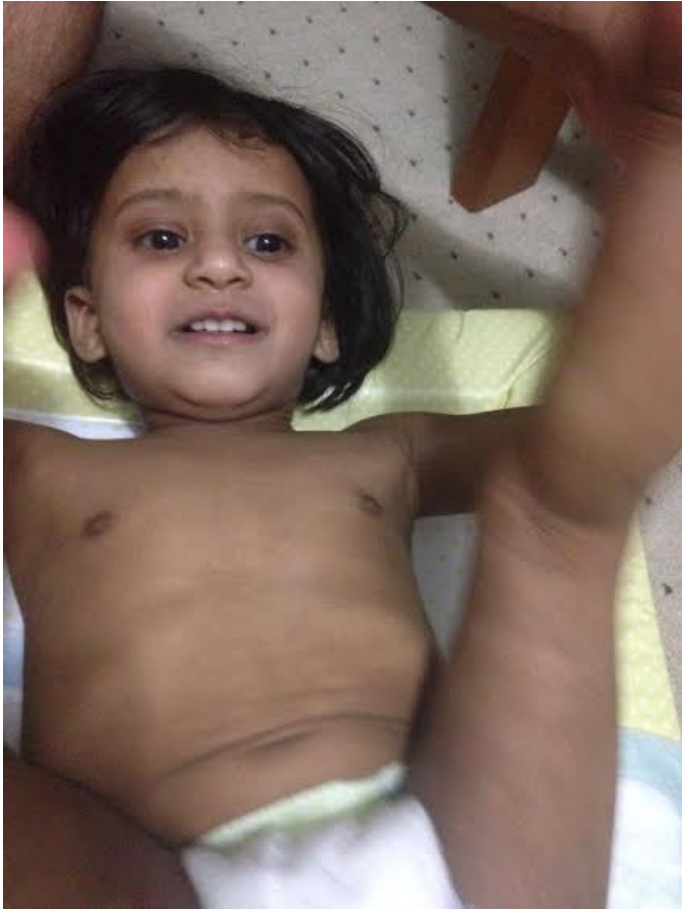
Note from parents:

My child had an incessant itch which affected all aspects of her life(sleep, feeding habits, weight gain, play time) and our life.

Case study 10 – female, aged 18 months

Photos after commencing Aron Regimen



Note from parents:

The itch has 100% gone. She is able to sleep through the night and engage in all activities comfortably during the day.

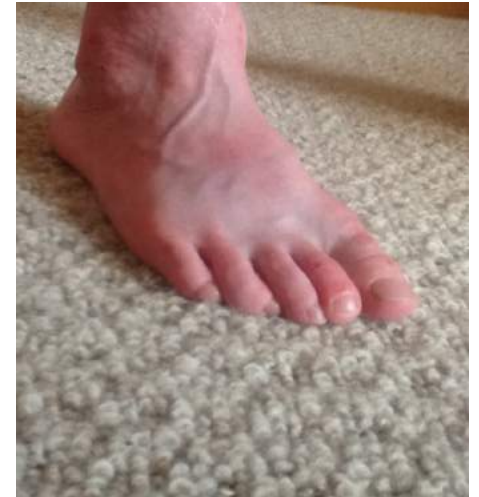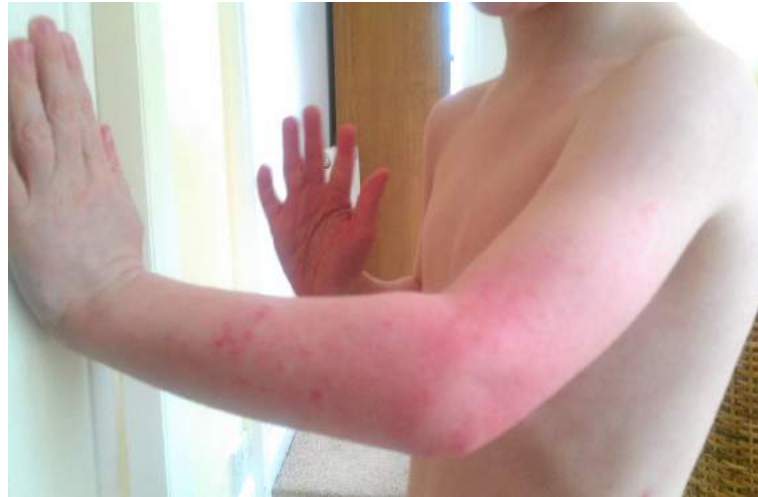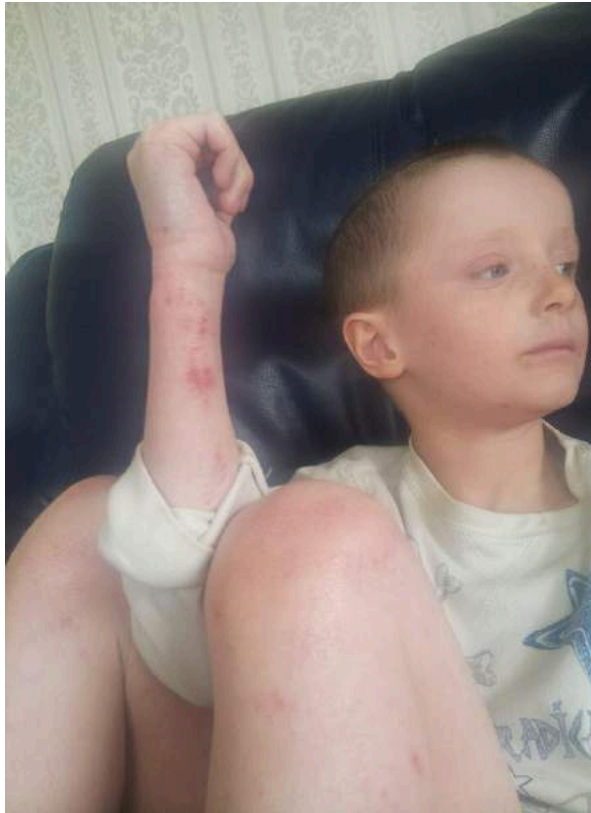Case study 11 (Dec 2014)

Male, aged 6 when started on Aron Regimen

Prior to commencing Aron Regimen	Age when diagnosed with atopic eczema	10 weeks
	Under treatment of GP or Dermatologist prior to commencing Aron Regimen	Dermatologist
	Most recent treatment prior to commencing Aron Regimen (immunosuppressants: any time; rest: previous year)	Topical steroids: Elocon, Synalar c Oral steroids: No Topical immunosuppressants: Protopic (0.1% and 0.03%) Oral immunosuppressants: No Antihistamines: Yes
	Any hospital emergency or elective admissions related to atopic eczema since diagnosis? If yes, how many?	Yes, 1 admission
	Any absences from school due to eczema (other than clinic appointments)?	Yes
Since commencing Aron Regimen	Date started the Aron Regimen	June 2014
	Current treatment	September 2017: Spot treatment approx once per month September 2016: Applied 2 x per week February 2016: Applied 3 x per week July 2015: Antibiotic removed. Applied 3 x per week Dec 2014: Applied 3 times a day Mix of steroid ointment and moisturiser ointment
	Any hospital emergency or elective admissions related to atopic eczema since commencing Aron Regimen?	No
	Any absences from school due to eczema (other than clinic appointments or initial week of Aron Regimen)?	No

Case study 11 – male, aged 6

Photos before commencing Aron Regimen

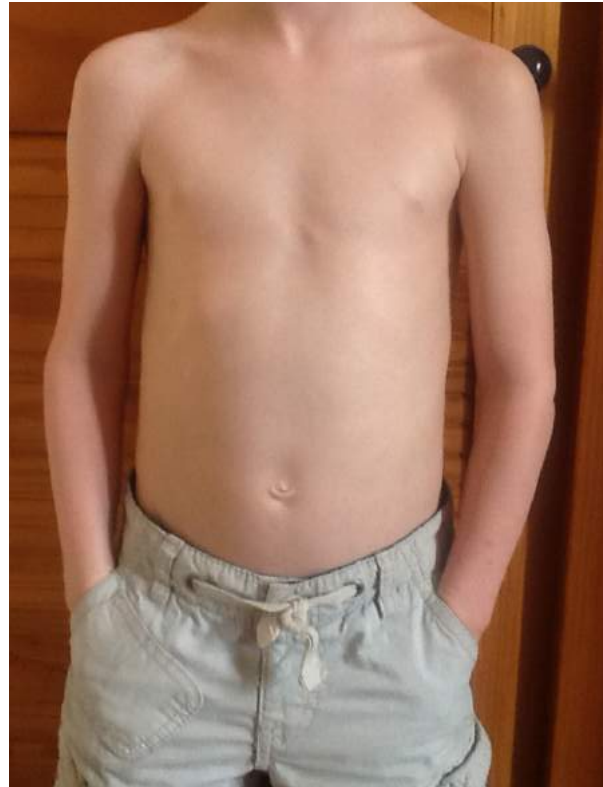

Note from parents:

He was constantly itchy and irritable. Trying not to scratch, having activities interrupted to get cream applied several times per day, red and greasy appearance, scratching and appearance being discussed by family and friends – this was starting to affect his confidence and emotional wellbeing.

Case study 11 – male, aged 6

Photos after commencing Aron Regimen



Note from parents:

He feels really comfortable and hardly ever scratches. Apart from having creams applied eczema is hardly an issue any more. As parents we no longer worry about how eczema is affecting his physical and emotional health and applying creams and monitoring his scratching no longer rules our daily family life.

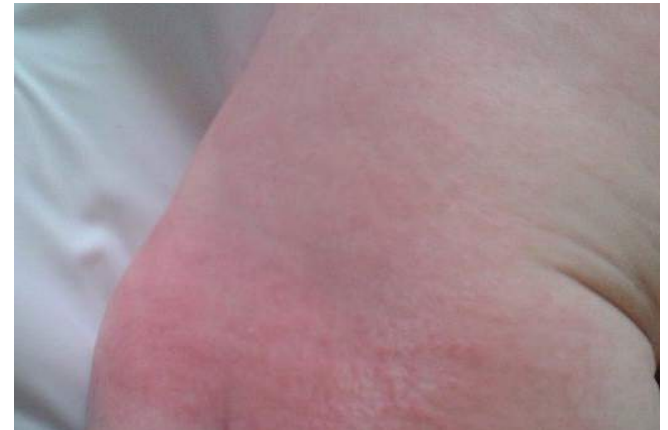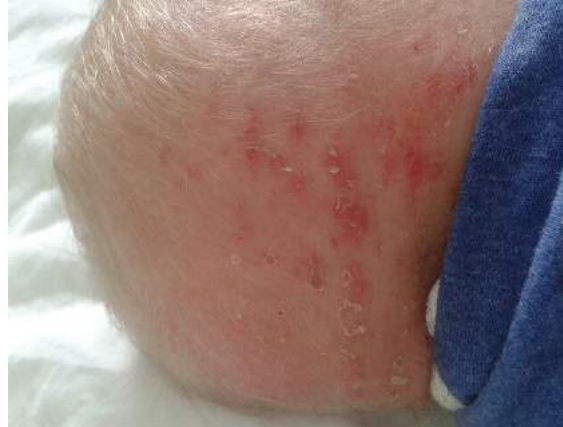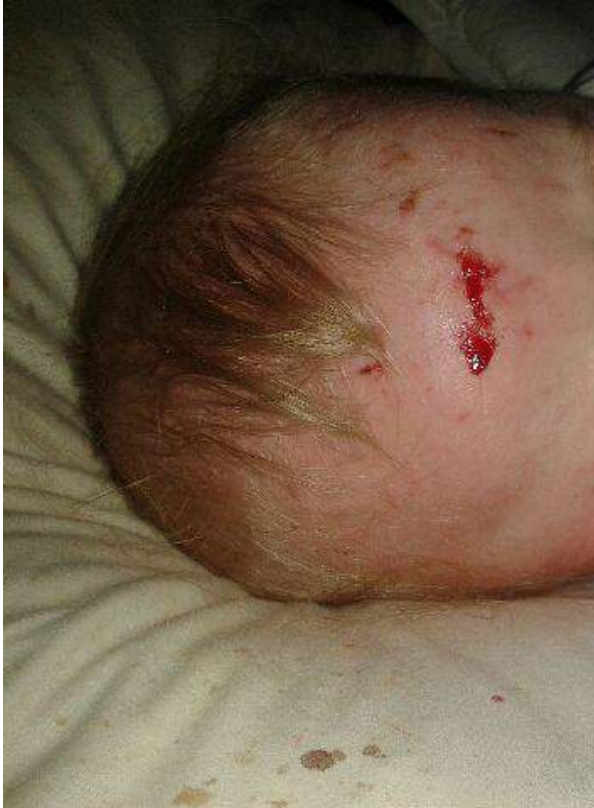Case study 12 (Dec 2014)

Male, aged 7 months when started on Aron Regimen

Prior to commencing Aron Regimen	Age when diagnosed with atopic eczema	5 months
	Under treatment of GP or Dermatologist prior to commencing Aron Regimen	GP
	Most recent treatment prior to commencing Aron Regimen (immunosuppressants: any time; rest: previous year)	<div>Topical steroids: Hydrocortisone 1%</div> <div>Oral steroids: No</div> <div>Topical immunosuppressants: No</div> <div>Oral immunosuppressants: No</div> <div>Antihistamines: Yes</div>
	Any hospital emergency or elective admissions related to atopic eczema since diagnosis? If yes, how many?	No (but two trips to 'out of hours' – emergency doctor very concerned and said to see GP next day for urgent referral to Dermatology)
	Any absences from school due to eczema (other than clinic appointments)?	N/A
Since commencing Aron Regimen	Date started the Aron Regimen	Oct 2014
	Current treatment	<p>September 2017: Spot treating, now infrequently</p> <p>September 2016: Scalp never; face rarely (only if required); arms, legs and torso, infrequently if required, every 1-2 weeks.</p> <p>February 2016: None on scalp, face applied 1 x every 3 days, arms and legs applied 1 x every other day, torso applied 1 x daily</p> <p>July 2015: Applied 2 x day</p> <p>Dec 2014: Applied 3 times a day to good areas, 4-5 problem areas</p> <p>Mix of steroid, antibiotic and moisturiser creams</p>
	Any hospital emergency or elective admissions related to atopic eczema since commencing Aron Regimen?	No
	Any absences from school due to eczema (other than clinic appointments or initial week of Aron Regimen)?	N/A

Case study 12 – male, aged 7 months

Photos before commencing Aron Regimen

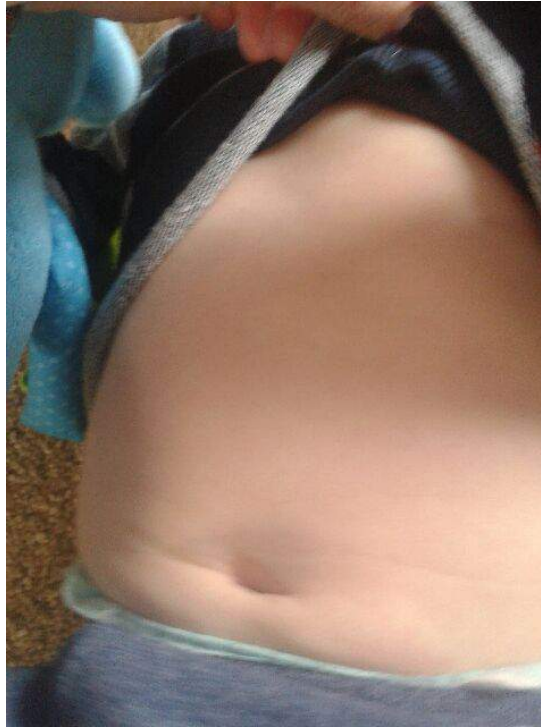
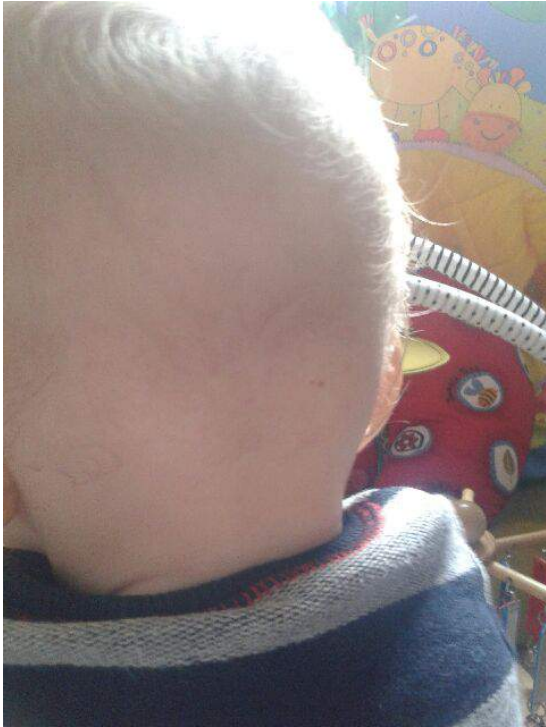
Note from parents:

My son was continuously scratching, crying and seemed very frantic. His skin was raw and felt like old leather. He barely slept at all, wouldn't go down in his own bed and would wake covered in blood. He seemed like a very unhappy baby both day and night and there was nothing we could do to console him.

Case study 12 – male, aged 7 months

Photos after commencing Aron Regimen



Note from parents:

Within 3 days he no longer scratched and stopped taking antihistamines. Within a week his skin was completely clear and soft to the touch. Within 2-3 weeks he was sleeping in his own bed, for a few hours at a time. He stopped crying during the day and became a happy, calm baby.

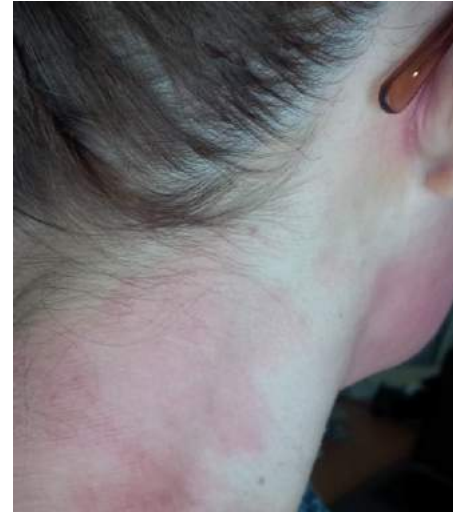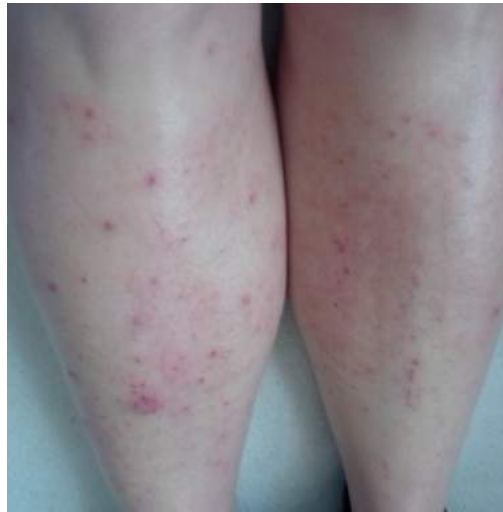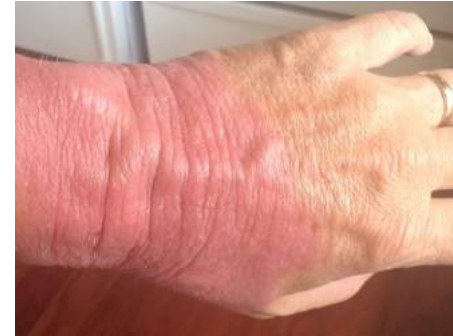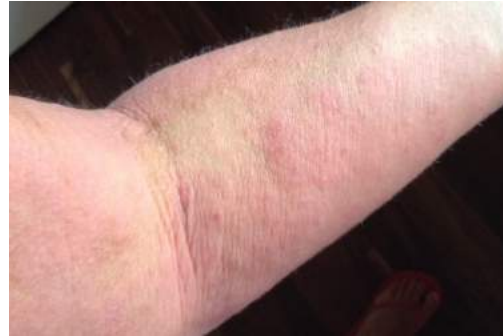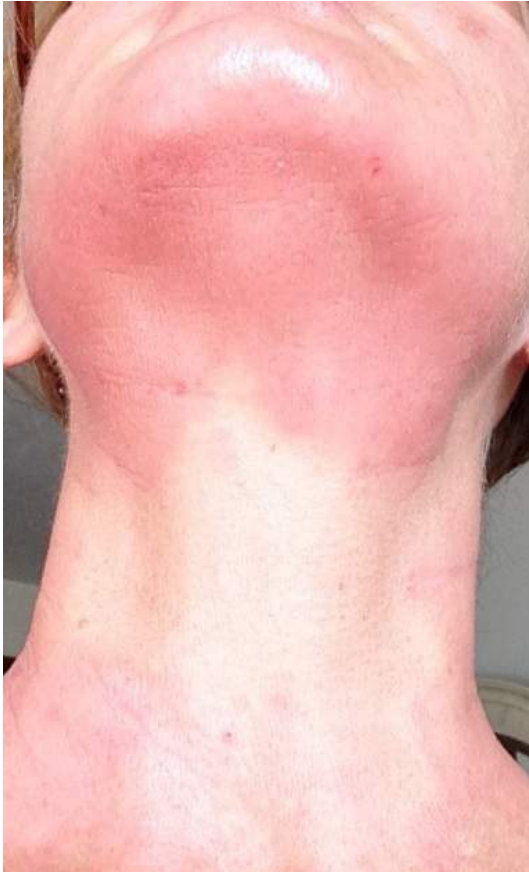Case study 13 (Dec 2014)

Female, aged 47 when started on Aron Regimen (Nov 2014)

Prior to commencing Aron Regimen	Age when diagnosed with atopic eczema	5 years
	Under treatment of GP or Dermatologist prior to commencing Aron Regimen	Dermatologist
	Most recent treatment prior to commencing Aron Regimen (immunosuppressants: any time; rest: previous year)	Topical steroids: Diflucortolone Valerate 0.1% Lyderm Ointment 0.05% Oral steroids: No Topical immunosuppressants: No Oral immunosuppressants: No Antihistamines: Yes
	Any hospital emergency or elective admissions related to atopic eczema since diagnosis? If yes, how many?	No
	Any absences from school due to eczema (other than clinic appointments)?	N/A
Since commencing Aron Regimen	Date started the Aron Regimen	Nov 2014
	Current treatment	September 2017: Only for very rare flares, otherwise nothing September 2016: As before only for flares, maximum 1 x weekly February 2016: Used only for flares, maximum 1 x weekly July 2015: Applied 1 x daily (sometimes less) Dec 2014: Applied 2 times a day Mix of steroid, antibiotic and moisturiser creams
	Any hospital emergency or elective admissions related to atopic eczema since commencing Aron Regimen?	No
	Any absences from school due to eczema (other than clinic appointments or initial week of Aron Regimen)?	N/A

Case study 13 – female, aged 47

Photos before commencing Aron Regimen

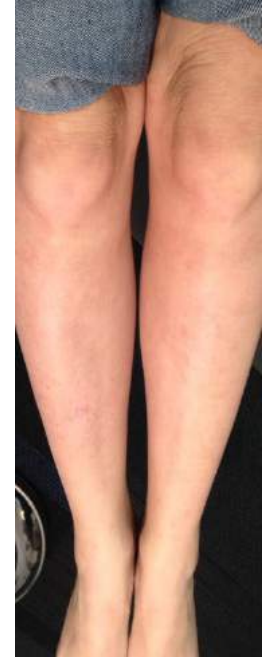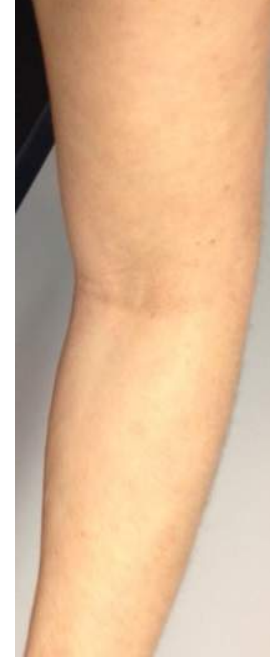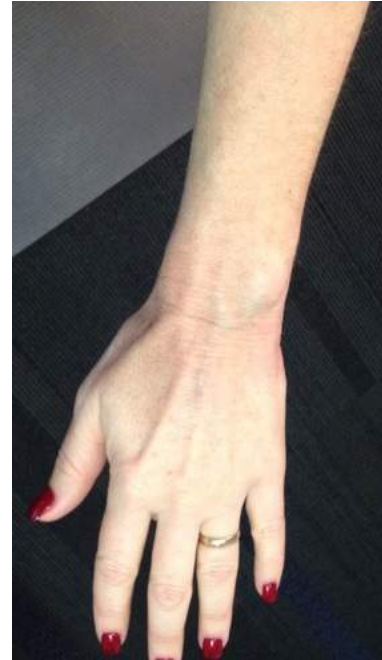


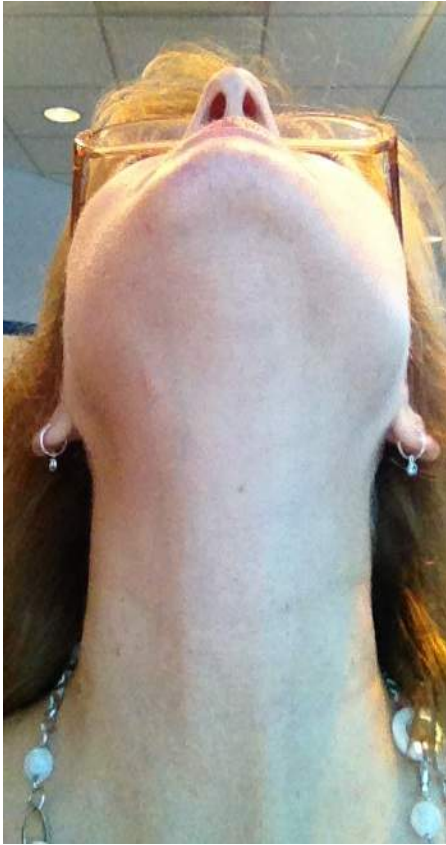Note from patient:

Could not concentrate at work. Feeling of hopelessness. Pain. Flaking & itching.

Case study 13 – female, aged 47

Photos after commencing Aron Regimen



Note from patient:

Within week 2, 95% of my skin was normal. No redness, no flaking, itching was almost non existent. Just my wrists were still a bit red, and thickened skin.

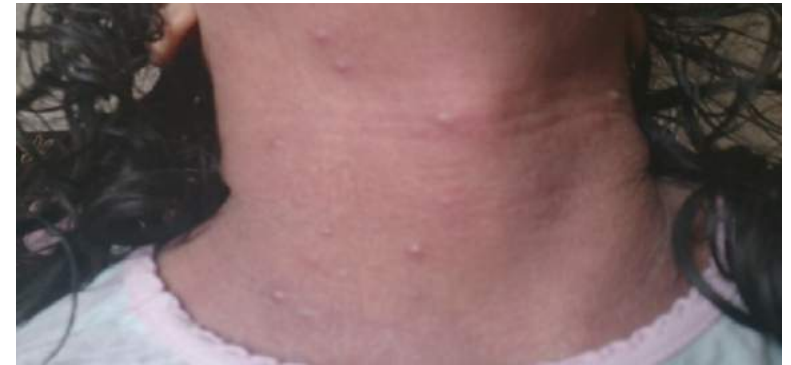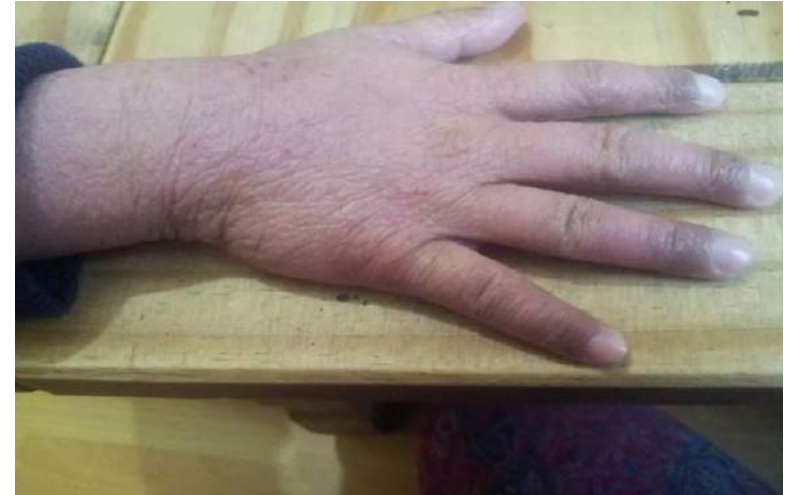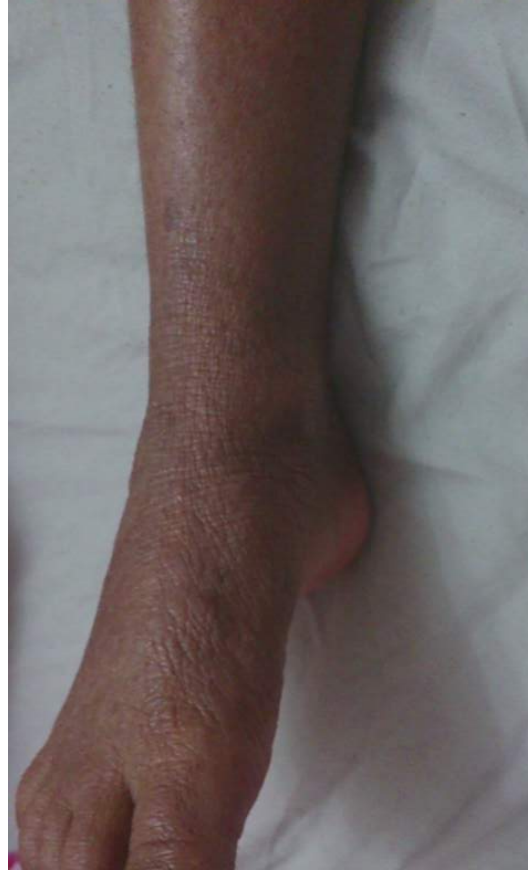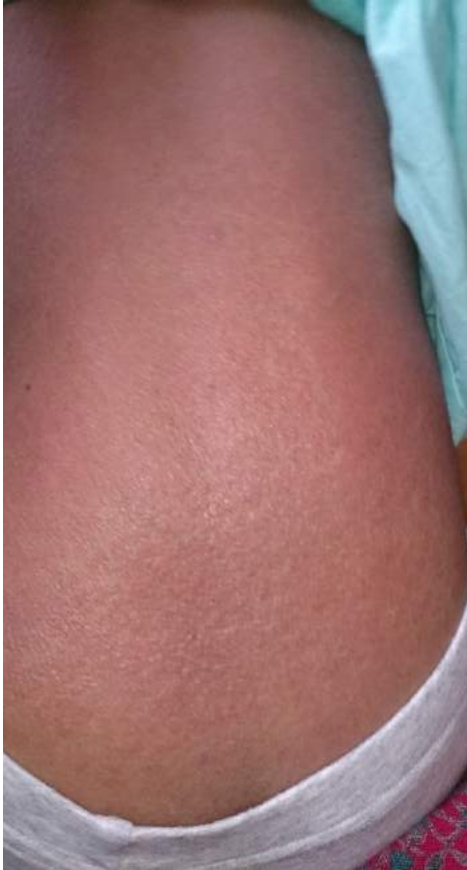Case study 14 (Dec 2014)

Female, aged 6 when started on Aron Regimen

Prior to commencing Aron Regimen	Age when diagnosed with atopic eczema	6 months
	Under treatment of GP or Dermatologist prior to commencing Aron Regimen	Dermatologist
	Most recent treatment prior to commencing Aron Regimen (immunosuppressants: any time; rest: previous year)	Topical steroids: Betnovate, Fucibet, Hydrocortisone Oral steroids: No Topical immunosuppressants: Protopic Oral immunosuppressants: No Antihistamines: Yes
	Any hospital emergency or elective admissions related to atopic eczema since diagnosis? If yes, how many?	No
	Any absences from school due to eczema (other than clinic appointments)?	Yes
Since commencing Aron Regimen	Date started the Aron Regimen	June 2014
	Current treatment	September 2017: 1 app daily, when flaring steroid/antibiotic mix for hands/feet September 2016: 1 x daily body and face, 4 times daily neat steroid on hands and feet February 2016: Applied 1 x daily July 2015: Applied 1 x daily Dec 2014: Applied 2 times a day Mix of steroid, antibiotic and moisturiser creams
	Any hospital emergency or elective admissions related to atopic eczema since commencing Aron Regimen?	No
	Any absences from school due to eczema (other than clinic appointments or initial week of Aron Regimen)?	No

Case study 14 – female, aged 6

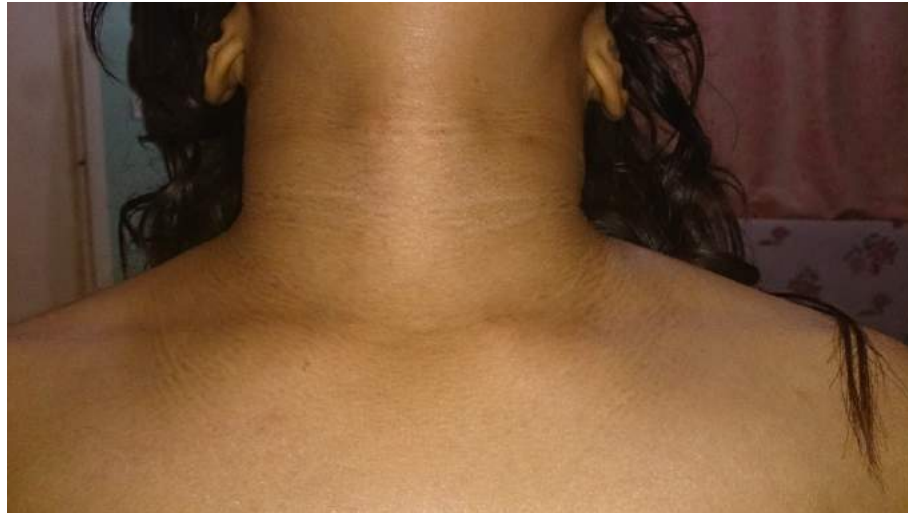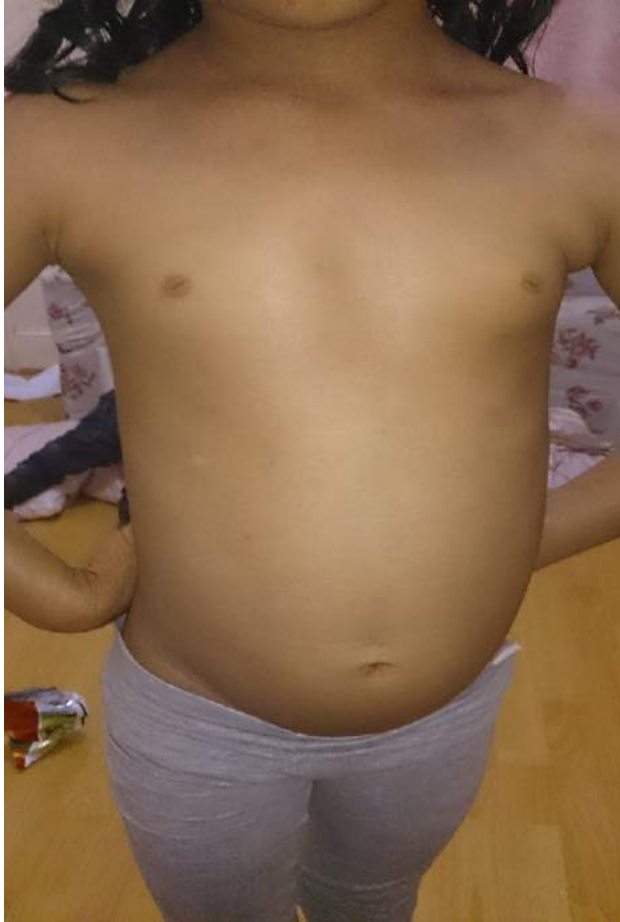Photos before commencing Aron Regimen



Note from parents:

Severe lack of sleep, a lot of weight loss for daughter, mentally impacted her.

Case study 14 – female, aged 6
Photos after commencing Aron Regimen



Note from parents:

Brilliant, sleeps through all night, does not need antihistamines every day like in the past

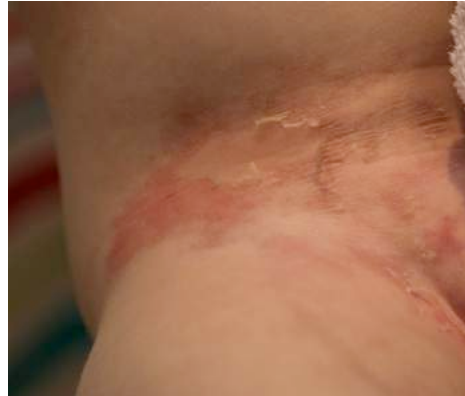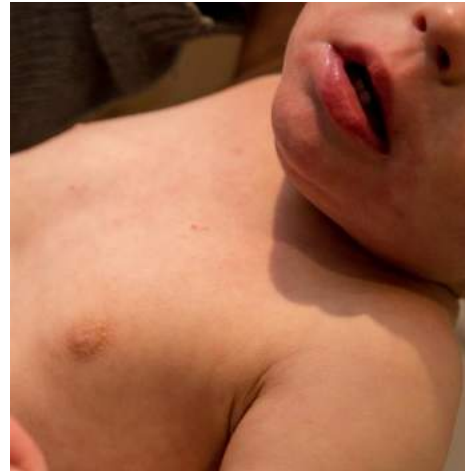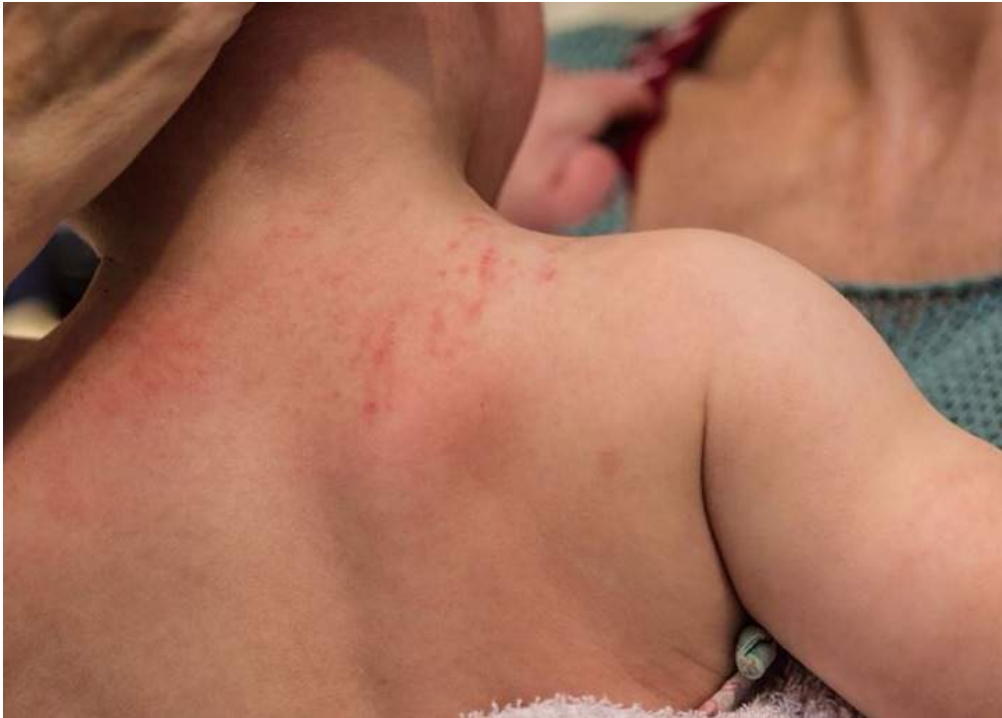Case study 15 (Jan 2015)

Male, aged 11 months when started on Aron Regimen

Prior to commencing Aron Regimen	Age when diagnosed with atopic eczema	3 months
	Under treatment of GP or Dermatologist prior to commencing Aron Regimen	Dermatologist
	Most recent treatment prior to commencing Aron Regimen (immunosuppressants: any time; rest: previous year)	Topical steroids: Eumovate, Hydrocortisone 1% Oral steroids: No Topical immunosuppressants: No Oral immunosuppressants: No Antihistamines: Yes
	Any hospital emergency or elective admissions related to atopic eczema since diagnosis? If yes, how many?	Yes, 1 admission
	Any absences from school due to eczema (other than clinic appointments)?	N/A
Since commencing Aron Regimen	Date started the Aron Regimen	Nov 2014
	Current treatment	September 2017: Applied 1 x weekly spot treatment, 2 fingers 1 x weekly September 2016: Applied 1 x weekly spot treatment, 3 fingers 4 x weekly over summer February 2016: Applied 1 x weekly back and sides spot treatment only, two fingers application 2 x weekly. November 2015: Antibiotic removed, further steroid dilution August 2015: 4 applications per week, face 2 x weekly of mixed compound only Jan 2015: Applied 1 x day Mix of steroid, antibiotic and moisturiser creams Antibiotic/steroid combined – face, started 13/05/15
	Any hospital emergency or elective admissions related to atopic eczema since commencing Aron Regimen?	No
	Any absences from school due to eczema (other than clinic appointments or initial week of Aron Regimen)?	N/A

Case study 15 – male, aged 11 months

Photos before commencing Aron Regimen

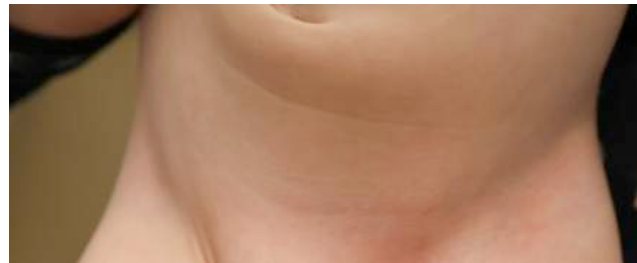
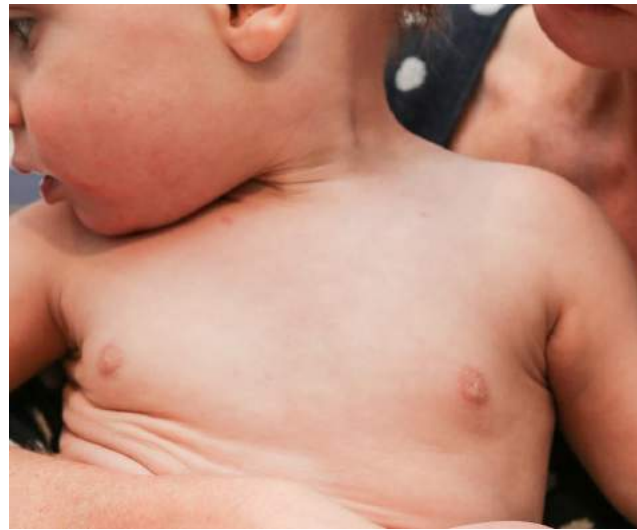
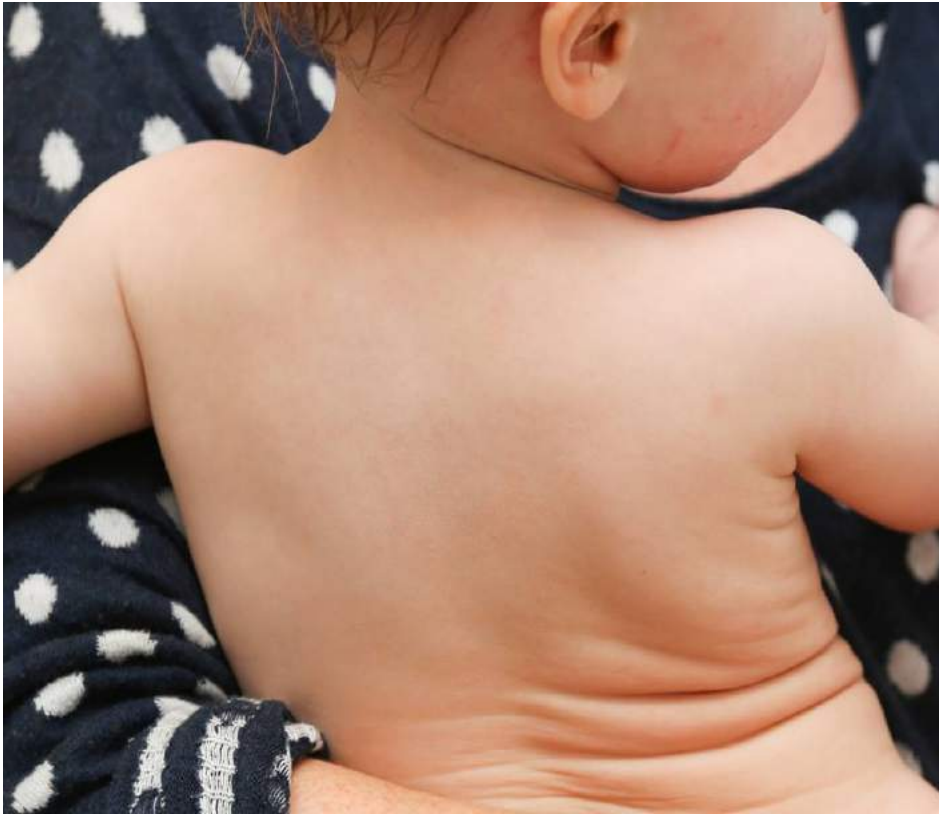
Note from parents:

Very itchy all the time, he couldn't stay still, screamed when bathes and held down arms to stop scratching. He didn't sleep well, constantly waking 2-3 times through the night, took antihistamine and wore sleep mitts to sleep at nights.

Case study 15 – male, aged 11 months

Photos after commencing Aron Regimen



Note from parents:

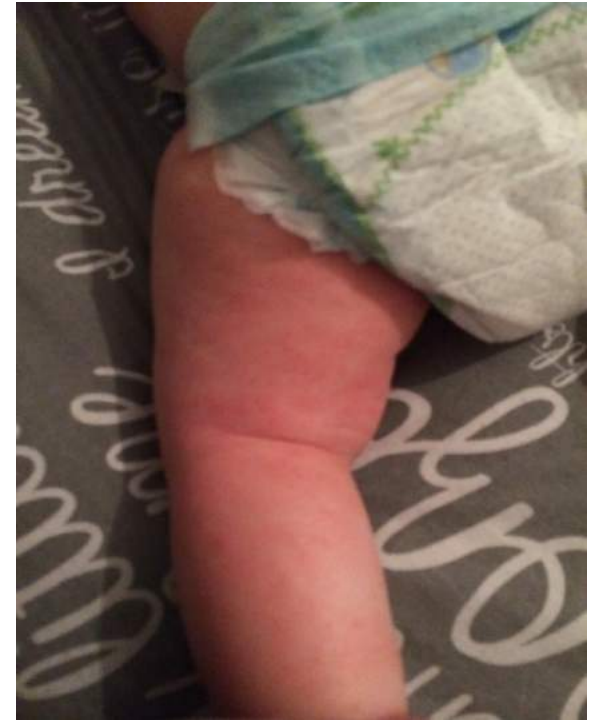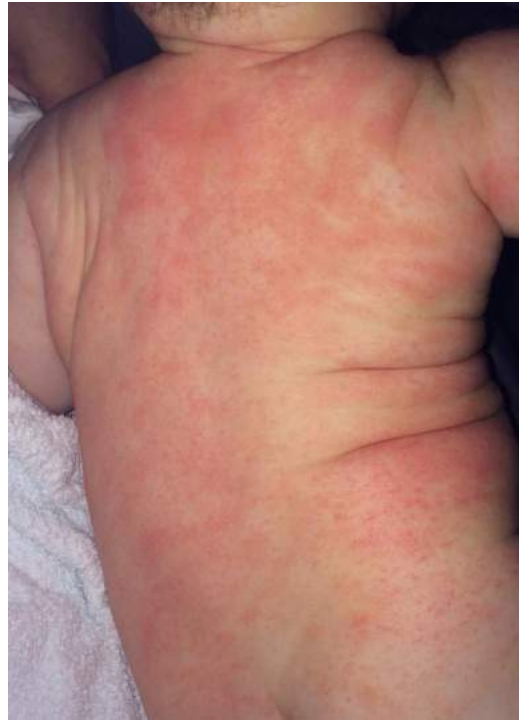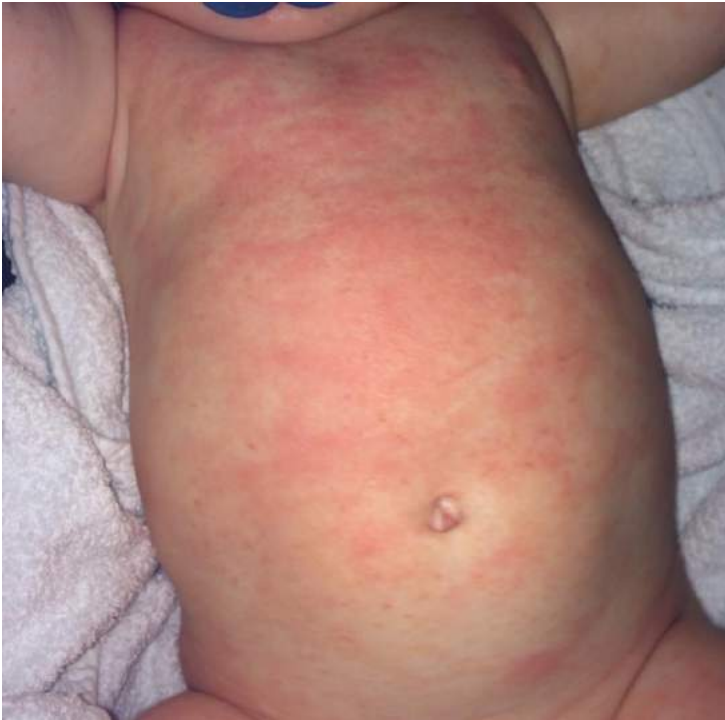No itch now, enjoys his baths, can sit and play with no jiggling. He sleeps throughout the night, takes no antihistamine and doesn't wear scratch sleeves. Much happier baby.

Case study 16 (Jan 2015)

Male, aged 7 months when started on Aron Regimen

Prior to commencing Aron Regimen	Age when diagnosed with atopic eczema	3 months
	Under treatment of GP or Dermatologist prior to commencing Aron Regimen	GP
	Most recent treatment prior to commencing Aron Regimen (immunosuppressants: any time; rest: previous year)	Topical steroids: Hydrocortisone Oral steroids: No Topical immunosuppressants: No Oral immunosuppressants: No Antihistamines: Yes
	Any hospital emergency or elective admissions related to atopic eczema since diagnosis? If yes, how many?	No
	Any absences from school due to eczema (other than clinic appointments)?	N/A
Since commencing Aron Regimen	Date started the Aron Regimen	Aug 2014
	Current treatment	September 2016: Have not applied any cream for 2 months now February 2016: Applied 1 weekly August 2015: Applied 1 x every 4 days Jan 2015: Applied once a day Mix of steroid/antibiotic combined cream and moisturiser cream
	Any hospital emergency or elective admissions related to atopic eczema since commencing Aron Regimen?	No
	Any absences from school due to eczema (other than clinic appointments or initial week of Aron Regimen)?	N/A

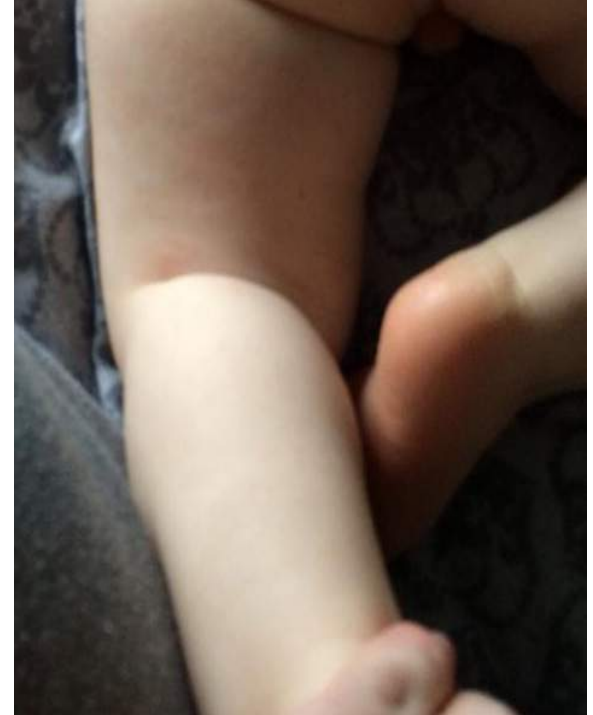
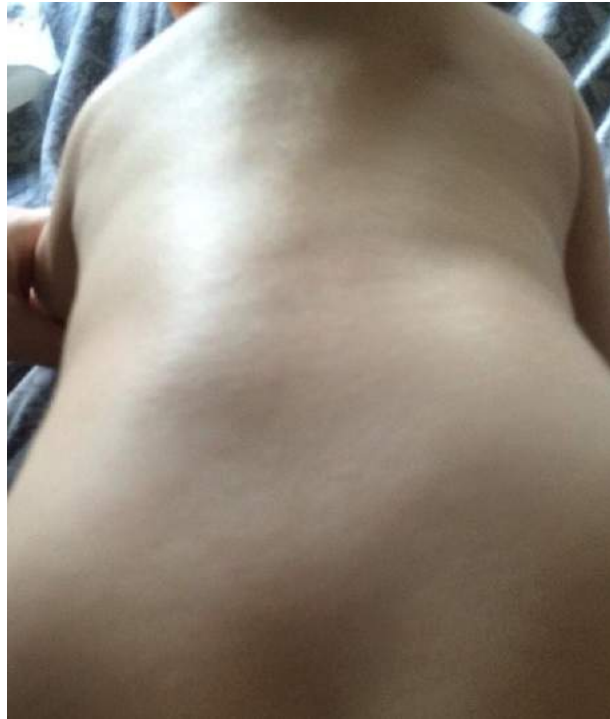
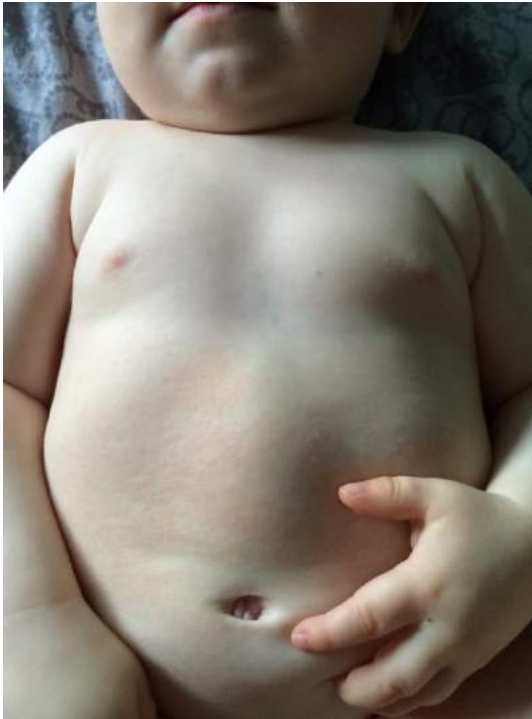Case study 16 – male, aged 7 months
Photos before commencing Aron Regimen



Note from parents:

Constant itch. Unhappy. Underdeveloped. No sleep.

Case study 16 – male, aged 7 months
Photos after commencing Aron Regimen



Note from parents:

Itch free. Happy. Well rested.

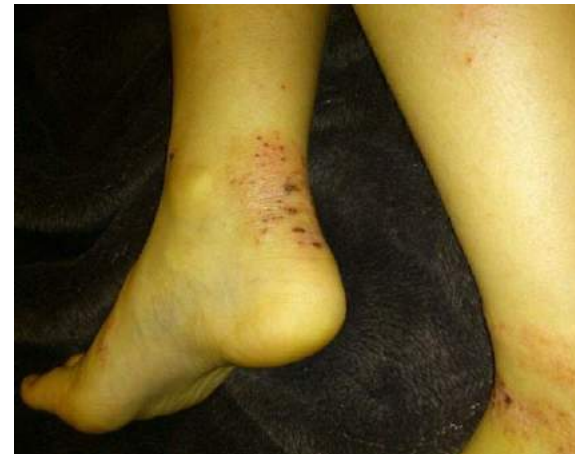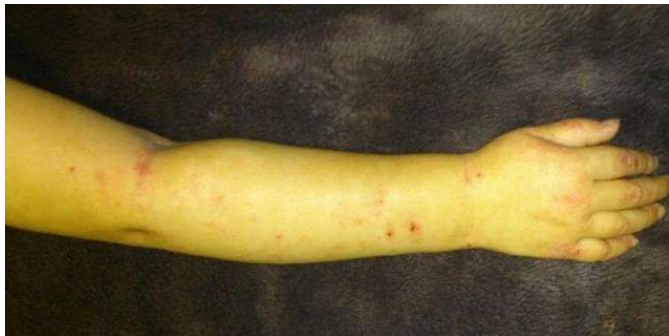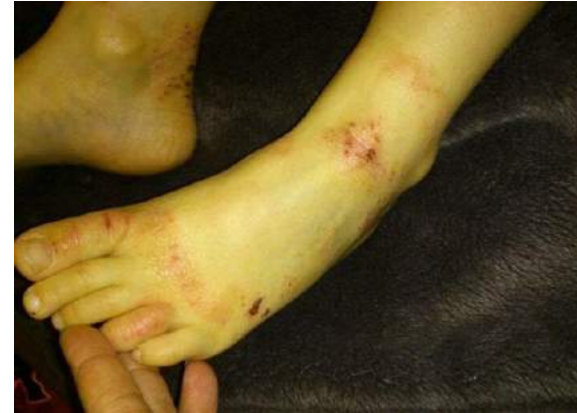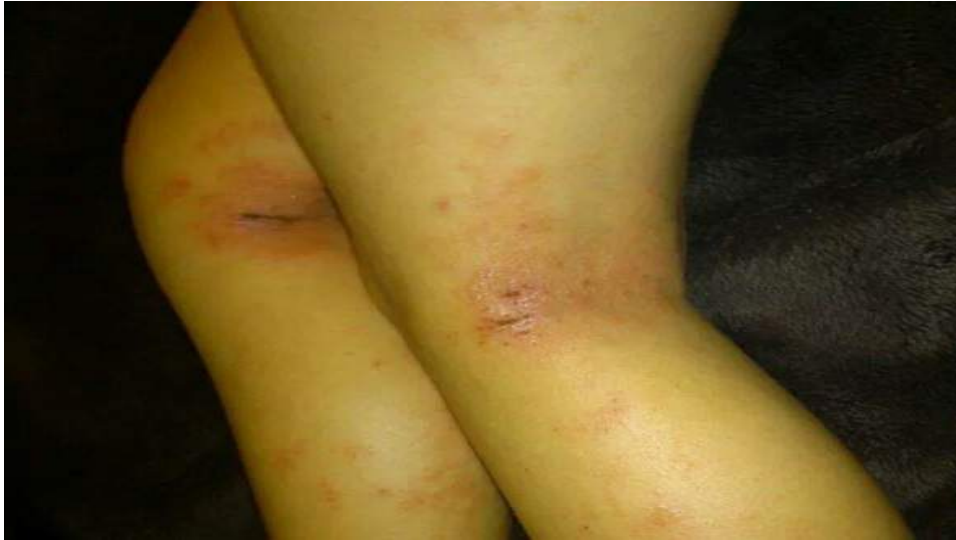Case study 17 (Feb 2015)

Male, aged 5 when started on Aron Regimen

Prior to commencing Aron Regimen	Age when diagnosed with atopic eczema	8 weeks
	Under treatment of GP or Dermatologist prior to commencing Aron Regimen	GP
	Most recent treatment prior to commencing Aron Regimen (immunosuppressants: any time; rest: previous year)	Topical steroids: Hydrocortisone, Eumovate, Betnovate Oral steroids: No Topical immunosuppressants: No Oral immunosuppressants: No Antihistamines: Yes
	Any hospital emergency or elective admissions related to atopic eczema since diagnosis? If yes, how many?	No
	Any absences from school due to eczema (other than clinic appointments)?	Yes
Since commencing Aron Regimen	Date started the Aron Regimen	Nov 2014
	Current treatment	September 2017: Spot treat as needed, hands only September 2016: 1 app per day on couple of toes, fingers, one wrist one spot on foot. Spot treatment for flares (once every 6 months). February 2016: 1 x application per week arms and legs, 1 x daily on hands and feet July 2015: 1 application every 2 days on arms and legs (not body anymore). 2 x daily on hands and feet. Feb 2015: Applied once a day all over Mix of steroid, antibiotic and moisturiser creams
	Any hospital emergency or elective admissions related to atopic eczema since commencing Aron Regimen?	No
	Any absences from school due to eczema (other than clinic appointments or initial week of Aron Regimen)?	No

Case study 17 – male, aged 5

Photos before commencing Aron Regimen

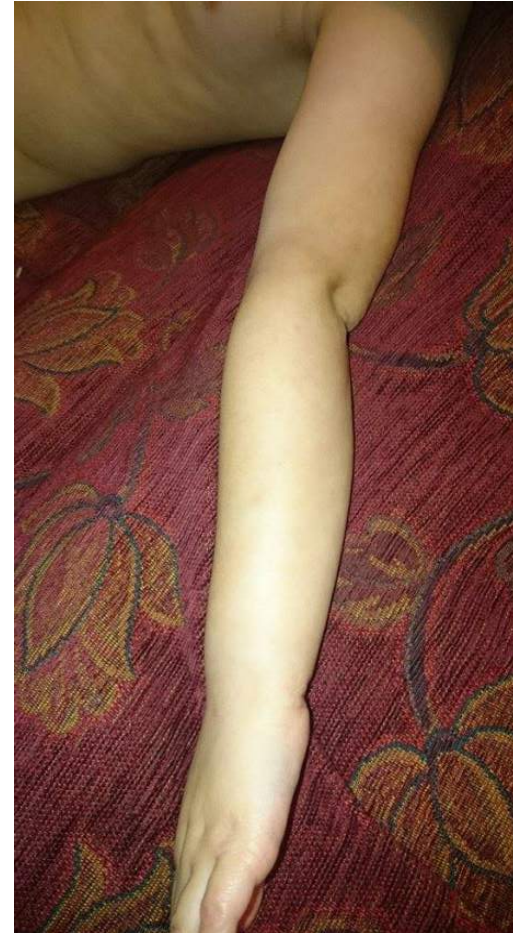
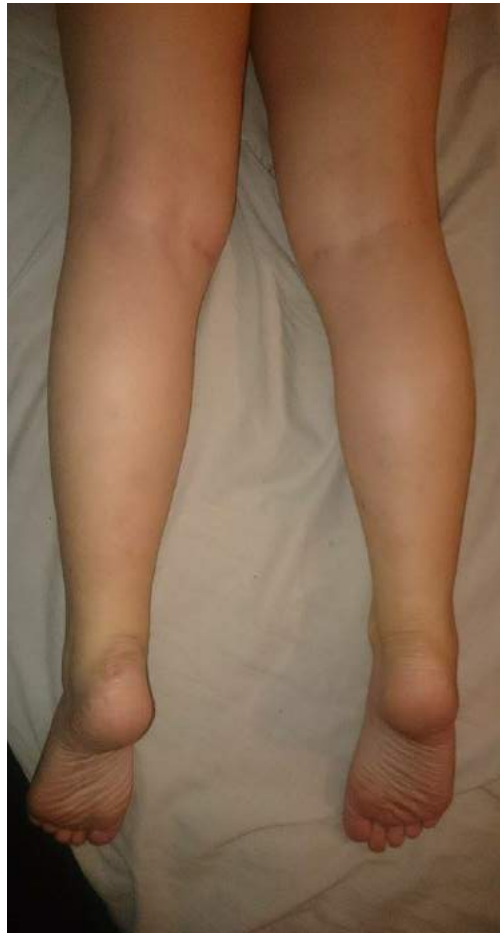
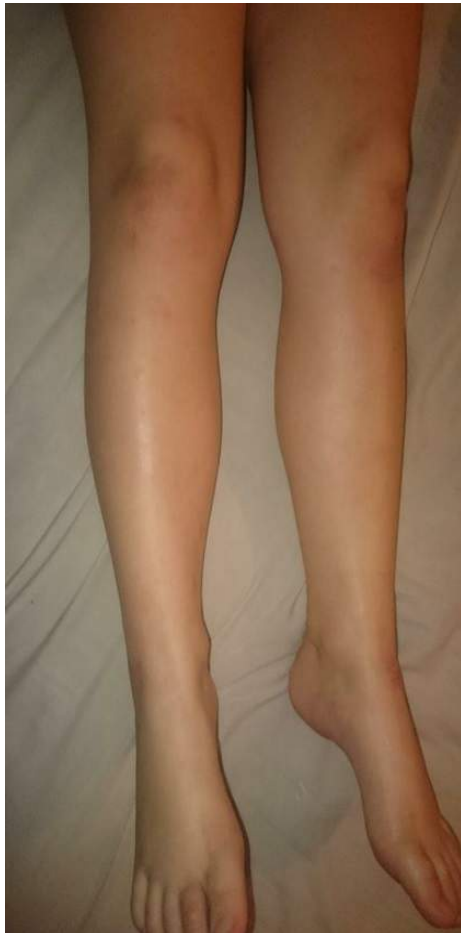Note from parents:

Very frustrated. Lack of sleep and constant itch. Restrictions to certain activities.

Case study 17 – male, aged 5

Photos after commencing Aron Regimen



Note from parents:

So much happier. Better sleep. Can do anything!!

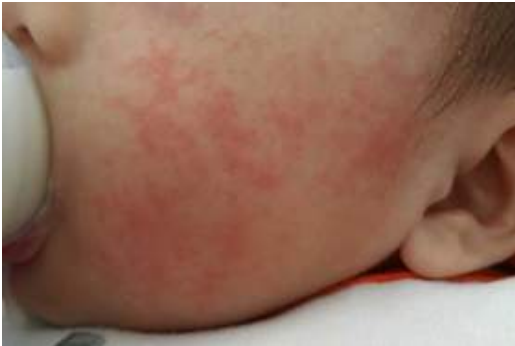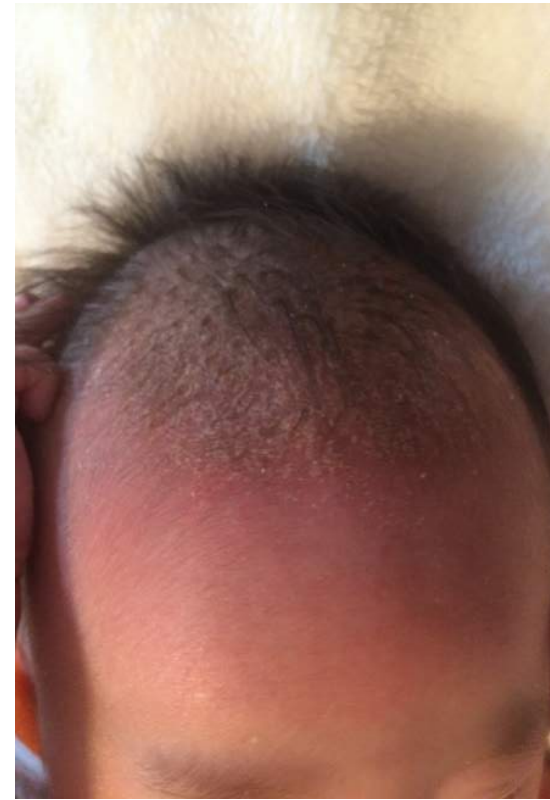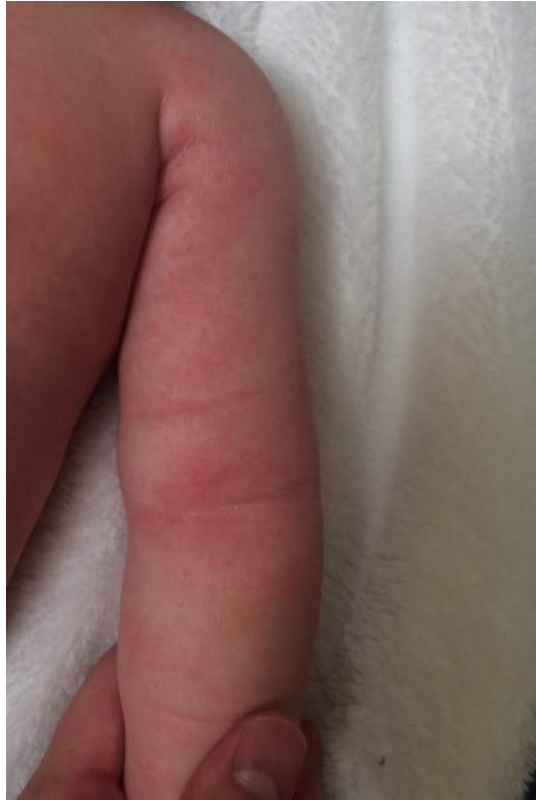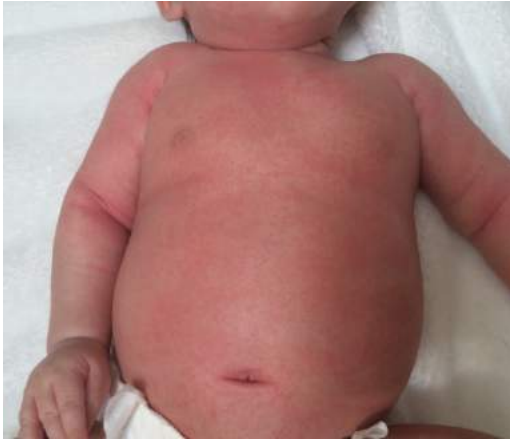Case study 18 (Jan 2015)

Male, aged 3 months when started on Aron Regimen (Sept 2014)

Prior to commencing Aron Regimen	Age when diagnosed with atopic eczema	5 weeks
	Under treatment of GP or Dermatologist prior to commencing Aron Regimen	GP
	Most recent treatment prior to commencing Aron Regimen (immunosuppressants: any time; rest: previous year)	Topical steroids: Hydrocortisone 1% Oral steroids: No Topical immunosuppressants: No Oral immunosuppressants: No Antihistamines: No
	Any hospital emergency or elective admissions related to atopic eczema since diagnosis? If yes, how many?	No
	Any absences from school due to eczema (other than clinic appointments)?	N/A
Since commencing Aron Regimen	Date started the Aron Regimen	Sept 2014
	Current treatment	September 2017: Spot treatment only if there is a flare, otherwise nothing September 2016: Only used on small spots if there is a flare, otherwise nothing July 2015: Finished using cream except if there is a flare Jan 2015: Applied once a day Mix of steroid, antibiotic and moisturiser creams
	Any hospital emergency or elective admissions related to atopic eczema since commencing Aron Regimen?	No
	Any absences from school due to eczema (other than clinic appointments or initial week of Aron Regimen)?	N/A

Case study 18 – male, age 3 months

Photos before commencing Aron Regimen

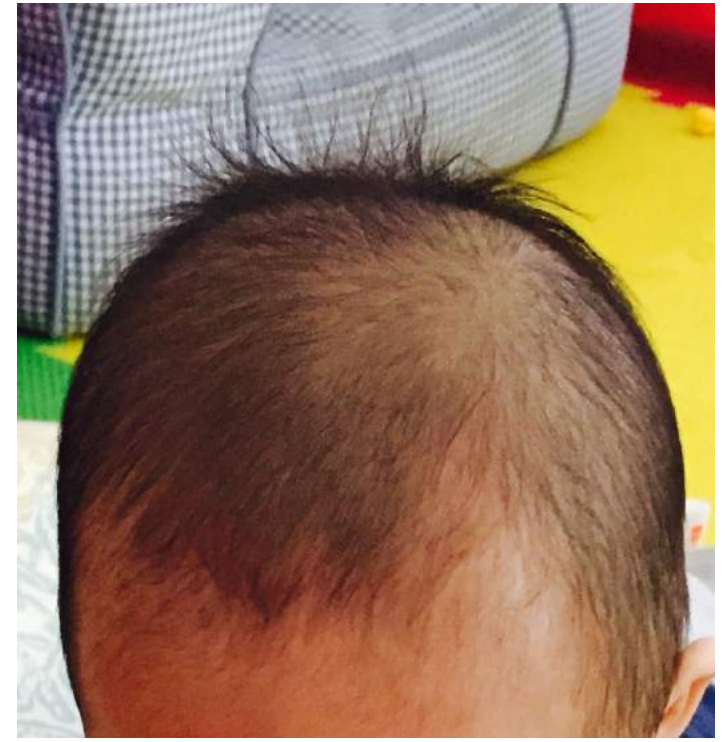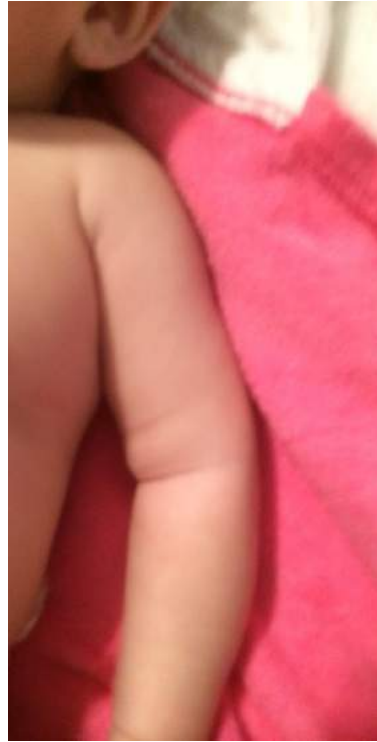

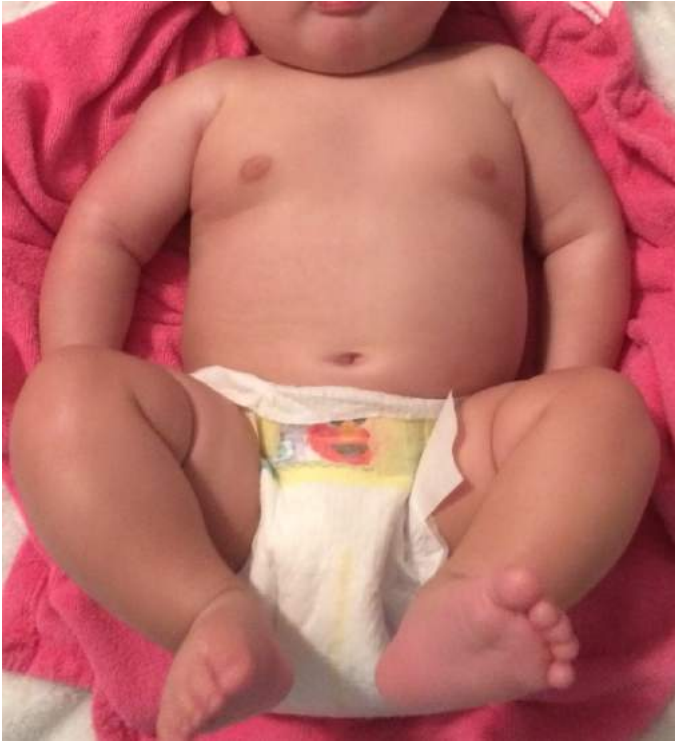
Note from parents:

Prior to Dr Aron, my son had head to toe inflamed and infected eczema. He was itchy and miserable.

Case study 18 – male, aged 3 months

Photos after commencing Aron Regimen



Note from parents:

Since starting with Dr Aron, my son now has smooth, soft baby skin! He looks amazing and is no longer itchy. Now, he can just be the baby he was meant to be.

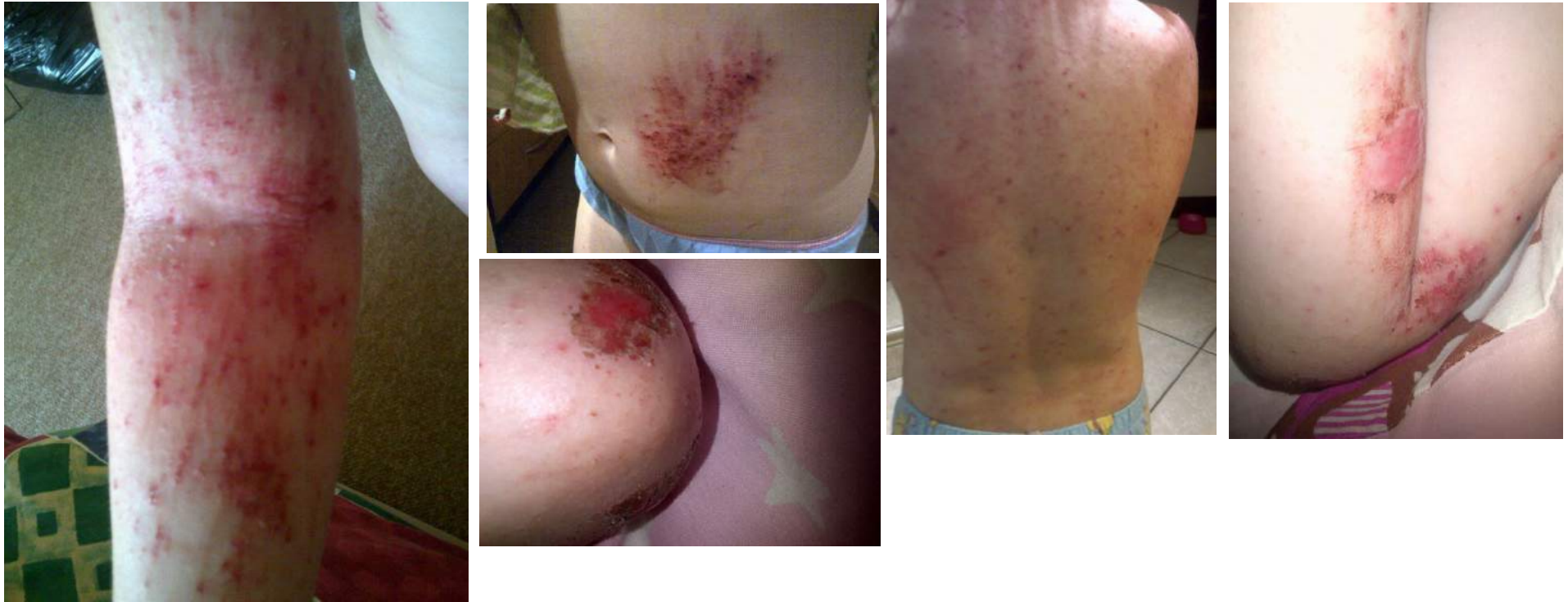Case study 19 (Feb 2015)

Female, aged 8 when started on Aron Regimen

Prior to commencing Aron Regimen	Age when diagnosed with atopic eczema	3
	Under treatment of GP or Dermatologist prior to commencing Aron Regimen	Dermatologist
	Most recent treatment prior to commencing Aron Regimen (immunosuppressants: any time; rest: previous year)	Topical steroids: Advantan fatty ointment Oral steroids: Yes Topical immunosuppressants: No Oral immunosuppressants: No Antihistamines: Yes
	Any hospital emergency or elective admissions related to atopic eczema since diagnosis? If yes, how many?	No
	Any absences from school due to eczema (other than clinic appointments)?	Yes
Since commencing Aron Regimen	Date started the Aron Regimen	Dec 2014
	Current treatment	September 2017: Spot treating, now infrequently September 2016: Every 1-2 weeks, spot treatment only February 2016: 2-3 x per week, spot treatment July 2015: 1 x application per day Feb 2015: 2 x application per day Mix of steroid, antibiotic and moisturiser creams
	Any hospital emergency or elective admissions related to atopic eczema since commencing Aron Regimen?	No
	Any absences from school due to eczema (other than clinic appointments or initial week of Aron Regimen)?	No

Case study 19 – female, aged 8

Photos before commencing Aron Regimen

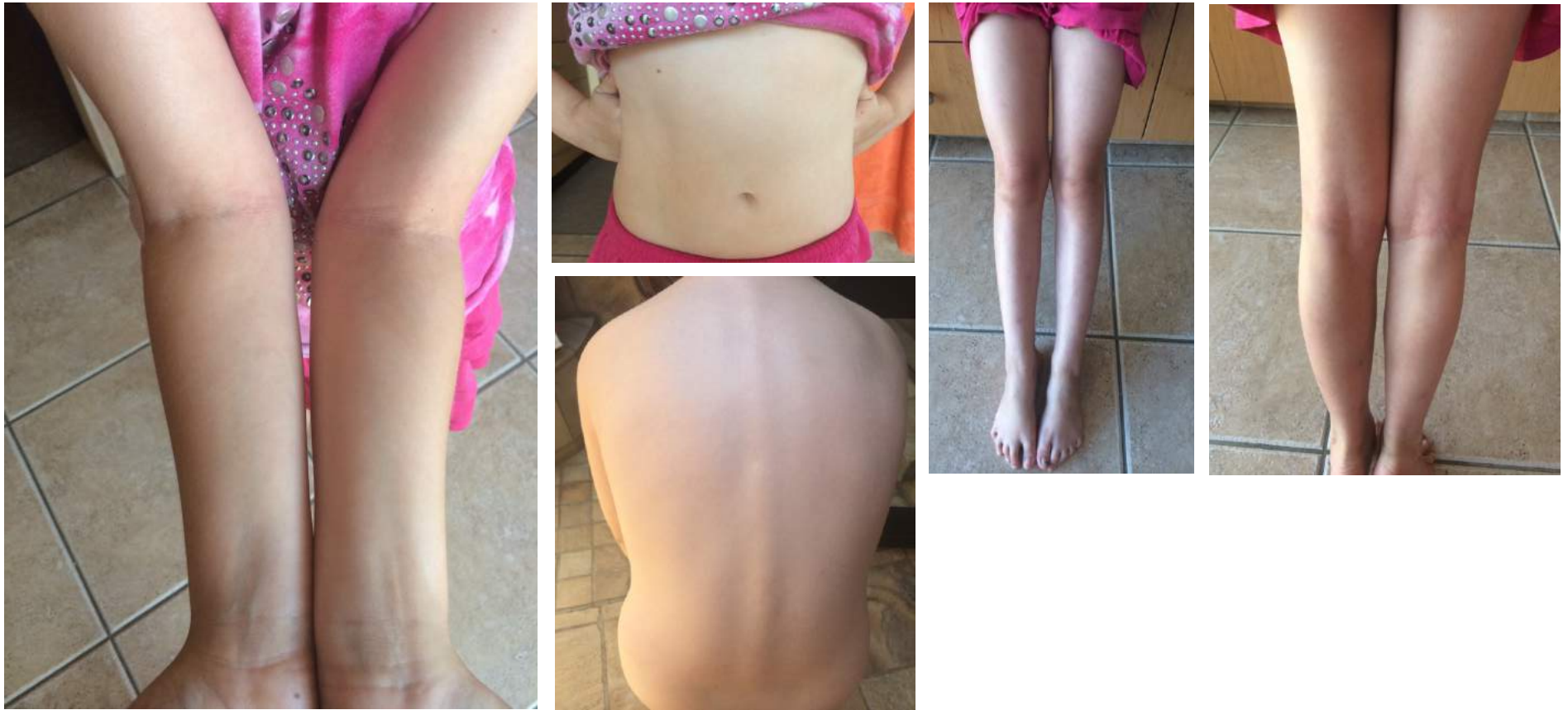

Note from parents:

At age 7 she asked me to help her die and by 8 she had a plan on how she was going to commit suicide. The itching, bleeding, lack of sleep, pain and exhaustion experienced attempting to treat this disease has had the knock-on effect of creating an autoimmune disease in her mom and her dad has had to have a staph-induced abscess removed surgically. The family have experienced over 100 boils between them (excluding the patient). Hundreds of thousands has been spent on treatments and my daughter has been in therapy for over 2 years for the psychological damage and anxiety that living with eczema has caused.

Case study 19 – female, aged 8

Photos after commencing Aron Regimen



Note from parents:

The first night of application she slept through. The itch completely disappeared after 2 days. All medication apart from Dr Aron's cream has been stopped including oral cortisone, chronic oral antibiotics, antihistamines as well as anti-anxiety / anti-depressant Cipralex. Happy daughter, more confident, no oily dresses and blood-soaked bedding, no more crying and scratching for hours on end. Quality of life has been restored to the family and her concentration and grades have improved.

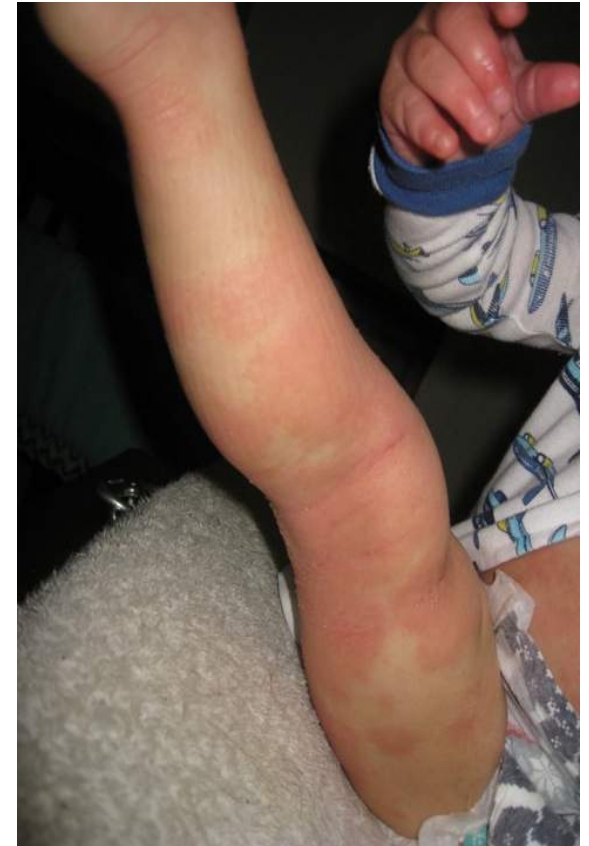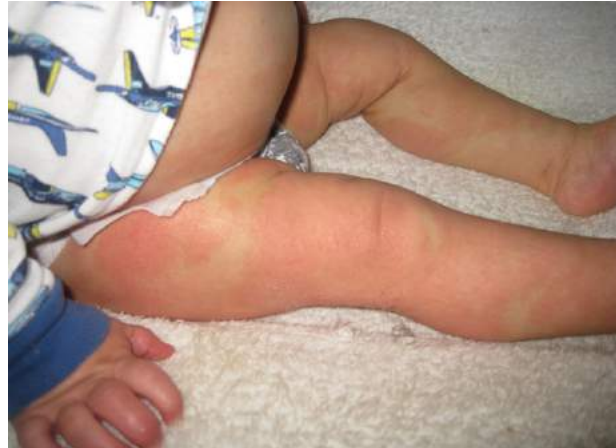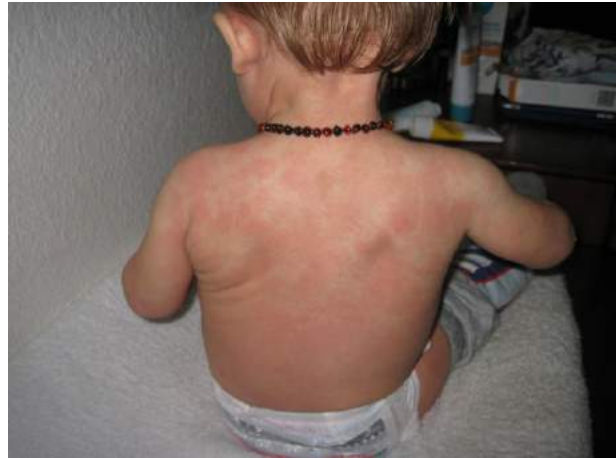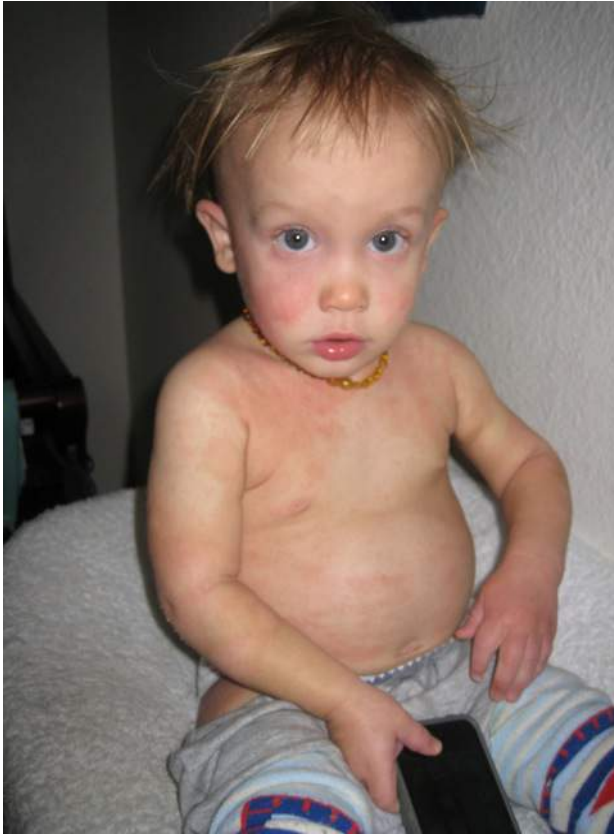Case study 20 (Feb 2015)

Male, aged 14 months when started on Aron Regimen

Prior to commencing Aron Regimen	Age when diagnosed with atopic eczema	5 weeks
	Under treatment of GP or Dermatologist prior to commencing Aron Regimen	GP
	Most recent treatment prior to commencing Aron Regimen (immunosuppressants: any time; rest: previous year)	Topical steroids: Clocortolone Pivalate 0.1% Oral steroids: Yes Topical immunosuppressants: No Oral immunosuppressants: No Antihistamines: Yes
	Any hospital emergency or elective admissions related to atopic eczema since diagnosis? If yes, how many?	No
	Any absences from school due to eczema (other than clinic appointments)?	N/A
Since commencing Aron Regimen	Date started the Aron Regimen	Jan 2015
	Current treatment	September 2017: 1-2 apps per week, spot treatment September 2016: 1 app per day to small spots February 2016: 2 apps per day to just arms and legs unless there's a flare July 2015: Applied 2 times per day, then 3 x per day Feb 2015: Applied 3 times a day Mix of steroid, antibiotic and moisturiser creams
	Any hospital emergency or elective admissions related to atopic eczema since commencing Aron Regimen?	No
	Any absences from school due to eczema (other than clinic appointments or initial week of Aron Regimen)?	N/A

Case study 20 – male, aged 14 months

Photos before commencing Aron Regimen

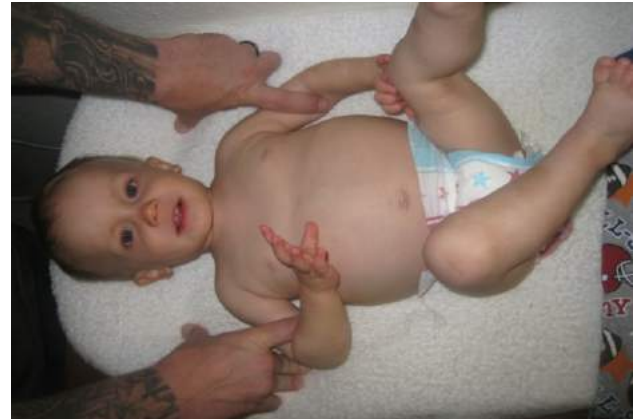
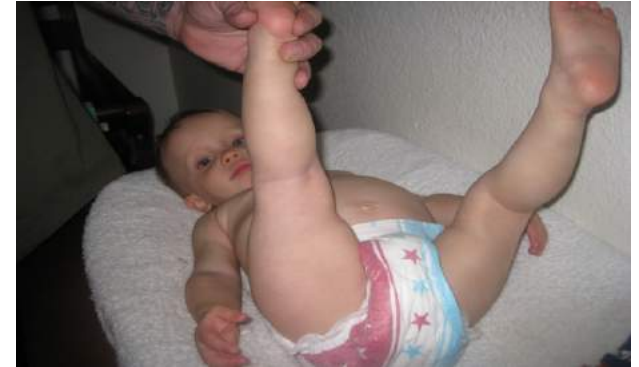
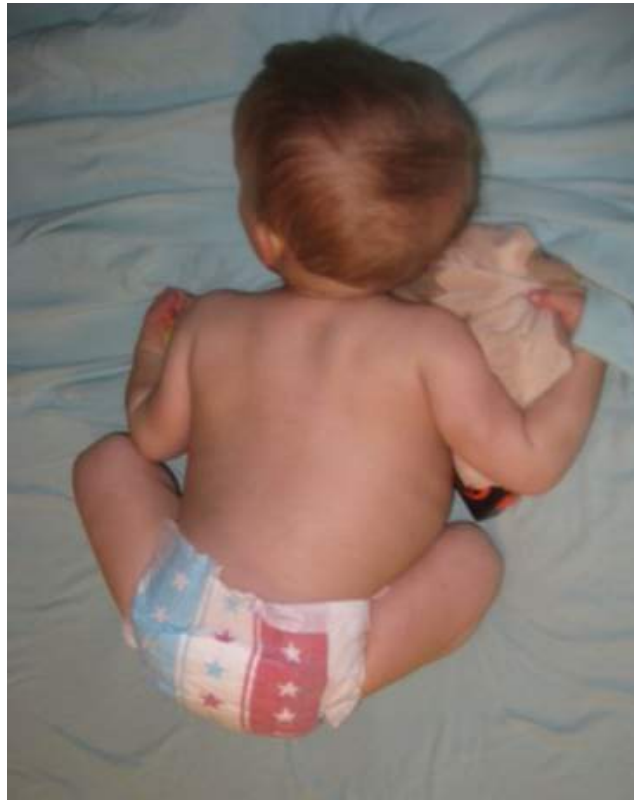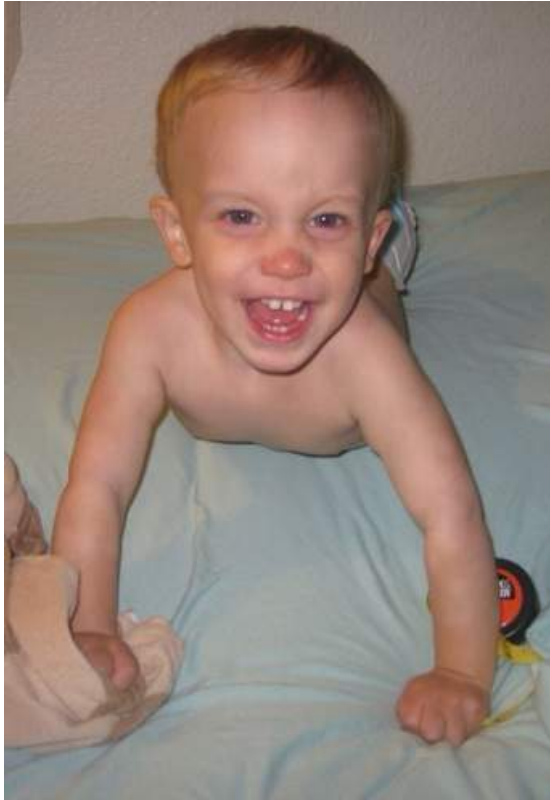Note from parents:

Double layered clothing, every cream you can find, antihistamines for sleep, two hours max sleep at night, mom distracted from siblings needs. Depression and searching for an answer nonstop.

Case study 20 – male, aged 14 months

Photos after commencing Aron Regimen



Note from parents:

Two applications and slept through the night, continued sleep, household stress alleviated. Bath time is fun! One layer of clothing without the need to itch, Happy clear eyed baby and the ability to determine true triggers.

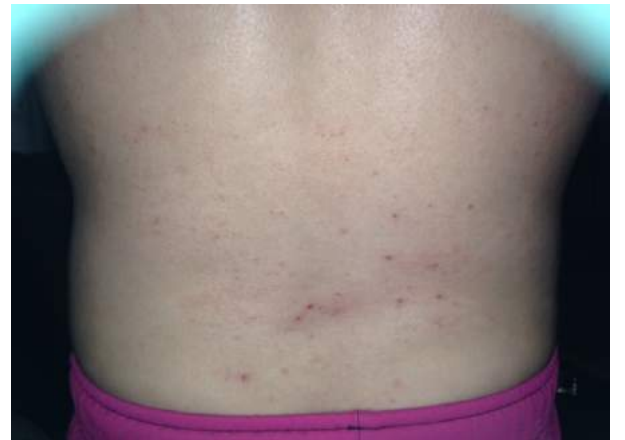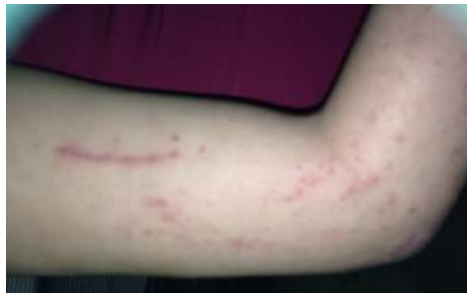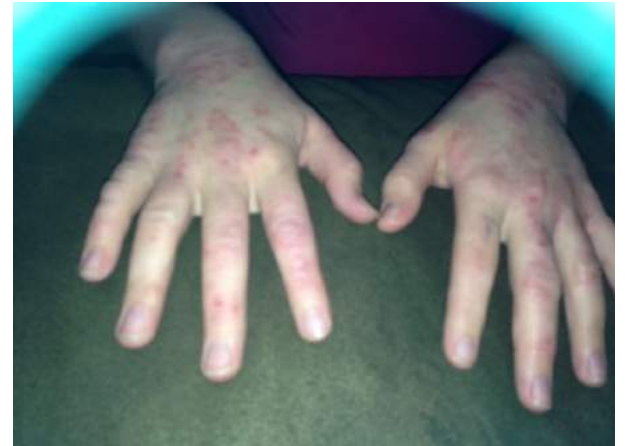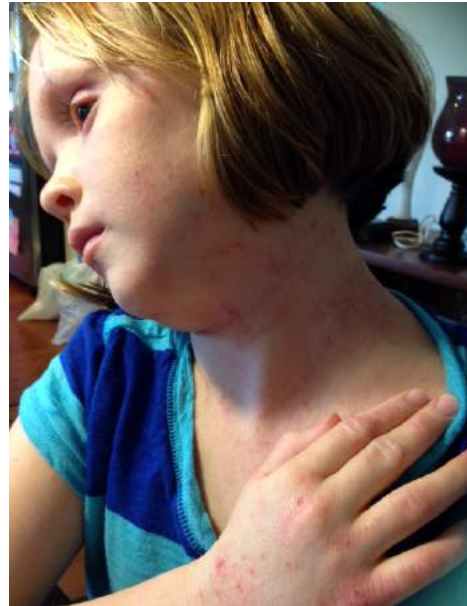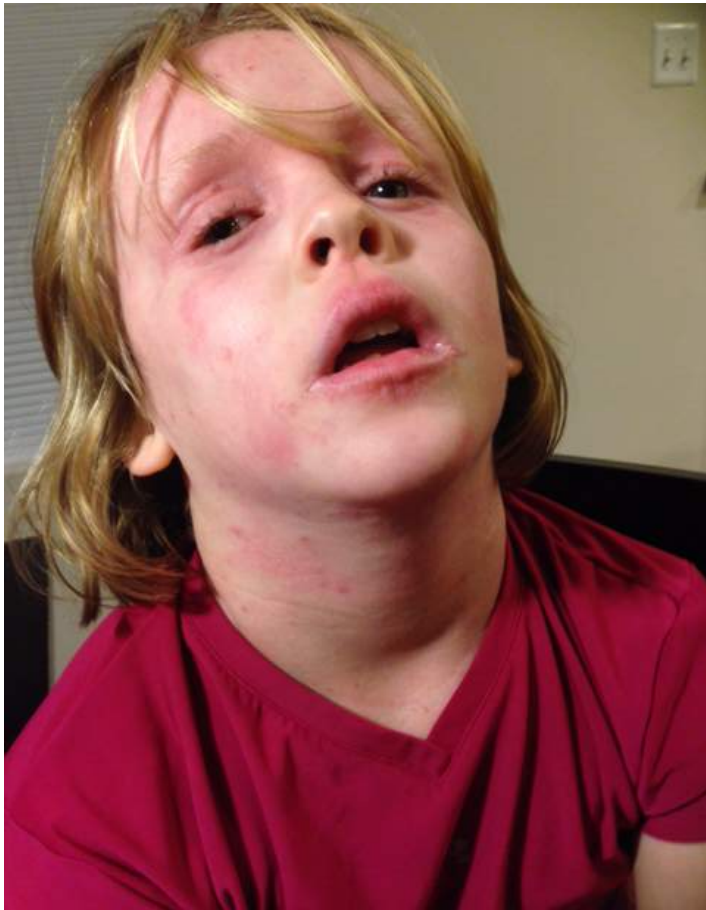Case study 21 (March 2015)

Female, aged 10 when started on Aron Regimen (Oct 2014)

Prior to commencing Aron Regimen	Age when diagnosed with atopic eczema	4 months
	Under treatment of GP or Dermatologist prior to commencing Aron Regimen	Dermatologist
	Most recent treatment prior to commencing Aron Regimen (immunosuppressants: any time; rest: previous year)	Topical steroids: Betamethasone, Triamcinolone, Desonide, Hydrocortisone Oral steroids: Yes Topical immunosuppressants: Yes (Elidel, Protopic) Oral immunosuppressants: No Antihistamines: Yes
	Any hospital emergency or elective admissions related to atopic eczema since diagnosis? If yes, how many?	Yes (one)
	Any absences from school due to eczema (other than clinic appointments)?	Yes
Since commencing Aron Regimen	Date started the Aron Regimen	Oct 2014
	Current treatment	September 2017: Spot treating 1 x per week September 2016: Spot treating 1 x per week February 2016: Applied 3 x per week, spot treatment only August 2015: Applied 1 x daily March 2015: Applied 2 days out of 3 to the face, and 2-1-2-1-2 to the body (once one day, twice the next) Mix of steroid, antibiotic and moisturiser creams
	Any hospital emergency or elective admissions related to atopic eczema since commencing Aron Regimen?	No
	Any absences from school due to eczema (other than clinic appointments or initial week of Aron Regimen)?	N/A

Case study 21 – female, aged 10

Photos before commencing Aron Regimen

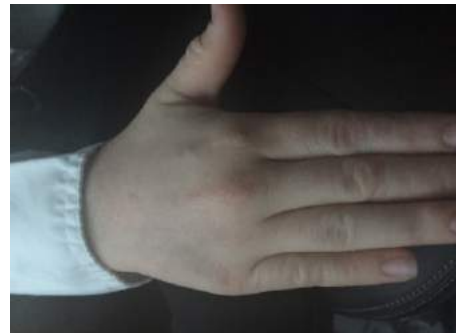
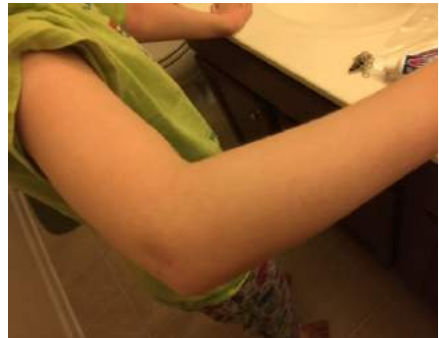
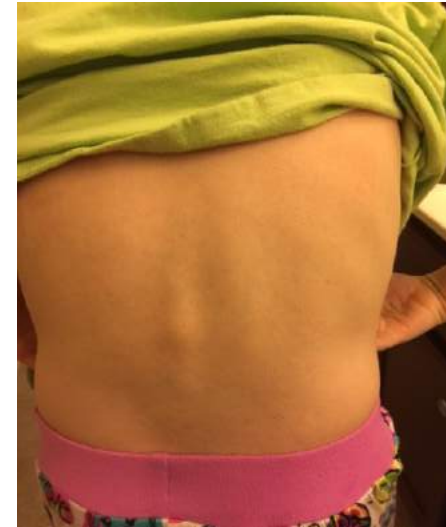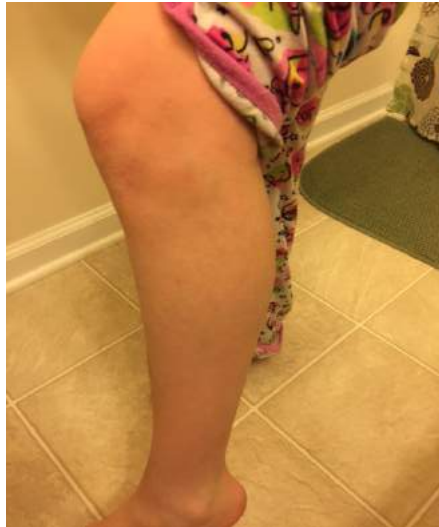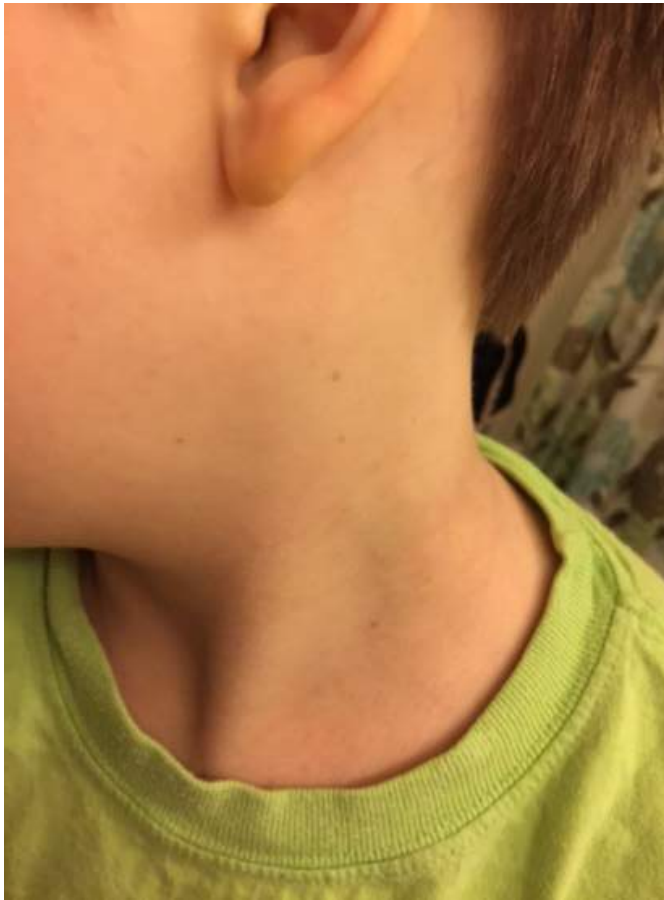Note from parents:

Eczema had control of our life prior to Dr Aron's help, our daughter was miserable. Daily wet wrapping and bleach baths and the long sleepless nights.

Case study 21 – female, aged 10

Photos after commencing Aron Regimen



Note from parents:

Our daughter immediately began sleeping through the night and absolutely no itching. She is able to focus at school, run and play outside more without the worry of a flare up and the treatment is very simple to maintain.

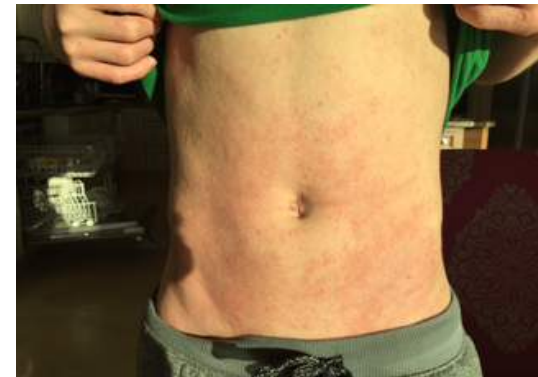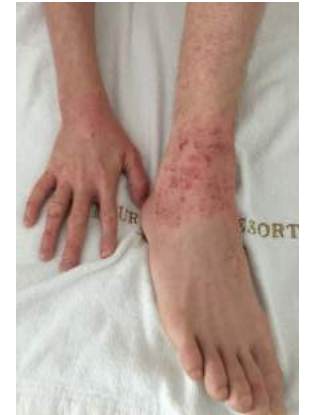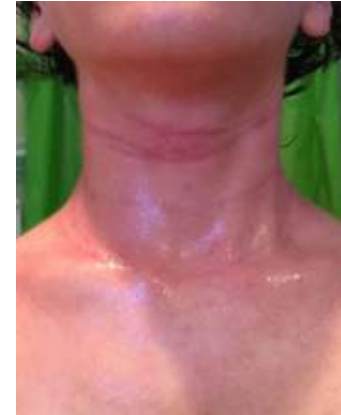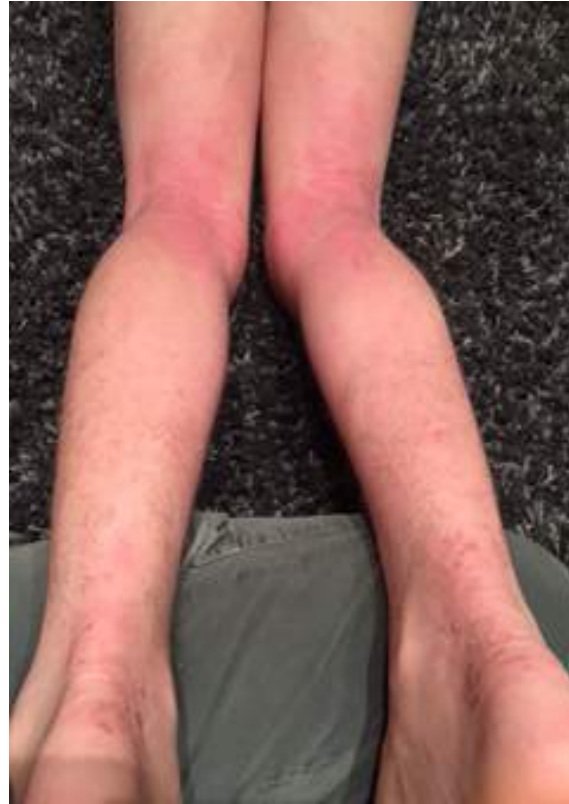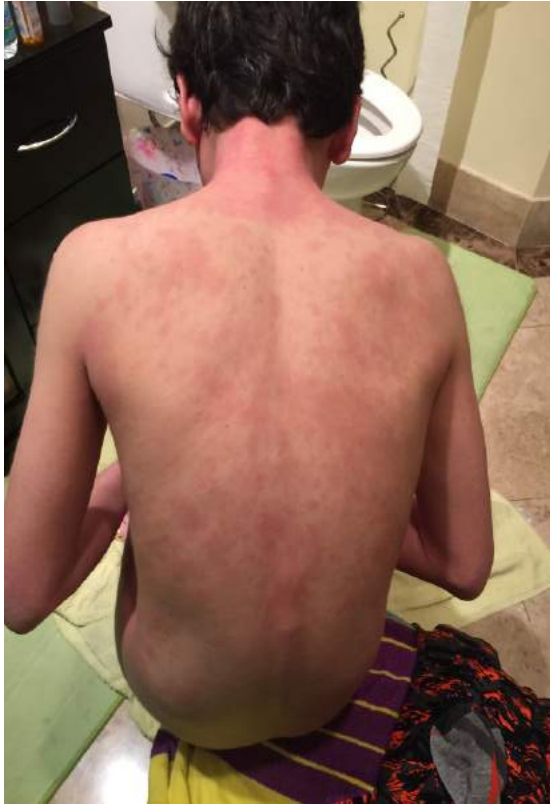Case study 22 (April 2015)

Male, aged 14 when started on Aron Regimen

Prior to commencing Aron Regimen	Age when diagnosed with atopic eczema	3 months
	Under treatment of GP or Dermatologist prior to commencing Aron Regimen	Dermatologist
	Most recent treatment prior to commencing Aron Regimen (immunosuppressants: any time; rest: previous year)	Topical steroids: Triamcinolone, Desonide, Mometasone, Hydrocortisone, Fluticasone Propionate Oral steroids: Yes Topical immunosuppressants: Yes (Protopic) Oral immunosuppressants: Yes Antihistamines: Yes
	Any hospital emergency or elective admissions related to atopic eczema since diagnosis? If yes, how many?	Yes, 2 admissions
	Any absences from school due to eczema (other than clinic appointments)?	Yes
Since commencing Aron Regimen	Date started the Aron Regimen	Feb 2015
	Current treatment	September 2017: 3-4 x per week. Steroid & emollient only. September 2016: As below. Steroid & emollient for maintenance about 3 applications per week. Original compound for any flares. February 2016: Steroid & emollient for maintenance about 3 applications per week. Original compound for any flares. July 2015: Antibiotic removed. Applied 1 x per day on small areas. Apr 2015: Applied once one day, twice the next Mix of steroid, antibiotic and moisturiser creams
	Any hospital emergency or elective admissions related to atopic eczema since commencing Aron Regimen?	No
	Any absences from school due to eczema (other than clinic appointments or initial week of Aron Regimen)?	No

Case study 22 – male, aged 14

Photos before commencing Aron Regimen

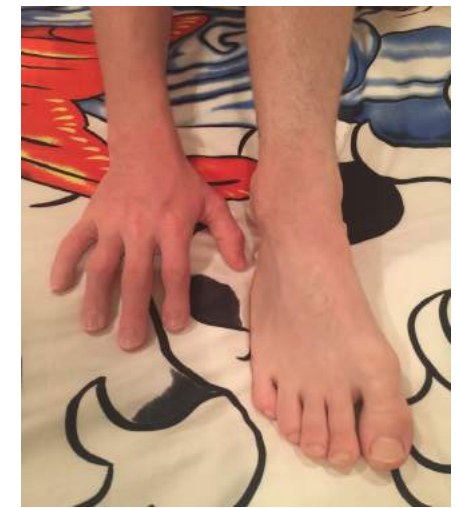
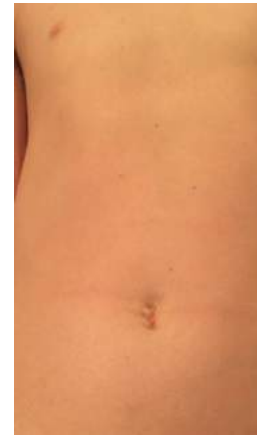
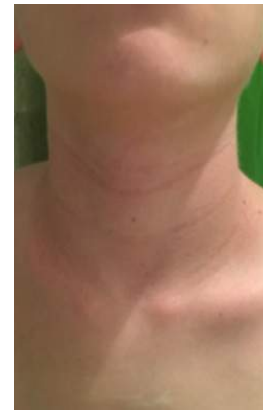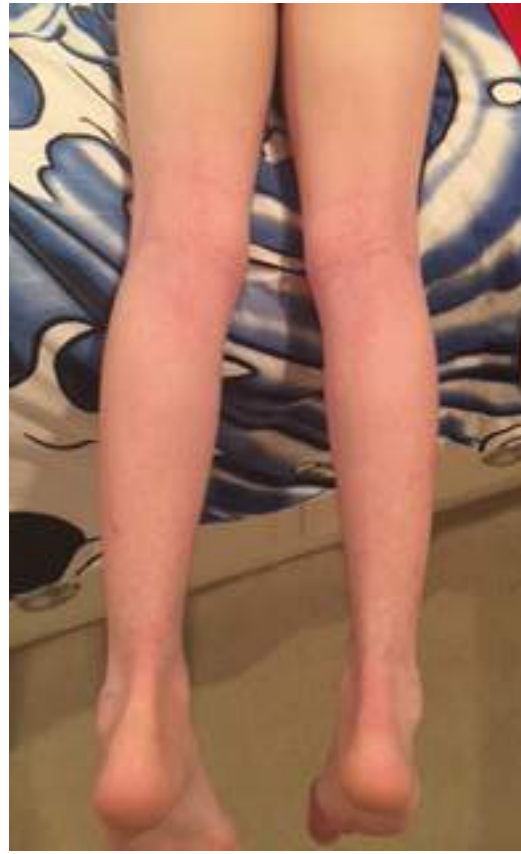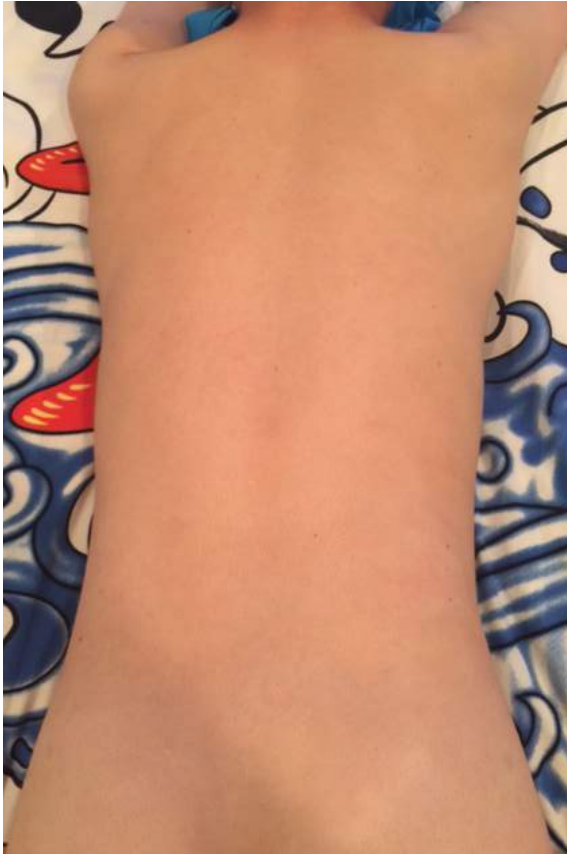Note from parents:

Life before Dr Aron was basically hell. My 14 year old son was bedridden due to his skin; he had intense insomnia, couldn't walk, couldn't turn his head, was in pain, skin shedding all over, took 5 hour daily baths and missed 3 months of 8th grade due to severe TSW. He couldn't even open his mouth to eat some days because of the cuts around his mouth. It was like we were living in a hospital and had to drop out of life for a while.

Case study 22 – male, aged 14

Photos after commencing Aron Regimen



Note from parents:

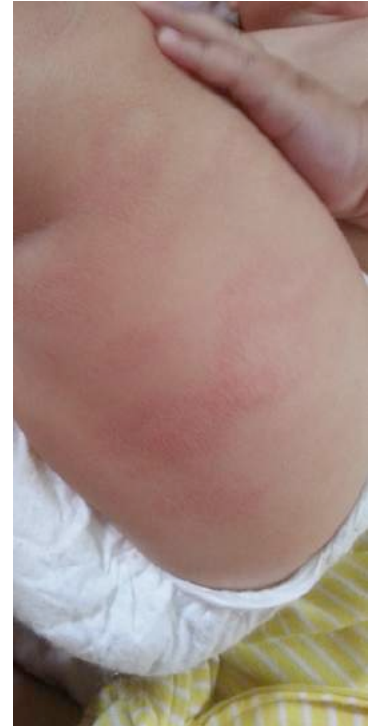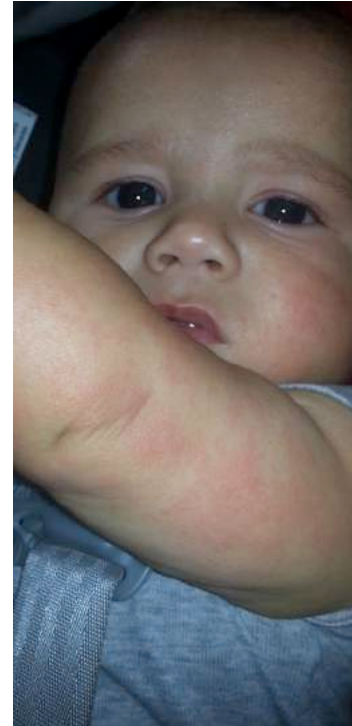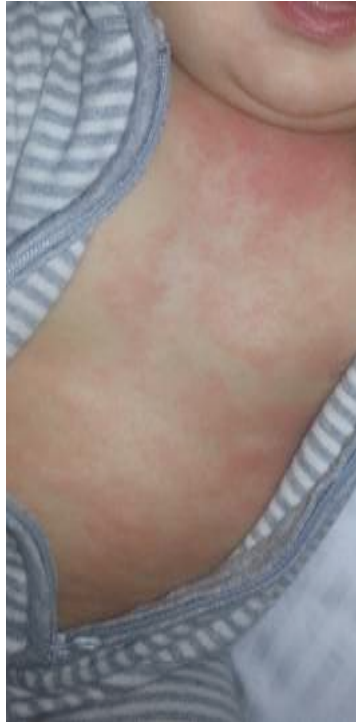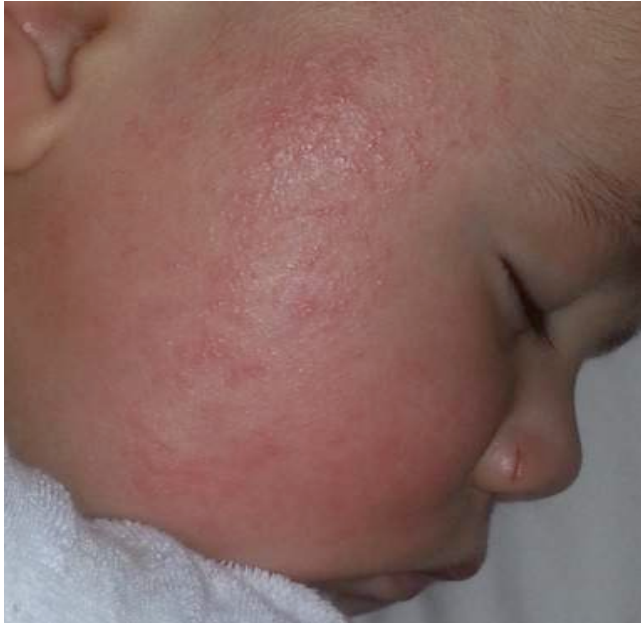Our whole family has our life back. I still can't believe it's real. Imagine your child suffering everyday of his life for 14 YEARS and not being able to stop his pain? Horrifying and so grateful to have finally found Dr Aron.

Case study 23 (April 2015)

Male, aged 7 months when started on Aron Regimen

Prior to commencing Aron Regimen	Age when diagnosed with atopic eczema	5 months
	Under treatment of GP or Dermatologist prior to commencing Aron Regimen	GP
	Most recent treatment prior to commencing Aron Regimen (immunosuppressants: any time; rest: previous year)	Topical steroids: Hydrocortisone Oral steroids: No Topical immunosuppressants: No Oral immunosuppressants: No Antihistamines: No
	Any hospital emergency or elective admissions related to atopic eczema since diagnosis? If yes, how many?	No
	Any absences from school due to eczema (other than clinic appointments)?	N/A
Since commencing Aron Regimen	Date started the Aron Regimen	Oct 2014
	Current treatment	September 2017: Still in remission September 2016: Still in remission February 2016: In remission since November 2015 August 2015: Applied 3 x weekly April 2015: Applied 4 days per week Mix of steroid, antibiotic and moisturiser creams
	Any hospital emergency or elective admissions related to atopic eczema since commencing Aron Regimen?	No
	Any absences from school due to eczema (other than clinic appointments or initial week of Aron Regimen)?	No

Case study 23 – male, aged 7 months
Photos before commencing Aron Regimen

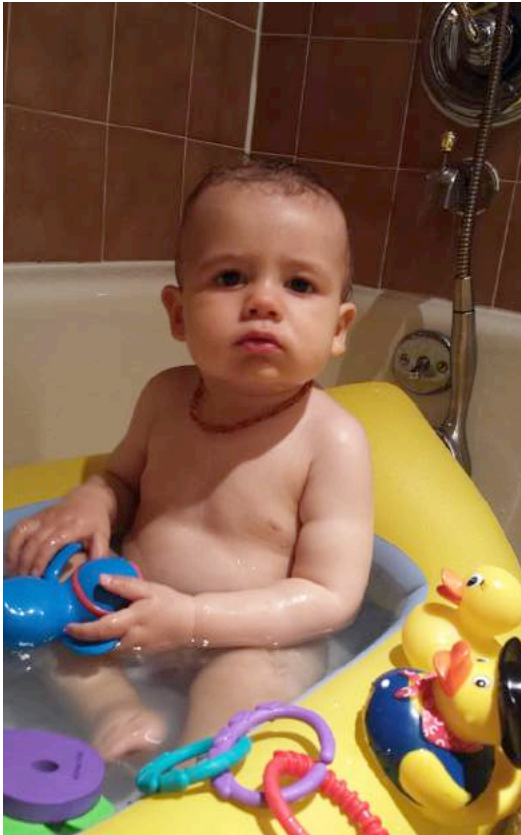

Note from parents:

Very itchy on scalp and body. Red dry scaly patches and constant flare ups difficult to pinpoint.

Case study 23 – male, aged 7 months

Photos after commencing Aron Regimen



Note from parents:

Itching stopped immediately! Skin started improving within 24 hours and remained clear since. We haven't had any flare ups at all even during teething. Only one small patch which went away quickly. Baby is growing and healthy and no more skin problems. Also stopped having hives from perfume exposure which before the treatment was additional to the eczema. Once treatment started hives were less and less frequent and completely disappearing allowing him to now be exposed to perfumes without reactions.

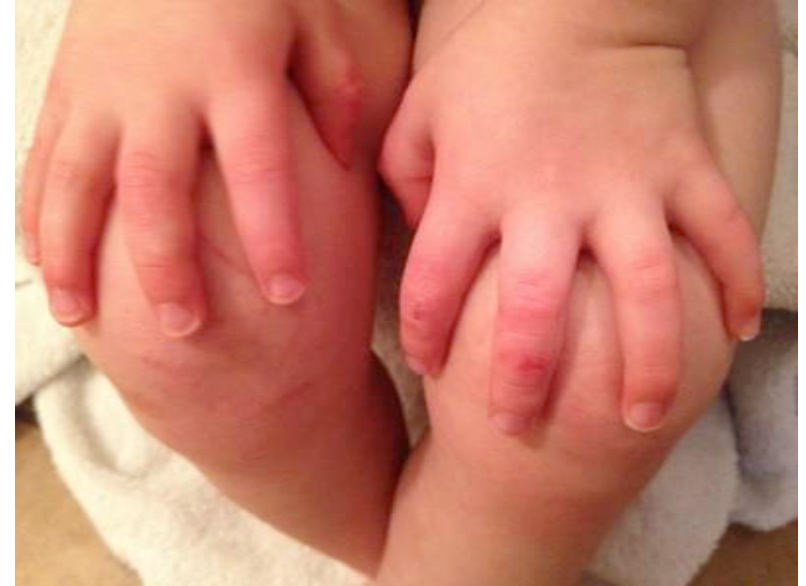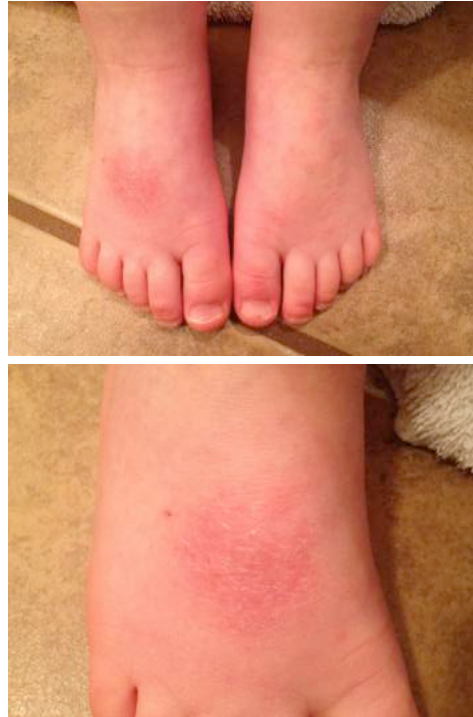Case study 24 (April 2015)

Male, aged 2 when started on Aron Regimen

Prior to commencing Aron Regimen	Age when diagnosed with atopic eczema	6 weeks
	Under treatment of GP or Dermatologist prior to commencing Aron Regimen	Dermatologist
	Most recent treatment prior to commencing Aron Regimen (immunosuppressants: any time; rest: previous year)	Topical steroids: Fluticasone, Desonide .05%, Hydrocortisone 2.5%, Triamcinolone .1% Oral steroids: No Topical immunosuppressants: Yes. Protopic Oral immunosuppressants: No Antihistamines: Yes
	Any hospital emergency or elective admissions related to atopic eczema since diagnosis? If yes, how many?	No
	Any absences from school due to eczema (other than clinic appointments)?	Yes
Since commencing Aron Regimen	Date started the Aron Regimen	Jan 2015
	Current treatment	September 2017: 2 apps/day on toes / soles and one knee spot plus occasional apps to face when needed September 2016: 2-3 apps on feet every day, and spot treatment as needed February 2016: Just one finger gets 2 x daily, and spot treatment if required April 2015: 2 x daily Mix of steroid, antibiotic and moisturiser creams
	Any hospital emergency or elective admissions related to atopic eczema since commencing Aron Regimen?	No
	Any absences from school due to eczema (other than clinic appointments or initial week of Aron Regimen)?	No

Case study 24 – male, aged 2 years

Photos before commencing Aron Regimen

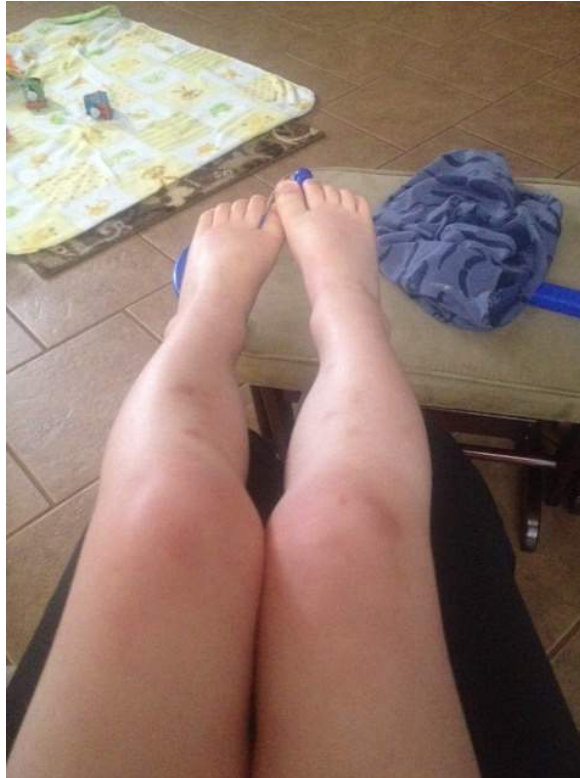
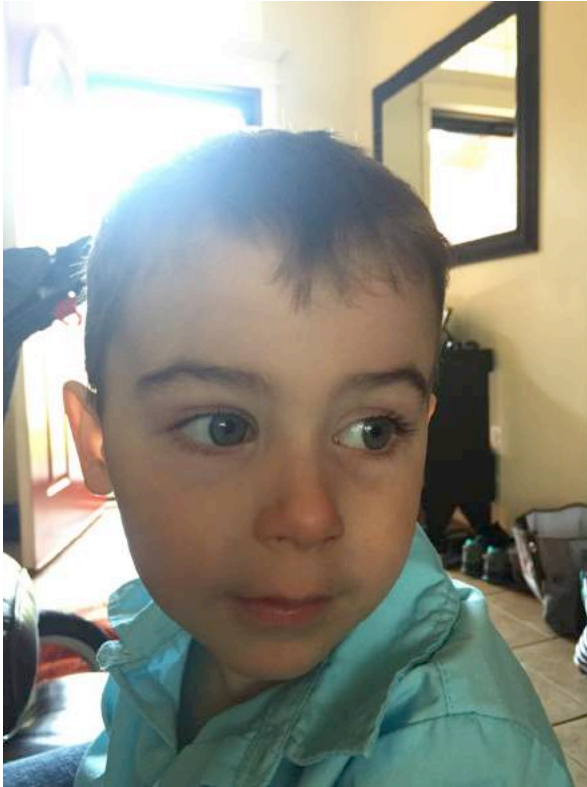
Note from parents:

Quality of life revolved around eczema and possible triggers, wet wraps, soaks, helicopter parenting, restless sleep. At one point, there was no quality of life, only existing to manage the eczema and almost no sleep even with drowsy medications.

Case study 24 – male, aged 2 years

Photos after commencing Aron Regimen



Note from parents:

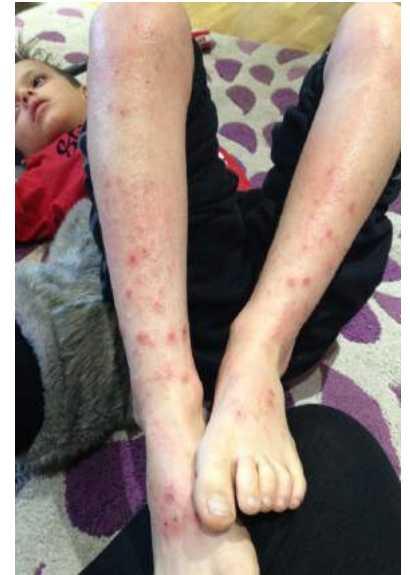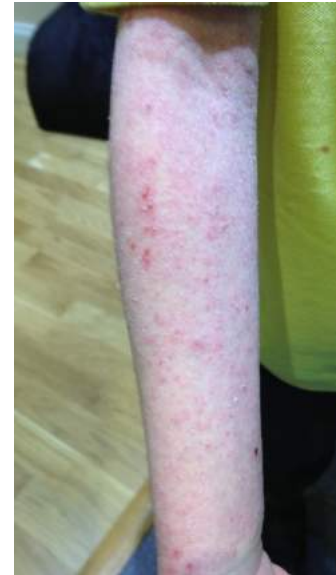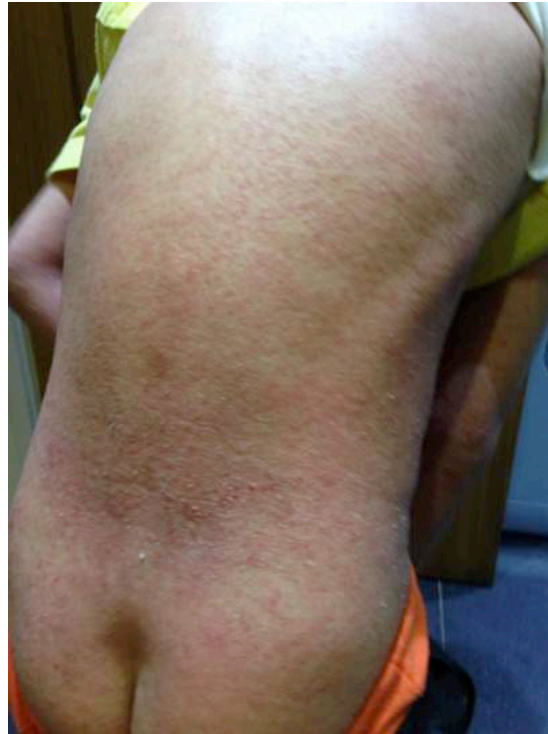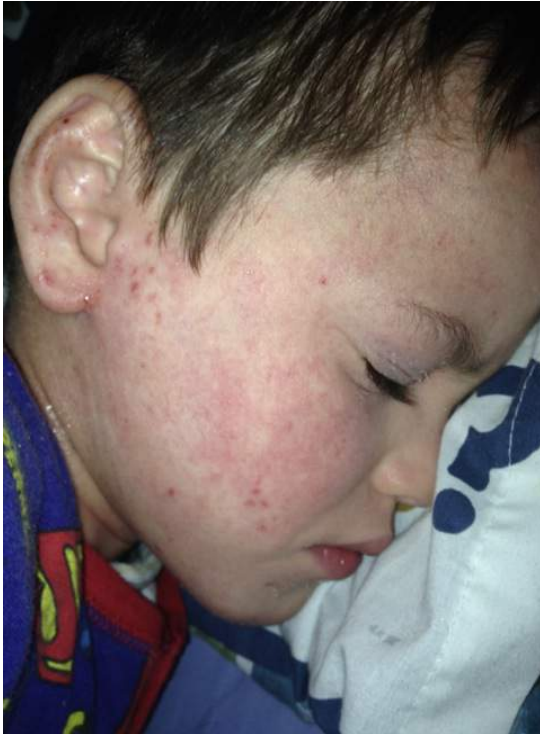Quality of life is 100%. We only avoid peanuts, sleep is awesome for him (like never before), absolutely no itchy patches, bath time is much quicker and enjoyable than before with all the wet wrapping.

Case study 25 (May 2015)

Male, aged 5 when started on Aron Regimen

Prior to commencing Aron Regimen	Age when diagnosed with atopic eczema	6 months
	Under treatment of GP or Dermatologist prior to commencing Aron Regimen	Dermatologist
	Most recent treatment prior to commencing Aron Regimen (immunosuppressants: any time; rest: previous year)	Topical steroids: Elecon Oral steroids: Yes Topical immunosuppressants: No Oral immunosuppressants: No Antihistamines: Yes
	Any hospital emergency or elective admissions related to atopic eczema since diagnosis? If yes, how many?	No
	Any absences from school due to eczema (other than clinic appointments)?	Yes
Since commencing Aron Regimen	Date started the Aron Regimen	Oct 2014
	Current treatment	September 2017: 1 x every 2 weeks, spot treatment September 2016: 1 x application every 2-3 days February 2016: 1 x daily May 2015: 2 x daily Mix of steroid, antibiotic and moisturiser creams
	Any hospital emergency or elective admissions related to atopic eczema since commencing Aron Regimen?	No
	Any absences from school due to eczema (other than clinic appointments or initial week of Aron Regimen)?	Yes

Case study 25 – male, aged 5 years
Photos before commencing Aron Regimen

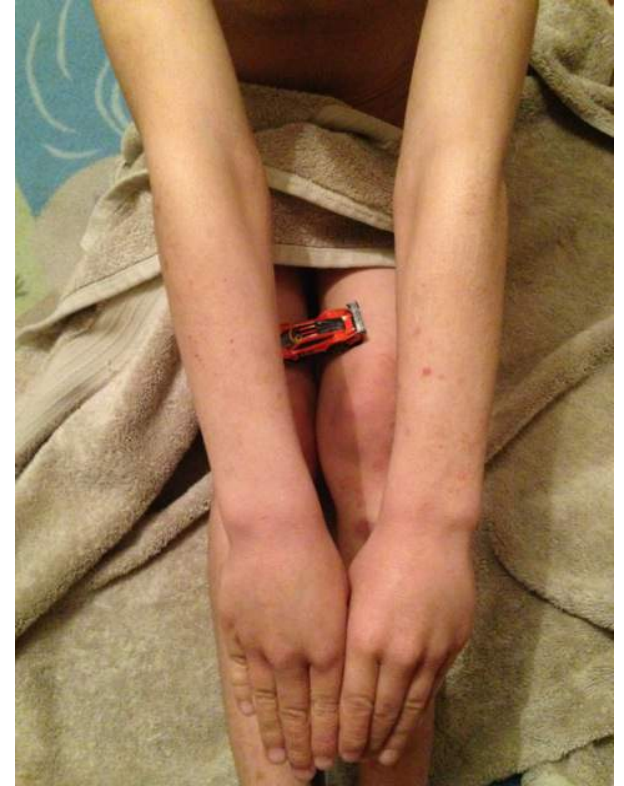
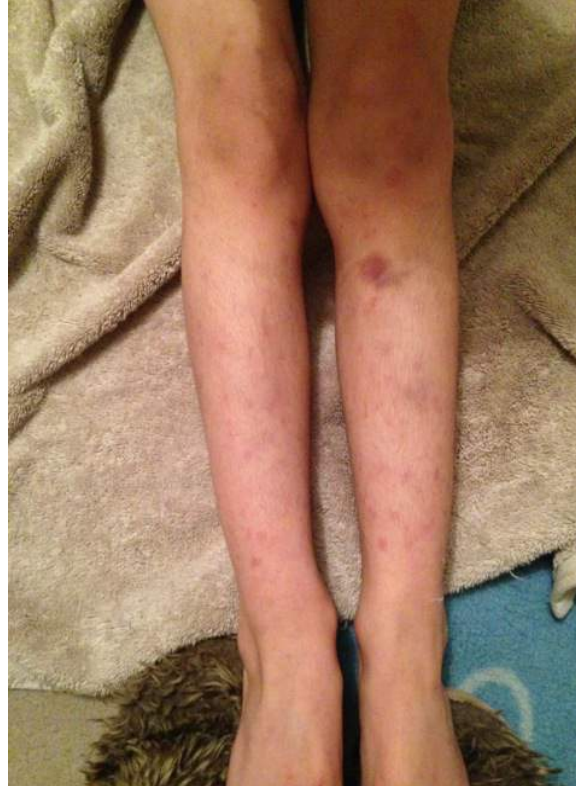
Note from parents:

Sleeping for few hours at a time. Could not sleep alone due to itching. Deeply depressed. Unconfident. Torturous cries while bathing developing a really fear of bath time and whole ritual of thick emollients etc.

Case study 25 – male, aged 5 years

Photos after commencing Aron Regimen



Note from parents:

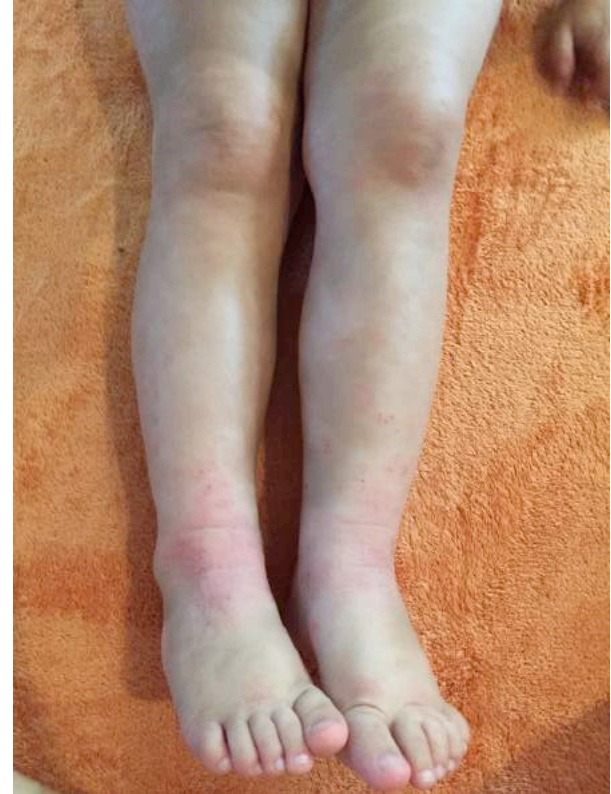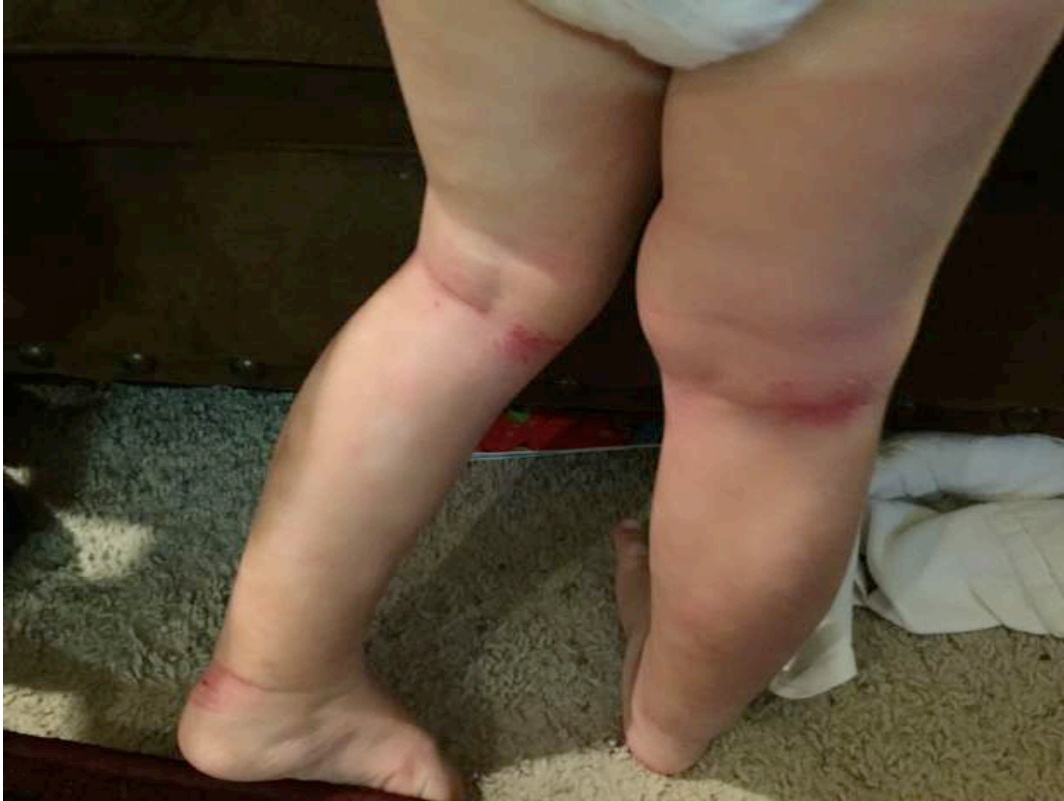Now sleeps through the night. Happy, confident interacts with his friends and teachers. Now is able to enjoy baths with his brothers and play in the water. Still itches slightly, more from habit though.

Case study 26 (May 2015)

Male, aged 2 when started on Aron Regimen

Prior to commencing Aron Regimen	Age when diagnosed with atopic eczema	6 months
	Under treatment of GP or Dermatologist prior to commencing Aron Regimen	GP
	Most recent treatment prior to commencing Aron Regimen (immunosuppressants: any time; rest: previous year)	Topical steroids: Hydrocortisone valerate Oral steroids: Yes Topical immunosuppressants: No Oral immunosuppressants: No Antihistamines: Yes
	Any hospital emergency or elective admissions related to atopic eczema since diagnosis? If yes, how many?	No
	Any absences from school due to eczema (other than clinic appointments)?	N/A
Since commencing Aron Regimen	Date started the Aron Regimen	April 2015
	Current treatment	September 2017: 1 x every 2 weeks September 2016: 1 x weekly if needed February 2016: Applied 2 x weekly August 2015: Applied 2 x weekly May 2015: Applied 2 x daily Mix of steroid, antibiotic and moisturiser creams
	Any hospital emergency or elective admissions related to atopic eczema since commencing Aron Regimen?	No
	Any absences from school due to eczema (other than clinic appointments or initial week of Aron Regimen)?	N/A

Case study 26 – male, aged 2 years
Photos before commencing Aron Regimen

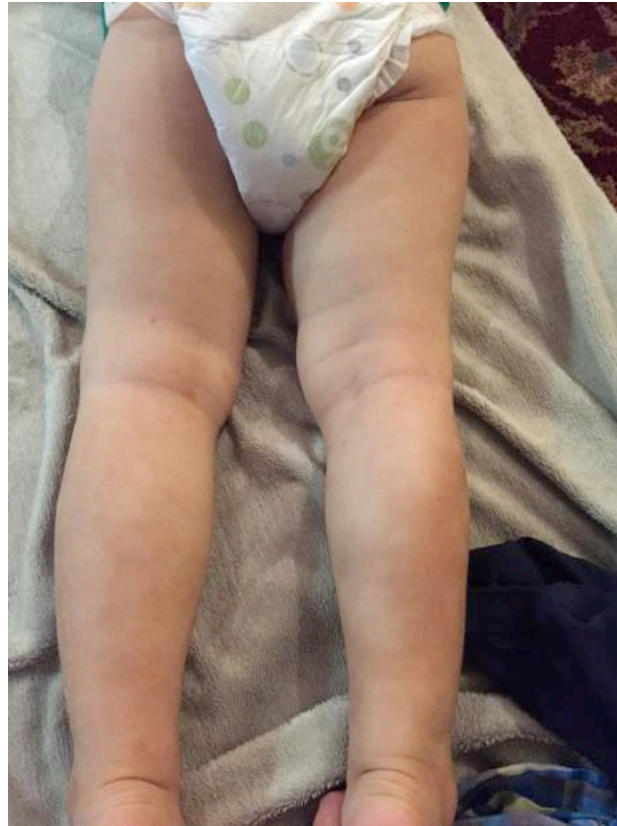
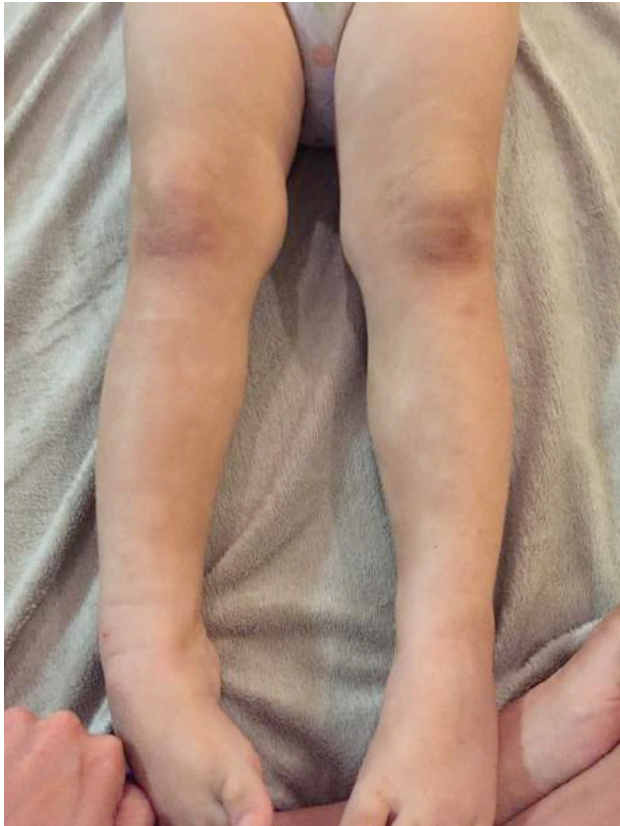
Note from parents:

Worrying all the time. Constantly trying to figure out what caused the last flare. Reminding him to quit scratching. Hating putting lotion on.

Case study 26 – male, aged 2 years

Photos after commencing Aron Regimen



Note from parents:

Life changing. Less worrying for me. Not constantly telling him to quit scratching.

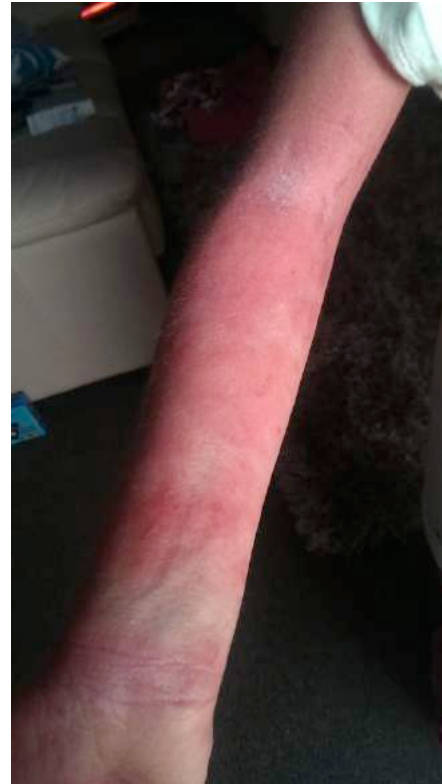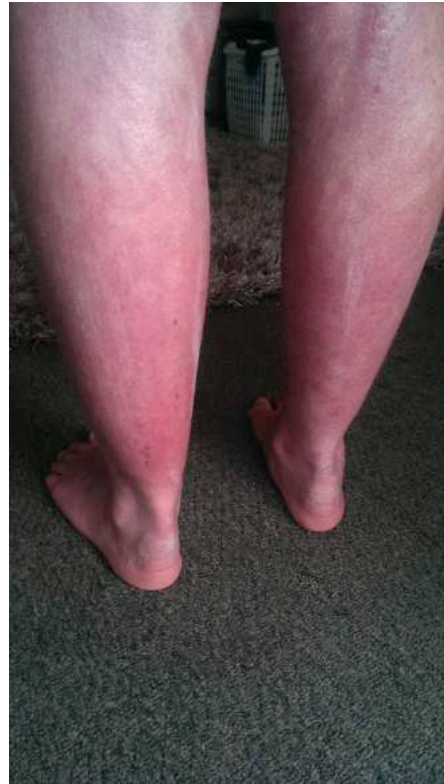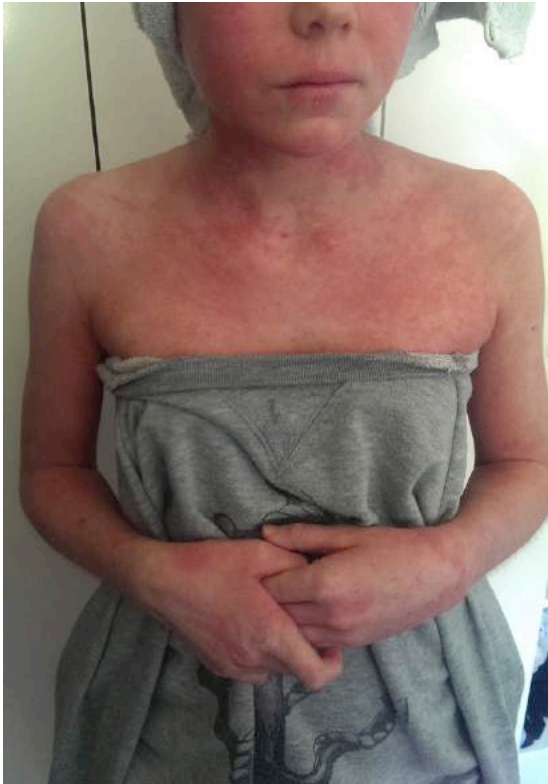Case study 27 (May 2015)

Female, aged 13 when started on Aron Regimen

Prior to commencing Aron Regimen	Age when diagnosed with atopic eczema	Birth
	Under treatment of GP or Dermatologist prior to commencing Aron Regimen	Dermatologist
	Most recent treatment prior to commencing Aron Regimen (immunosuppressants: any time; rest: previous year)	Topical steroids: Dermal, Betamethasone, Hydrocortisone, Elocon, Nerisone, Advantan, Eumovate Oral steroids: Yes Topical immunosuppressants: Yes Eiledel (pimecrolimus) Oral immunosuppressants: No Antihistamines: Yes
	Any hospital emergency or elective admissions related to atopic eczema since diagnosis? If yes, how many?	Yes – 4 or more admissions
	Any absences from school due to eczema (other than clinic appointments)?	Yes
Since commencing Aron Regimen	Date started the Aron Regimen	Nov 2014
	Current treatment	September 2017: 1 app per day; also neat steroid/antibiotic for stubborn areas September 2016: 1 app every second day, hands being treated with neat steroid due to flaring February 2016: 2 apps one day, 1 app the next August 2015: 2 apps one day, 1 app the next May 2015: Applied 2 x daily Mix of steroid, antibiotic and moisturiser creams
	Any hospital emergency or elective admissions related to atopic eczema since commencing Aron Regimen?	Yes
	Any absences from school due to eczema (other than clinic appointments or initial week of Aron Regimen)?	Yes

Case study 27 – female, aged 13 years

Photos before commencing Aron Regimen



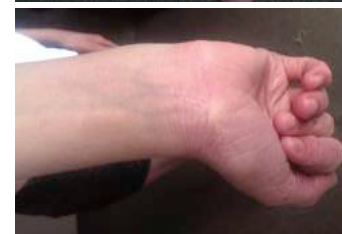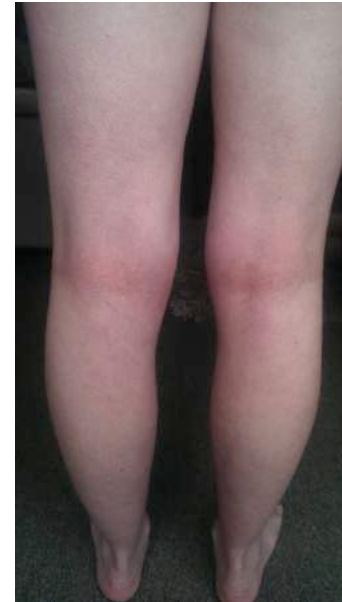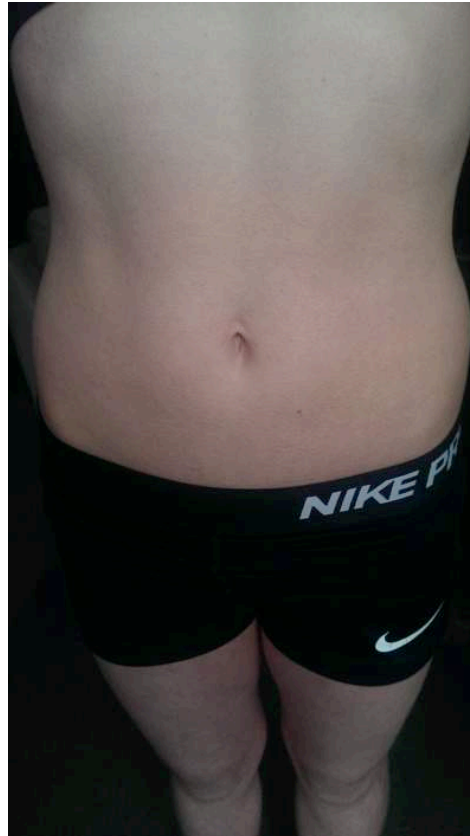
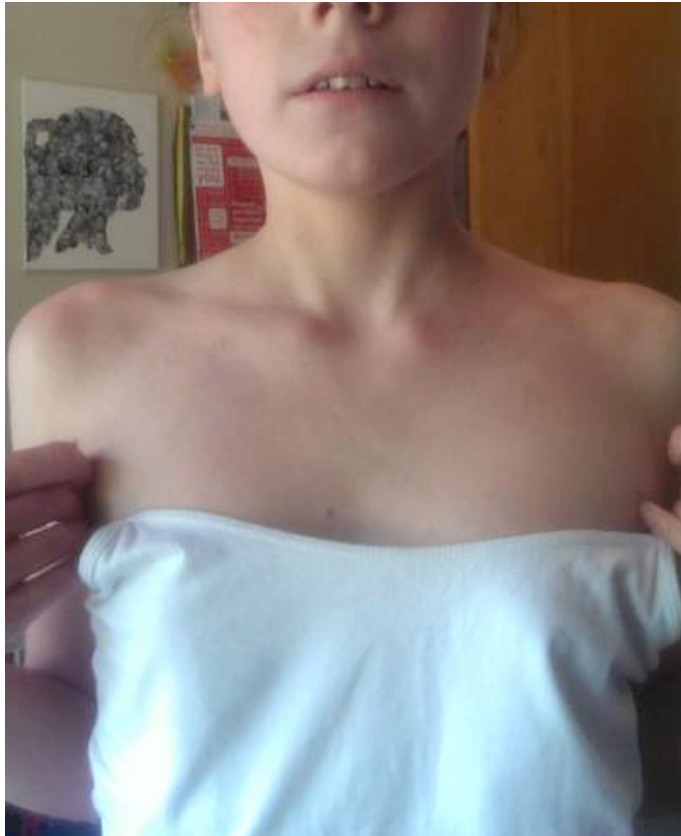Note from parents:

Before we started, Zoe suffered for 13 years from uncontrollable itch, pain, had never slept through an entire night, constant out of control staph infections, frequent hospital admissions, constant oral antibiotics, and oral steroids, failure to thrive as far as height and weight went, lack of self esteem and reactions to environmental allergies that were uncontrollable.

We, as parents were stressed, sleep deprived and felt helpless and unable to find anything that would help us to take away Zoe's pain and suffering.

Case study 27 – female, aged 13 years

Photos after commencing Aron Regimen



Note from parents:

For the first time ever, Zoe is sleeping through the night, is growing (like a weed!) has clear skin except for a couple of stubborn patches, but even they are improving and she is off ALL medications including antihistamines. She is attending school, and her school work is improving hugely. She is now also able to hang out and do normal "teenager things" without her skin dictating what she can and can't take part in. Slowly but surely we are seeing a happy confident change in her that is the best thing in the world to see.

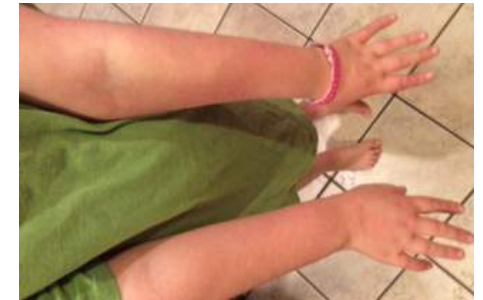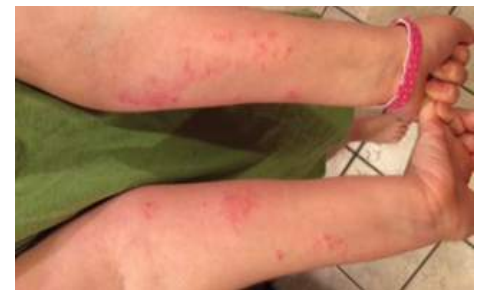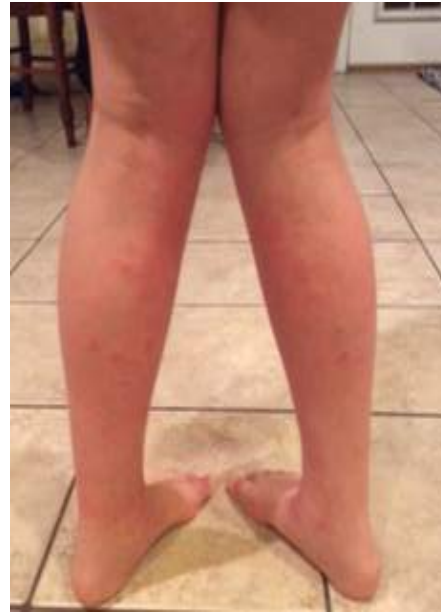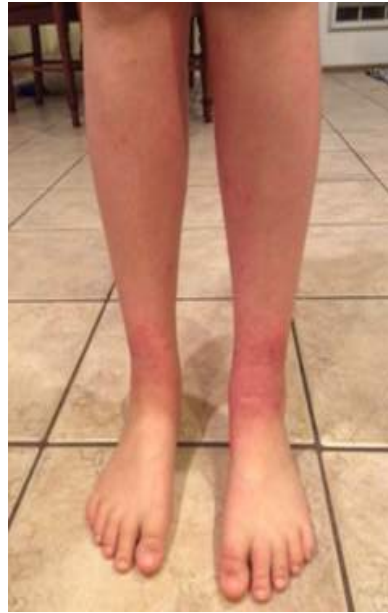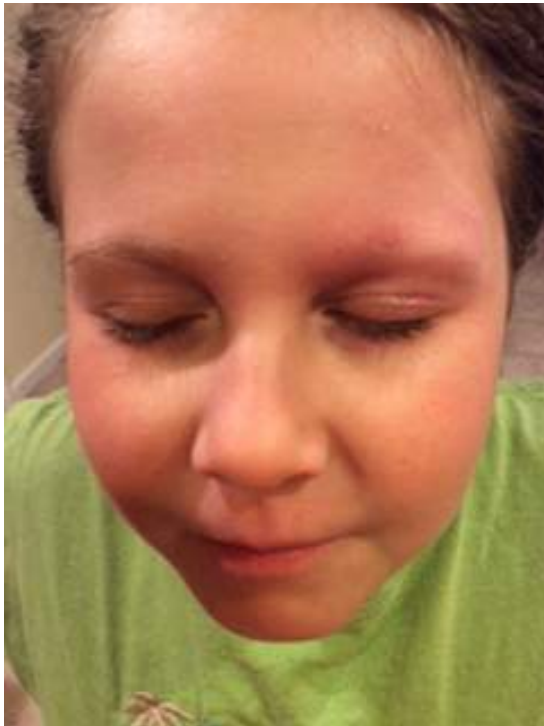Case study 28 (May 2015)

Female, aged 11 when started on Aron Regimen

Prior to commencing Aron Regimen	Age when diagnosed with atopic eczema	9 months
	Under treatment of GP or Dermatologist prior to commencing Aron Regimen	Dermatologist
	Most recent treatment prior to commencing Aron Regimen (immunosuppressants: any time; rest: previous year)	Topical steroids: triamcinolone, desonide, flucinolone, desoxymetasone Oral steroids: Yes Topical immunosuppressants: Yes – Eiledel Oral immunosuppressants: No Antihistamines: Yes
	Any hospital emergency or elective admissions related to atopic eczema since diagnosis? If yes, how many?	No
	Any absences from school due to eczema (other than clinic appointments)?	Yes
Since commencing Aron Regimen	Date started the Aron Regimen	Feb 2014
	Current treatment	September 2017: In remission September 2016: Only spot treating for flares, approx once per month January 2016: 1 x weekly application May 2015: 1 x daily Mix of steroid, antibiotic and moisturiser creams
	Any hospital emergency or elective admissions related to atopic eczema since commencing Aron Regimen?	No
	Any absences from school due to eczema (other than clinic appointments or initial week of Aron Regimen)?	No

Case study 28 – female, aged 11 years

Photos before commencing Aron Regimen

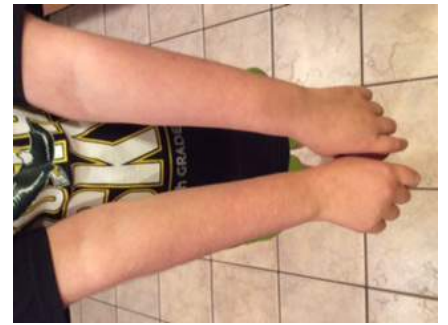
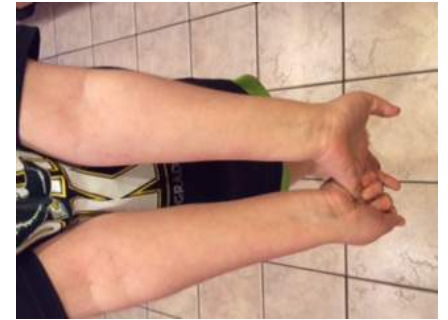
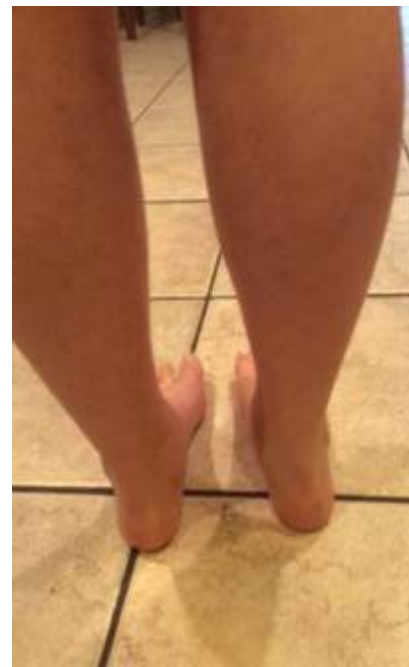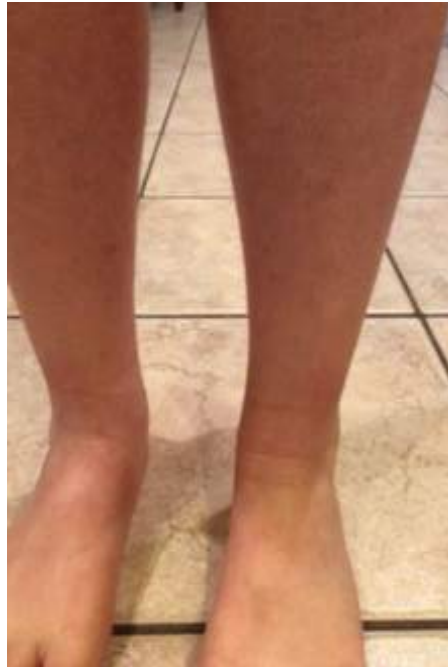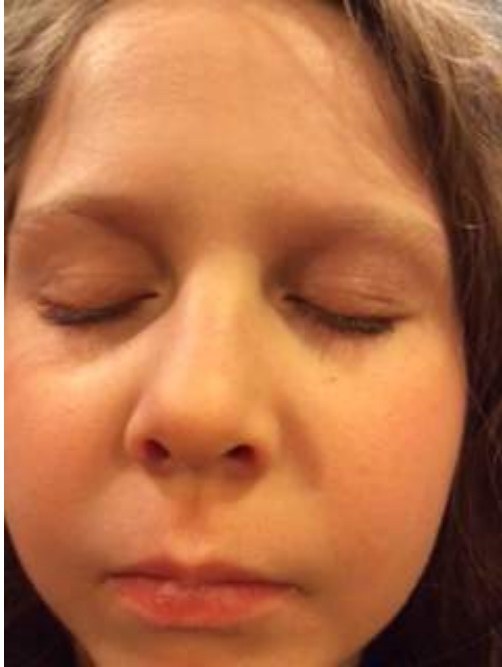Note from parents:

We spent endless hours fighting this disease just to keep it in some state of "normalcy": apply this ointment and that ointment, wet wrapping, phototherapy, not to mention taking enough hydroxyzine on a daily basis that would knock out a horse.

Case study 28 – female, aged 11 years

Photos after commencing Aron Regimen



Note from parents:

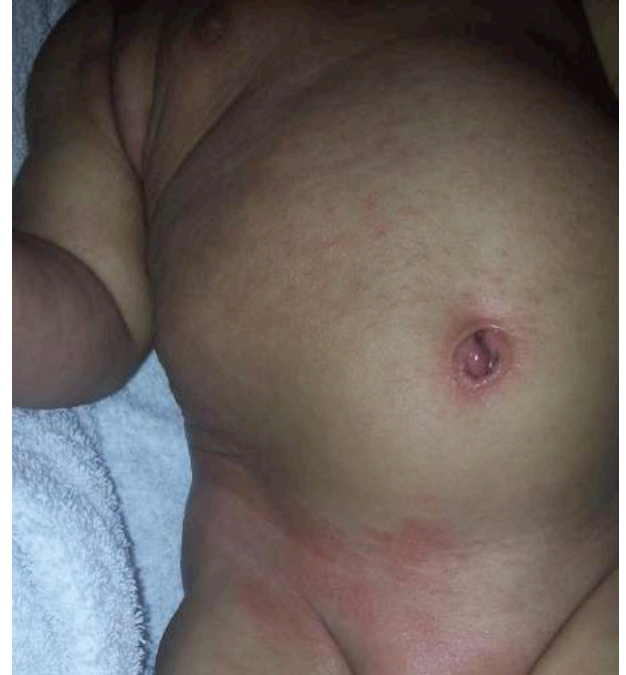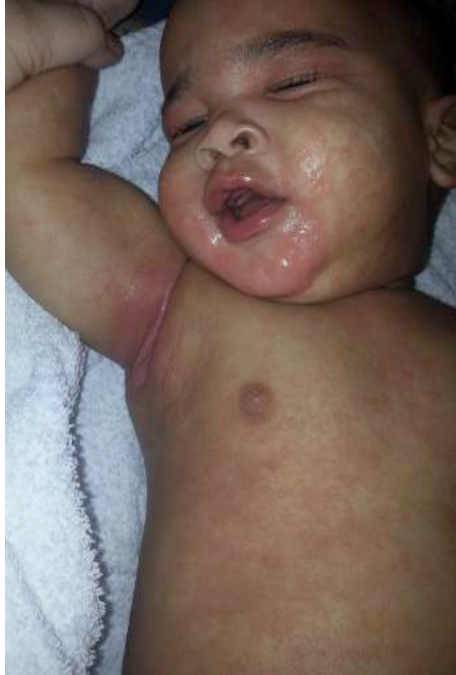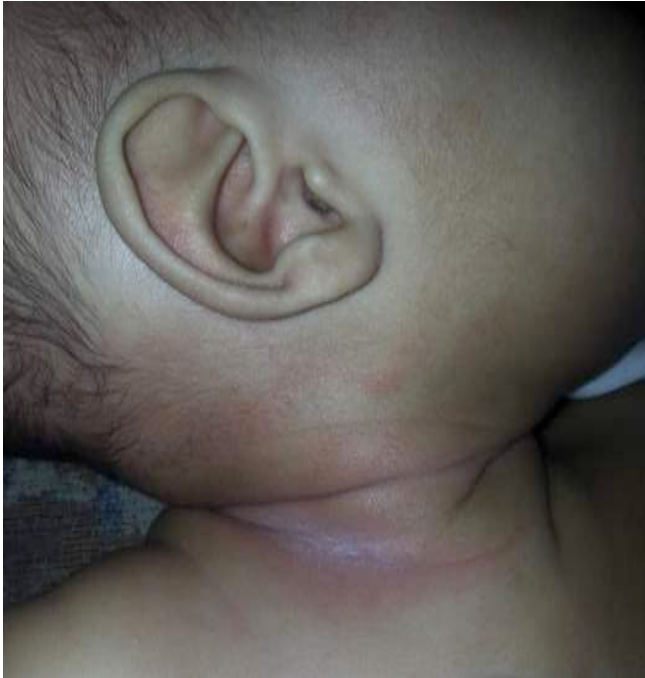NO ITCH! She no longer takes hydroxyzine; our skin routine takes only seconds and I have bright, vibrant, happy child!

Case study 29 (May 2015)

Male, aged 6 months when started on Aron Regimen

Prior to commencing Aron Regimen	Age when diagnosed with atopic eczema	5.5 months
	Under treatment of GP or Dermatologist prior to commencing Aron Regimen	GP
	Most recent treatment prior to commencing Aron Regimen (immunosuppressants: any time; rest: previous year)	Topical steroids: Advantan (Methylprednisolone aceponate), hydrocortisone 0.1%, Elocon Oral steroids: No Topical immunosuppressants: No Oral immunosuppressants: No Antihistamines: Yes
	Any hospital emergency or elective admissions related to atopic eczema since diagnosis? If yes, how many?	No
	Any absences from school due to eczema (other than clinic appointments)?	N/A
Since commencing Aron Regimen	Date started the Aron Regimen	March 2015
	Current treatment	September 2017: 1 x daily September 2016: 1 x daily February 2016: 1 x daily, steroid diluted slightly further May 2015: 1 x daily Mix of steroid, antibiotic and moisturiser creams
	Any hospital emergency or elective admissions related to atopic eczema since commencing Aron Regimen?	No
	Any absences from school due to eczema (other than clinic appointments or initial week of Aron Regimen)?	N/A

Case study 29 – male, aged 6 months
Photos before commencing Aron Regimen

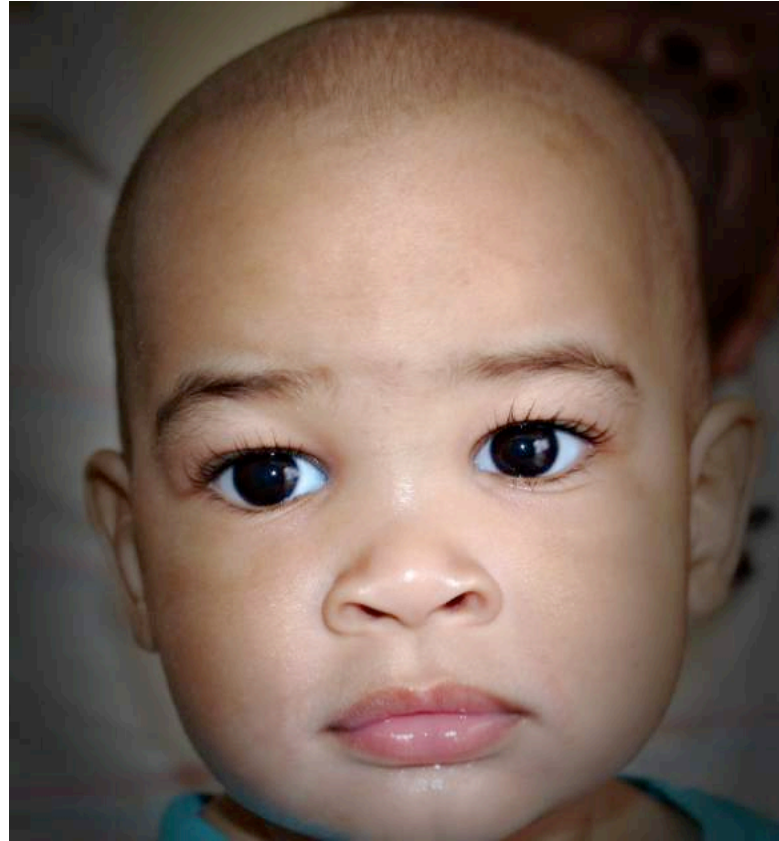
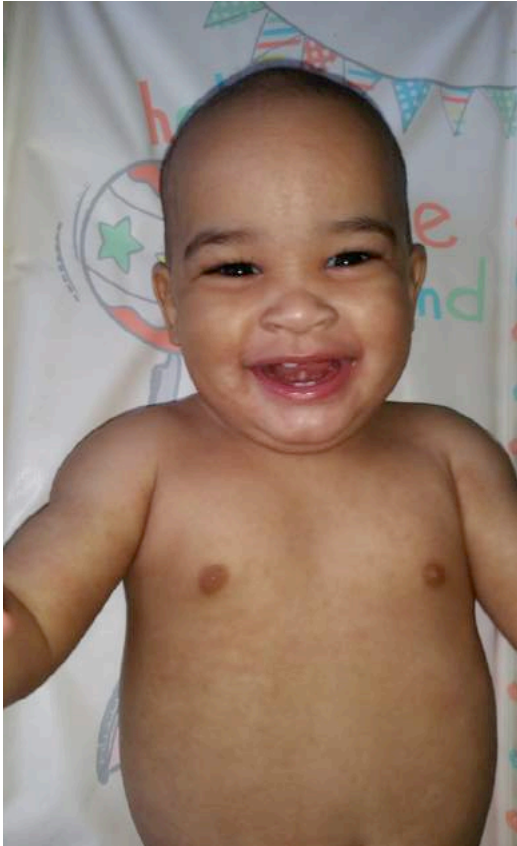
Note from parents:

His sleeping was very poor, multiple awakening at night. Not interested in playing or engaging socially, his development slowed down.

Case study 29 – male, aged 6 months

Photos after commencing Aron Regimen



Note from parents:

His sleeping through the night and he is now ahead of time with his milestones.

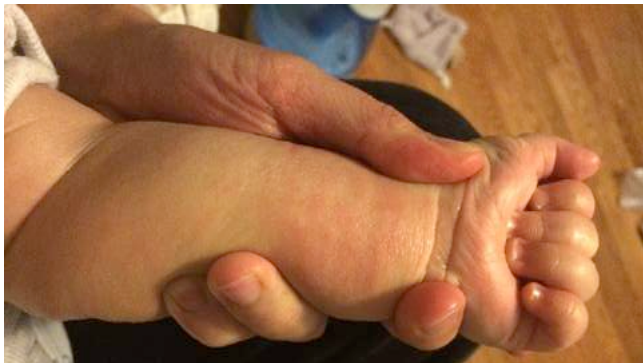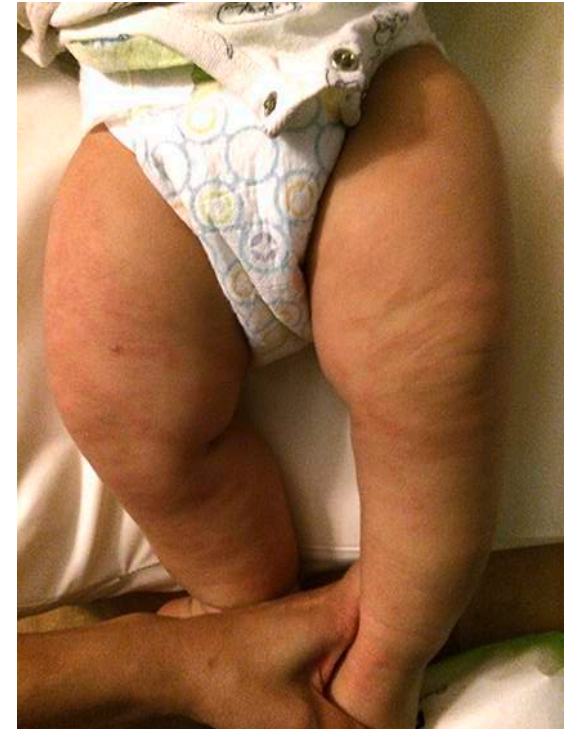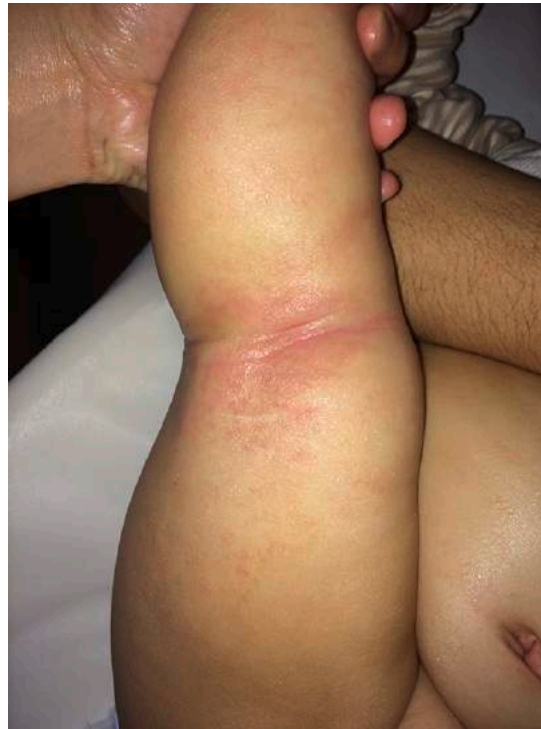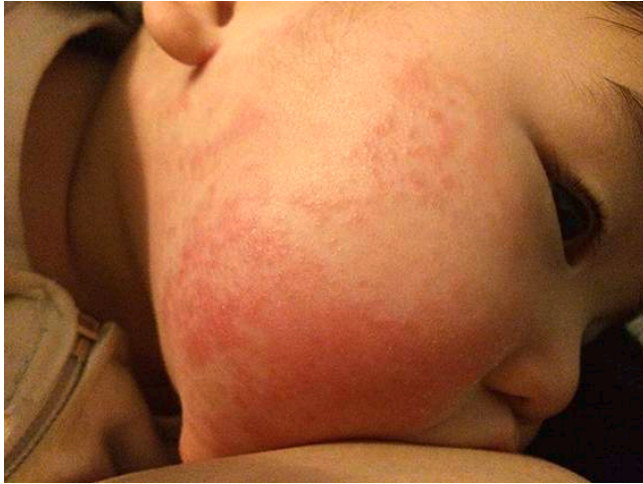Case study 30 (July 2015)

Male, aged 9 months when started on Aron Regimen

Prior to commencing Aron Regimen	Age when diagnosed with atopic eczema	4 months
	Under treatment of GP or Dermatologist prior to commencing Aron Regimen	Dermatologist
	Most recent treatment prior to commencing Aron Regimen (immunosuppressants: any time; rest: previous year)	Topical steroids: Hydrocortisone 1% Oral steroids: No Topical immunosuppressants: No Oral immunosuppressants: No Antihistamines: Yes
	Any hospital emergency or elective admissions related to atopic eczema since diagnosis? If yes, how many?	No
	Any absences from school due to eczema (other than clinic appointments)?	N/A
Since commencing Aron Regimen	Date started the Aron Regimen	April 2015
	Current treatment	September 2017: Body 2/3 times a week. Fingers and around mouth flair often – apps vary from 2x per day to 1 every 2 days September 2016: 3x daily on face on small spots, 3 x a week for most of body, except for 2x daily on fingers and tops of feet February 2016: 1212121 for facial area. 1x daily on limbs. Every 2nd day on torso. July 2015: 1 x daily Mix of steroid, antibiotic and moisturiser creams
	Any hospital emergency or elective admissions related to atopic eczema since commencing Aron Regimen?	No
	Any absences from school due to eczema (other than clinic appointments or initial week of Aron Regimen)?	N/A

Case study 30 – male, aged 9 months

Photos before commencing Aron Regimen

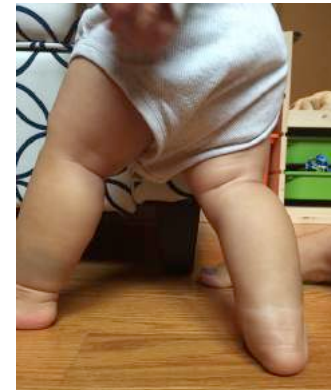
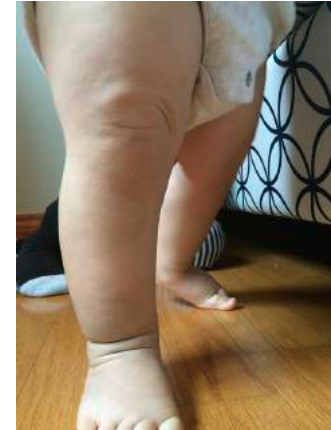
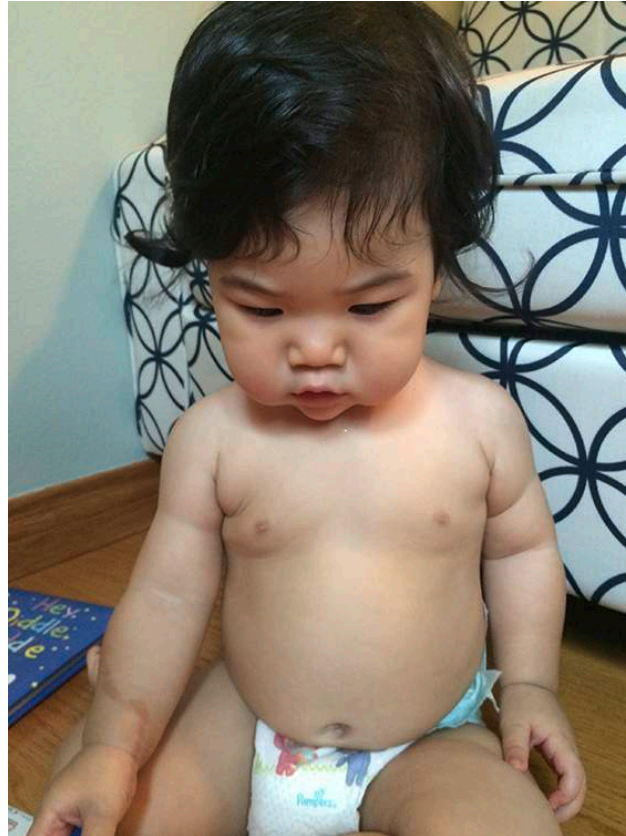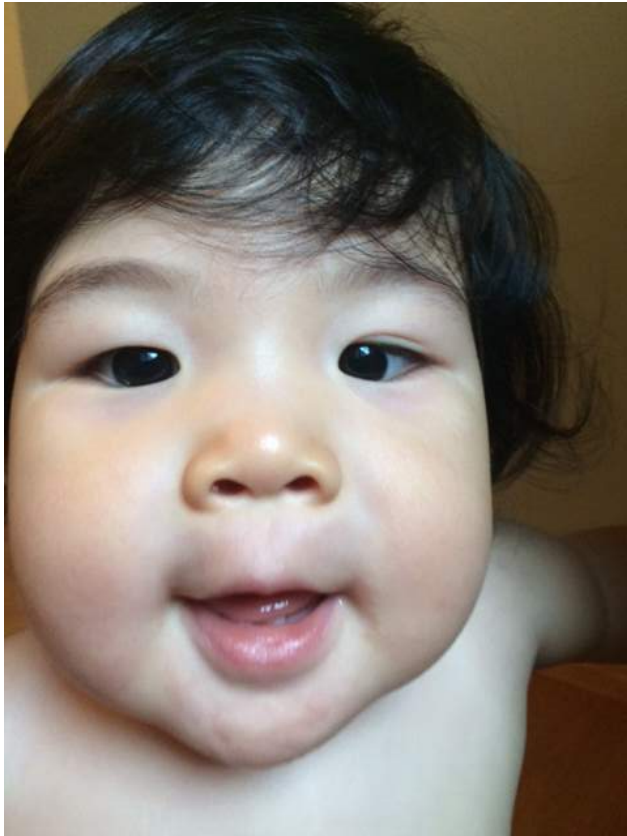Note from parents:

He had difficulty falling and staying asleep to the point where he had dark circles under his eyes. He couldn't do anything (play, eat, bath, diaper change, etc.) without scratching.

Case study 30 – male, aged 9 months

Photos after commencing Aron Regimen



Note from parents:

As parents, we often talk about how he is still our happy, adventurous little boy, just MORE. He can chase after his older brother without stopping to scratch. He can play for extended periods of time without being distracted by the itch. No more scratching and itching!

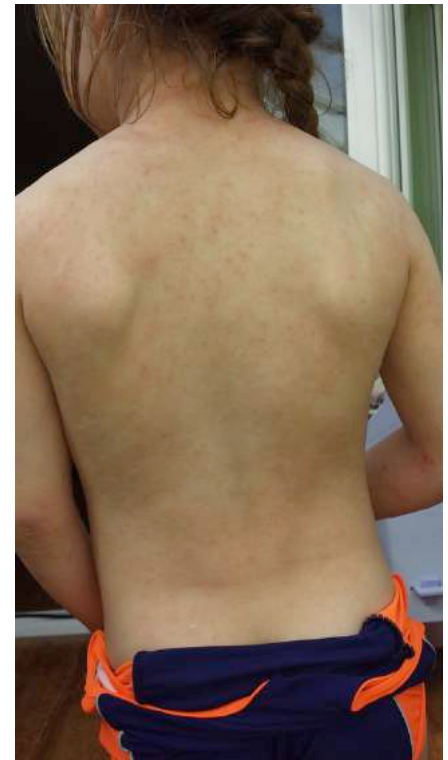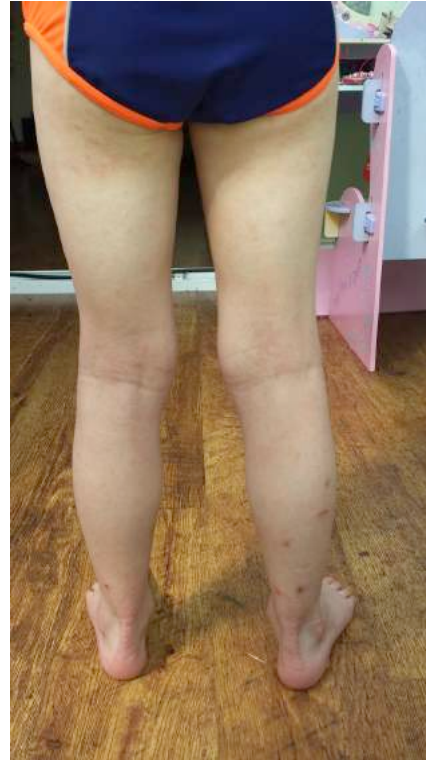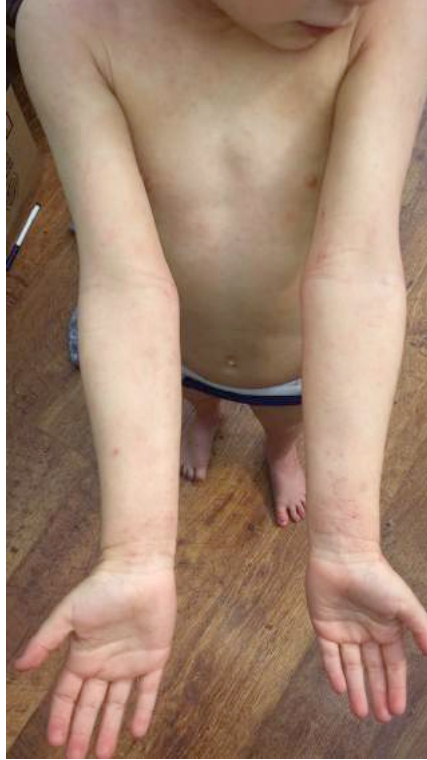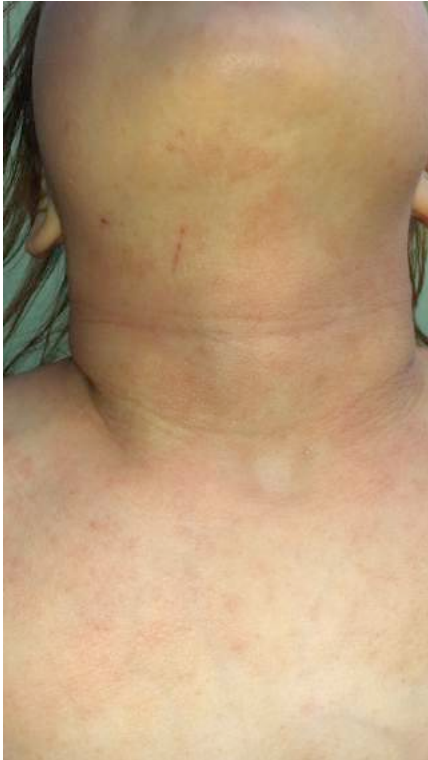Case study 31 (July 2015)

Female, aged 6 when started on Aron Regimen

Prior to commencing Aron Regimen	Age when diagnosed with atopic eczema	2 years
	Under treatment of GP or Dermatologist prior to commencing Aron Regimen	GP
	Most recent treatment prior to commencing Aron Regimen (immunosuppressants: any time; rest: previous year)	Topical steroids: Hydrocortisone, Eumovate, Elocon Oral steroids: No Topical immunosuppressants: Yes, Protopic Oral immunosuppressants: No Antihistamines: Yes
	Any hospital emergency or elective admissions related to atopic eczema since diagnosis? If yes, how many?	No
	Any absences from school due to eczema (other than clinic appointments)?	No
Since commencing Aron Regimen	Date started the Aron Regimen	May 2015
	Current treatment	September 2017: Only needed for rare flares September 2016: 4 apps per week except for flares March 2016: 1 x daily application on body, twice daily on hands July 2015: Alternating once /twice daily Mix of steroid, antibiotic and moisturiser creams
	Any hospital emergency or elective admissions related to atopic eczema since commencing Aron Regimen?	No
	Any absences from school due to eczema (other than clinic appointments or initial week of Aron Regimen)?	No

Case study 31 – female, aged 6 years

Photos before commencing Aron Regimen

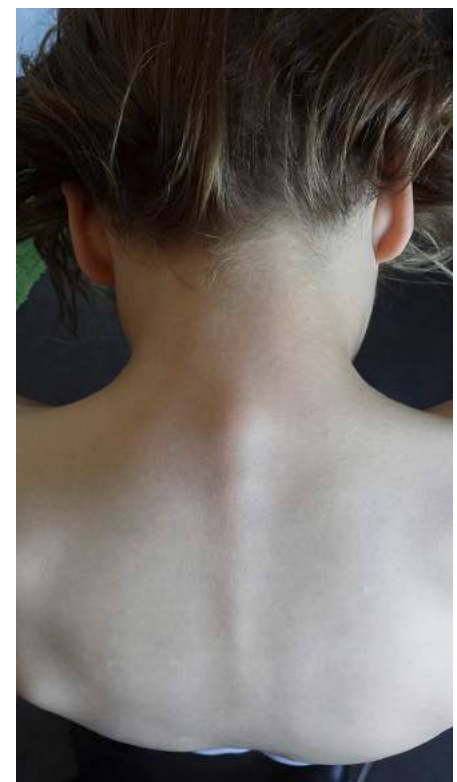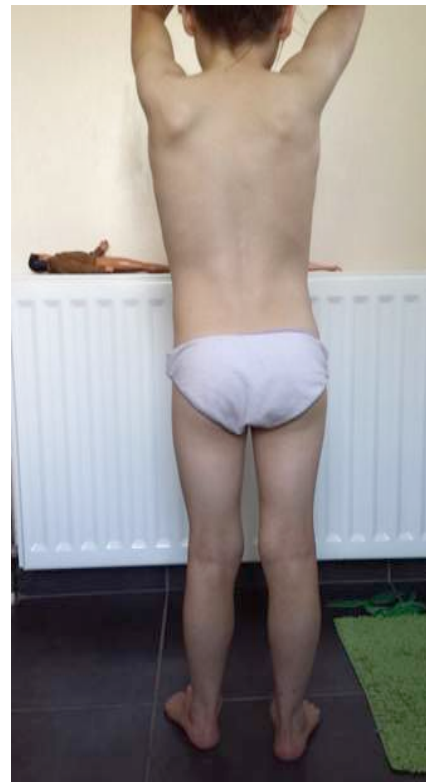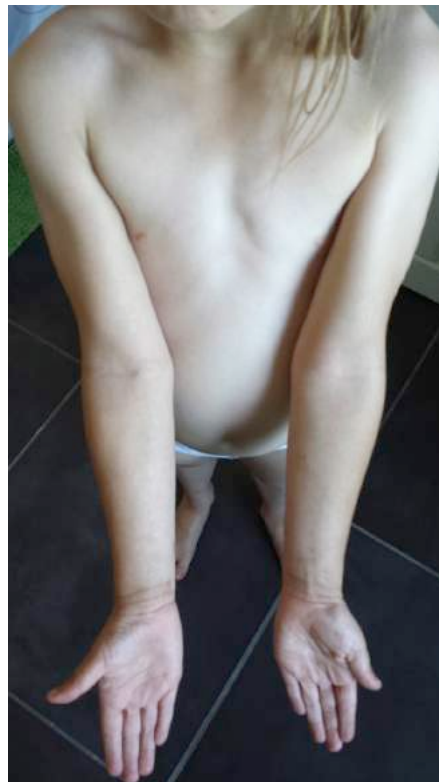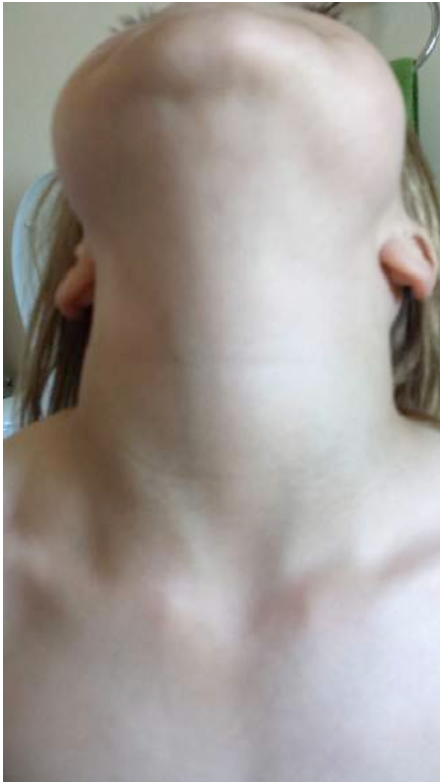


Note from parents:

She was very itchy, scratching all the time with red, inflamed and broken sore skin. Looking pale, tired and uncomfortable and unable to wear dresses, skirts or short sleeves.

Case study 31 – female, aged 6 years

Photos after commencing Aron Regimen



Note from parents:

Itch 95% gone hence skin healing and looking much clearer and healthier. She is much happier in herself and looking better and thrilled she can wear dresses!

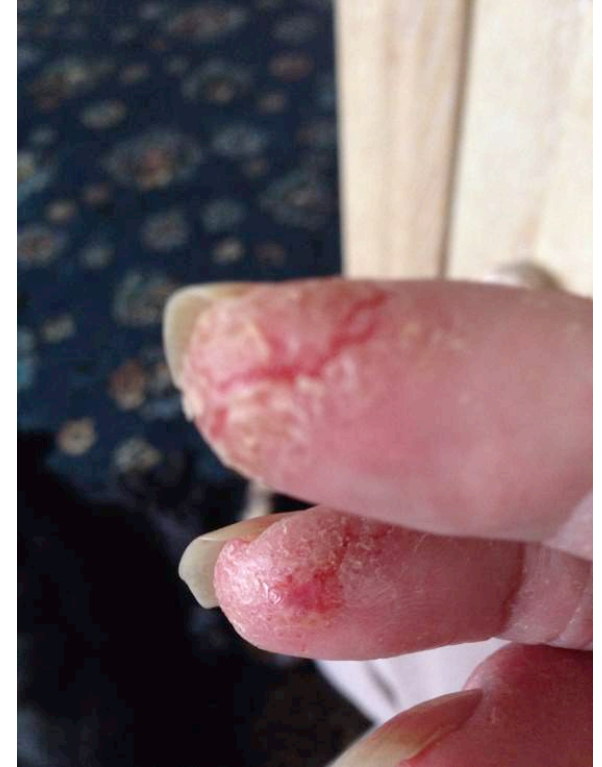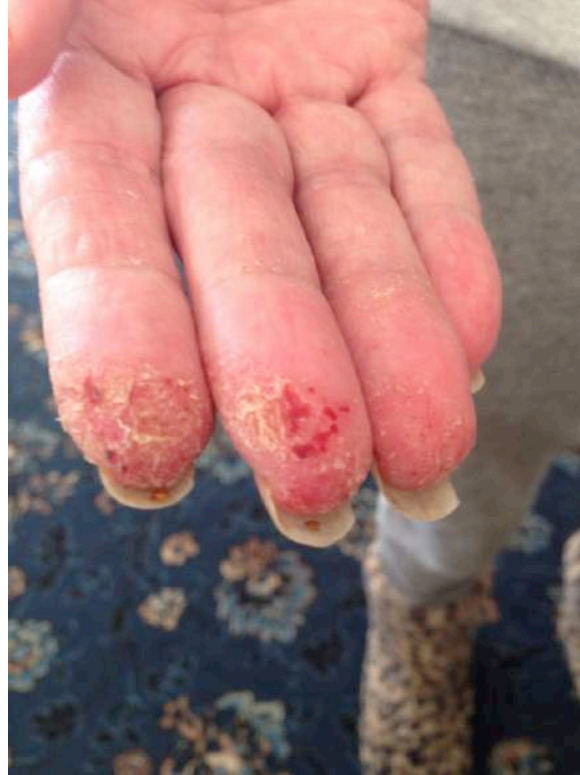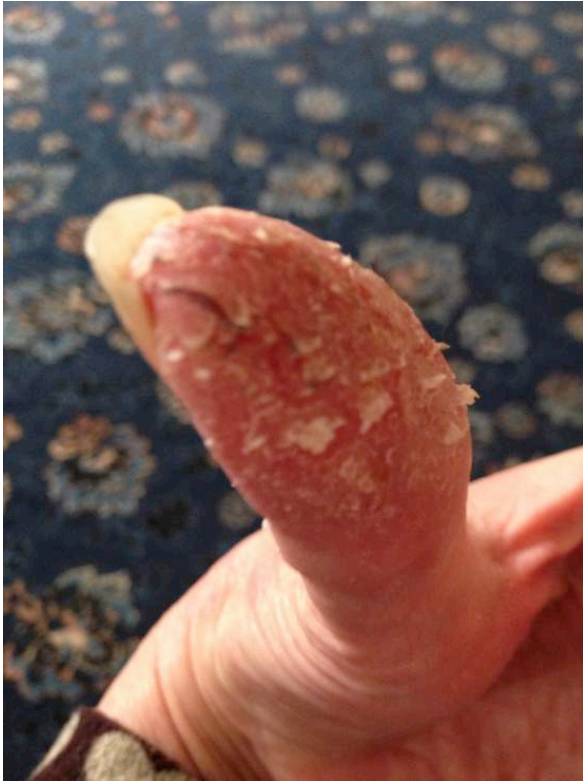Case study 32 (July 2015)

Female, aged 56 when started on Aron Regimen

Prior to commencing Aron Regimen	Age when diagnosed with atopic eczema	45 years
	Under treatment of GP or Dermatologist prior to commencing Aron Regimen	Dermatologist
	Most recent treatment prior to commencing Aron Regimen (immunosuppressants: any time; rest: previous year)	Topical steroids: Yes (most kinds) Oral steroids: No Topical immunosuppressants: No Oral immunosuppressants: No Antihistamines: No
	Any hospital emergency or elective admissions related to atopic eczema since diagnosis? If yes, how many?	No
	Any absences from school due to eczema (other than clinic appointments)?	N/A
Since commencing Aron Regimen	Date started the Aron Regimen	Sept 2014
	Current treatment	September 2017: Still in remission September 2016: Still in remission Use of creams ceased May 2015 – nothing used except emollient Steroid, antibiotic and a moisturiser cream (separate)
	Any hospital emergency or elective admissions related to atopic eczema since commencing Aron Regimen?	No
	Any absences from school due to eczema (other than clinic appointments or initial week of Aron Regimen)?	N/A

Case study 32 – female, aged 56 years

Photos before commencing Aron Regimen

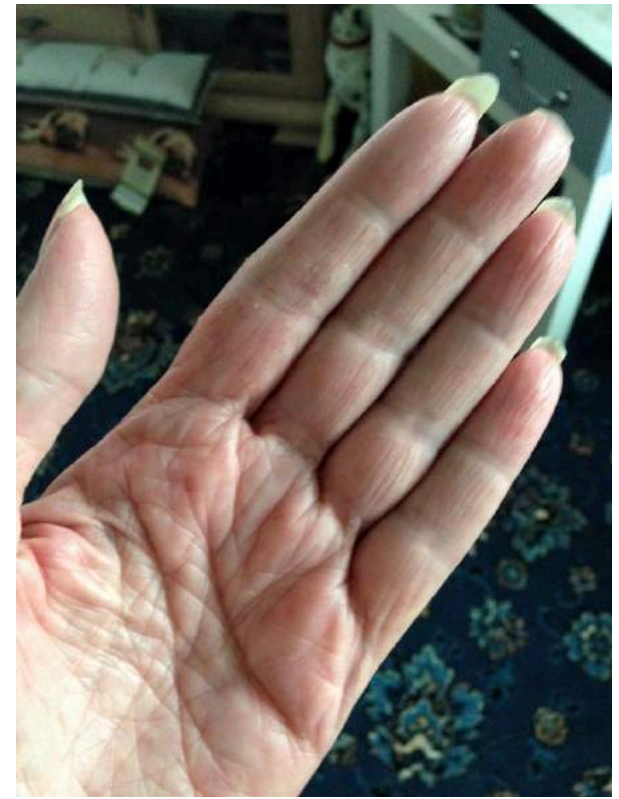
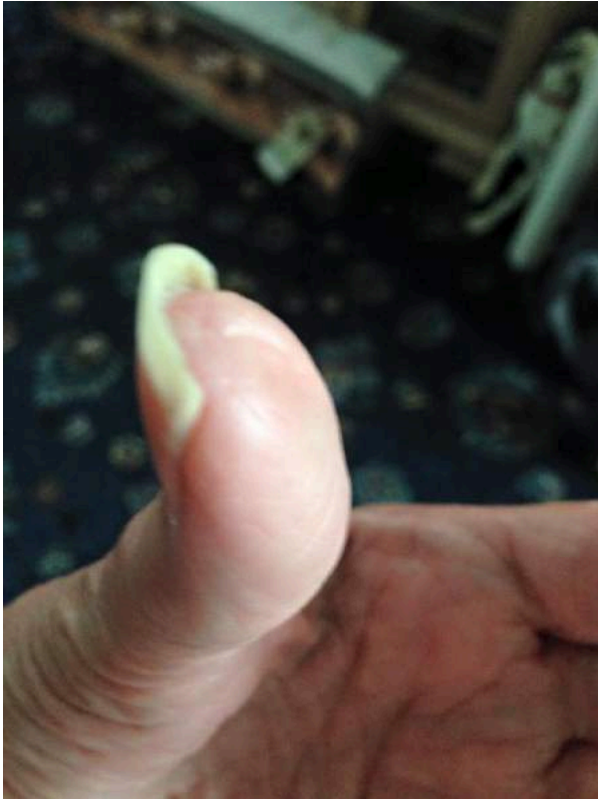

Note from adult:

My hands before treatment were a complete mess, broken infected weeping fissures that made my life difficult ..Some days / weeks even I could not dress bathe or feed myself and lived in bandages and gloves.

Case study 32 – female, aged 56 years

Photos after commencing Aron Regimen



Note from adult:

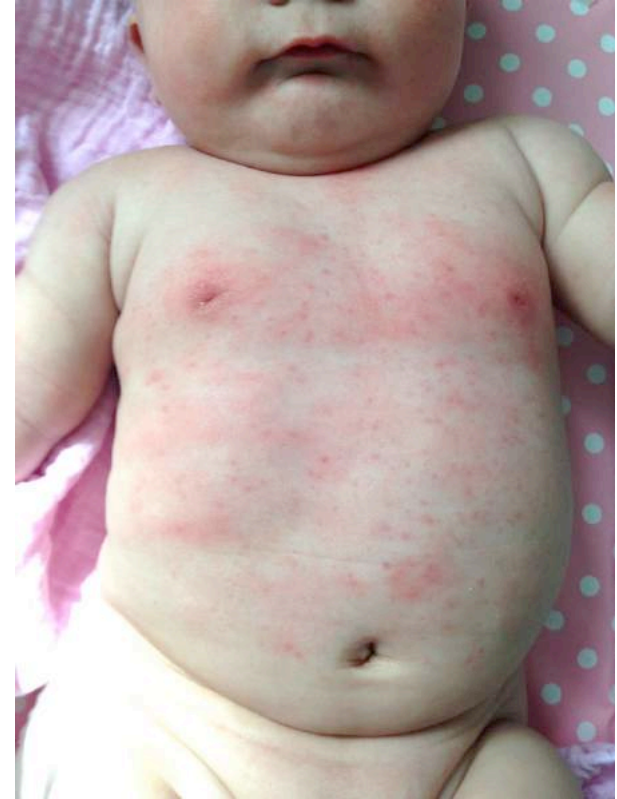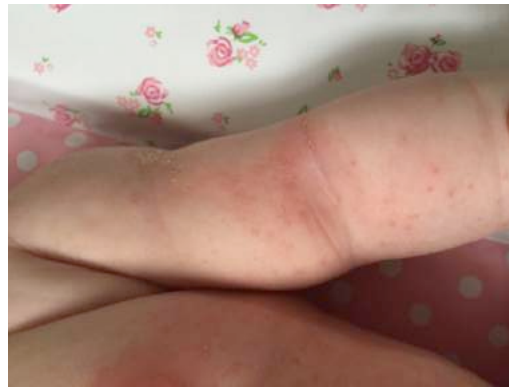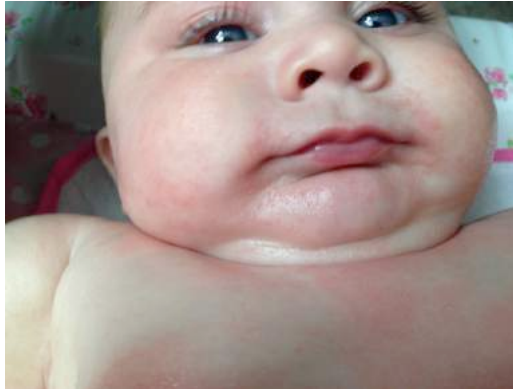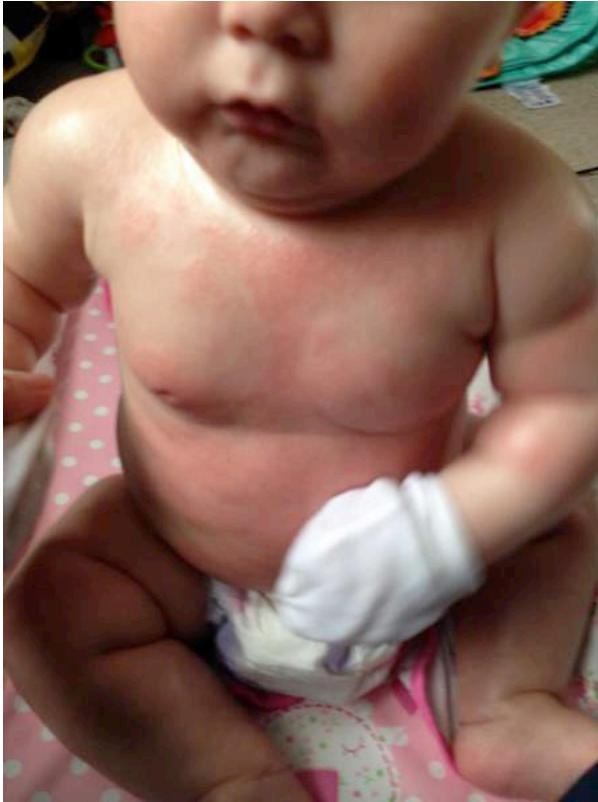Since my treatment with Dr Aron commenced within a few days I found an improvement that increased by the day. I now have my life back. I'm so happy and quite literally a changed person both physically and mentally...Thank you Dr Aron from the bottom of my heart.

Case study 33 (July 2015)

Female, aged 5 months when started on Aron Regimen

Prior to commencing Aron Regimen	Age when diagnosed with atopic eczema	3 months
	Under treatment of GP or Dermatologist prior to commencing Aron Regimen	GP
	Most recent treatment prior to commencing Aron Regimen (immunosuppressants: any time; rest: previous year)	Topical steroids: Hydrocortisone Oral steroids: No Topical immunosuppressants: No Oral immunosuppressants: No Antihistamines: Yes
	Any hospital emergency or elective admissions related to atopic eczema since diagnosis? If yes, how many?	Yes – 1 admission
	Any absences from school due to eczema (other than clinic appointments)?	N/A
Since commencing Aron Regimen	Date started the Aron Regimen	May 2015
	Current treatment	September 2017: Still in remission September 2016: Still in remission. Nothing used except emollient. Use of creams ceased 20th July 2015 – nothing used except emollient Mix of steroid, antibiotic and moisturiser creams
	Any hospital emergency or elective admissions related to atopic eczema since commencing Aron Regimen?	No
	Any absences from school due to eczema (other than clinic appointments or initial week of Aron Regimen)?	N/A

Case study 33 – female, aged 5 months
Photos before commencing Aron Regimen

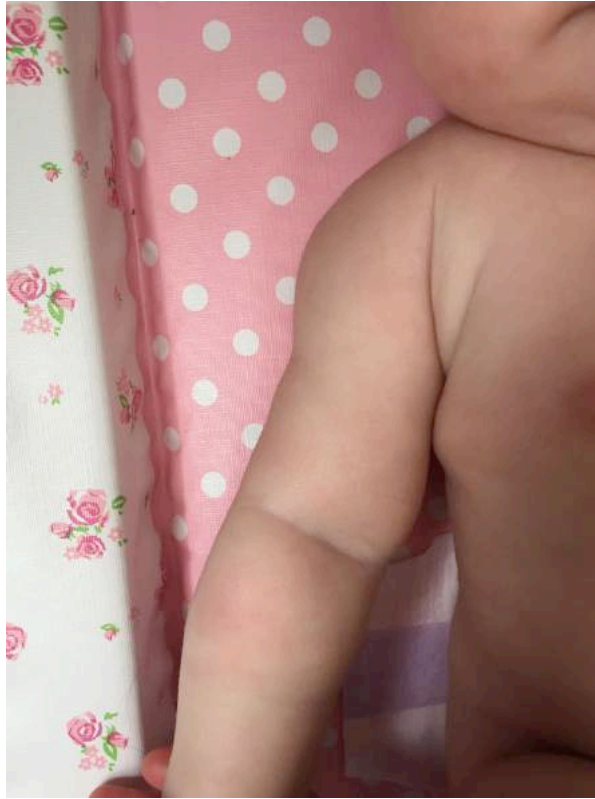
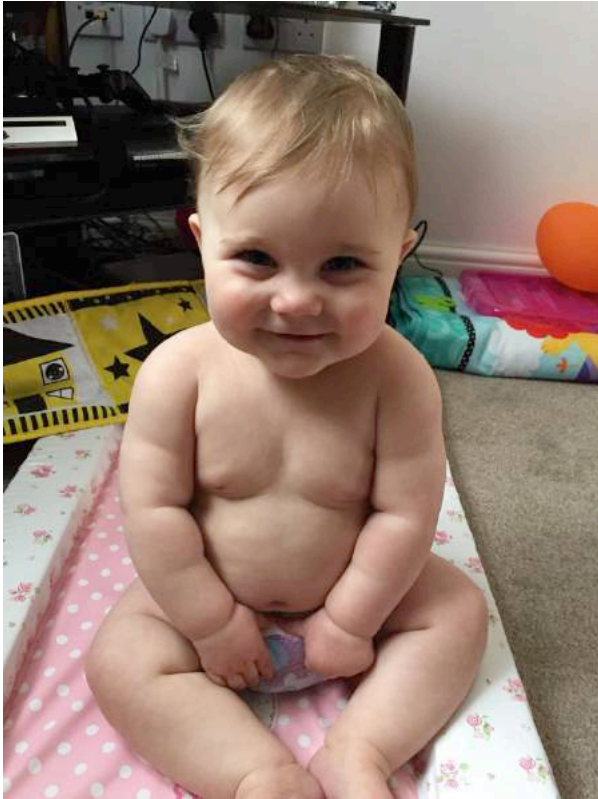
Note from parents:

She was waking up frequently in the night unable to sleep due to scratching, I couldn't change her without putting mits on her hands and holding her arms down as she used to draw blood when she scratched.

Case study 33 – female, aged 5 months

Photos after commencing Aron Regimen



Note from parents:

Her skin cleared almost instantly, within a day she was looking ten times better. The itching went away after a weeks use and now she is eczema free!

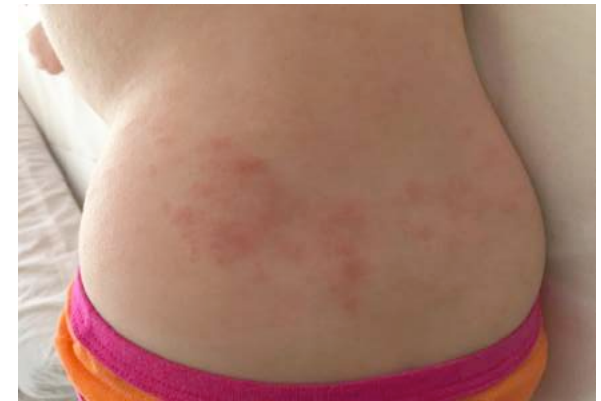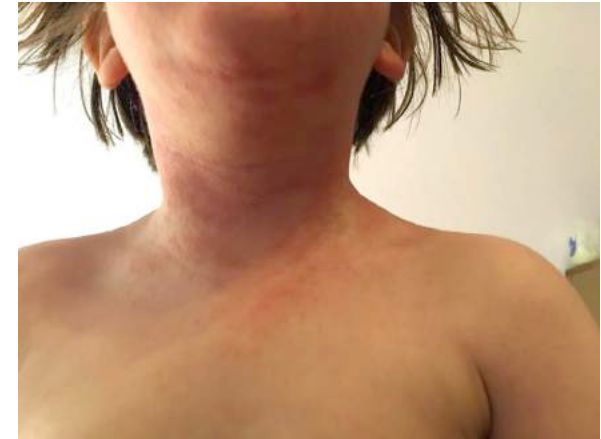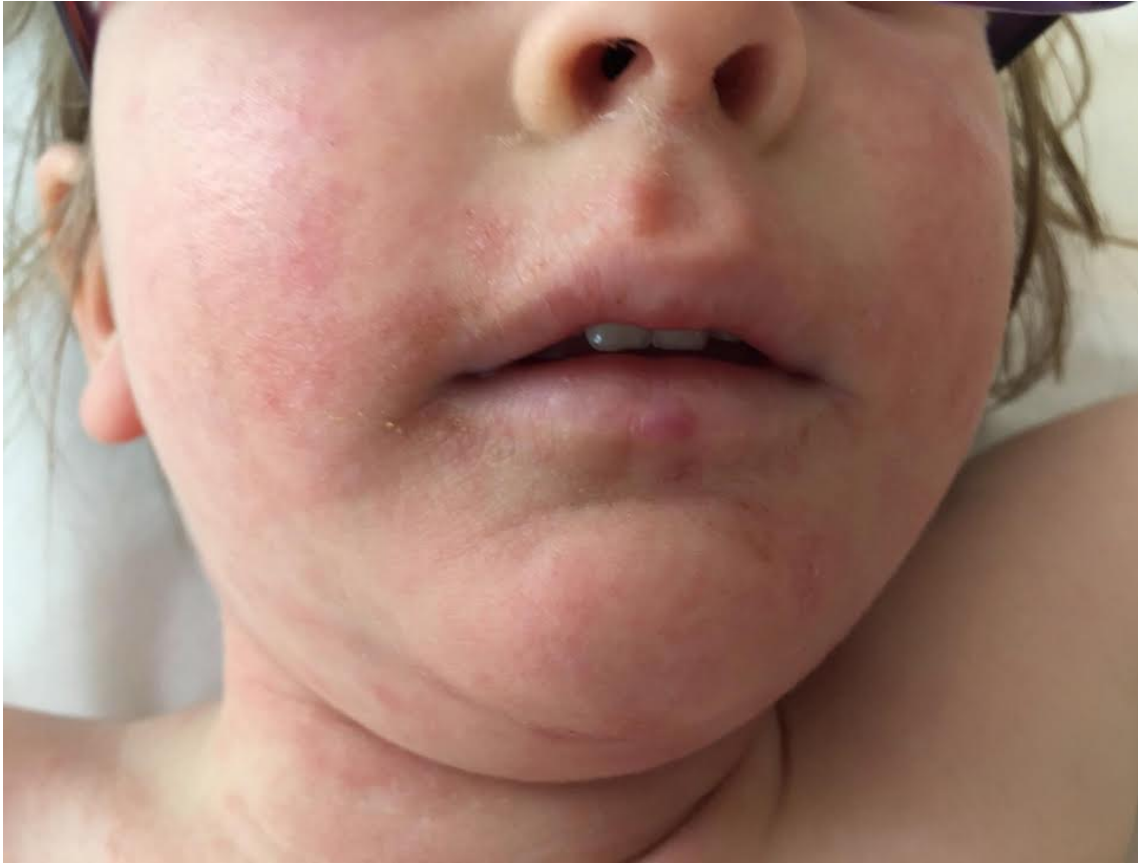Case study 34 (July 2015)

Female, aged 3 years when started on Aron Regimen

Prior to commencing Aron Regimen	Age when diagnosed with atopic eczema	6 weeks
	Under treatment of GP or Dermatologist prior to commencing Aron Regimen	GP
	Most recent treatment prior to commencing Aron Regimen (immunosuppressants: any time; rest: previous year)	Topical steroids: Hydrocortisone 1% Hydrocortisone 2.5 %, Triamcinilone 0.1% ointment Oral steroids: No Topical immunosuppressants: No Oral immunosuppressants: No Antihistamines: Yes
	Any hospital emergency or elective admissions related to atopic eczema since diagnosis? If yes, how many?	No
	Any absences from school due to eczema (other than clinic appointments)?	N/A
Since commencing Aron Regimen	Date started the Aron Regimen	Feb 2015
	Current treatment	September 2017: Every 3rd day on fingers, wrists, bottom, ankles, and knees September 2016: 1x daily on bottom, every 2nd-4th day on knees and one ankle. Use on flares as needed. Usually very mild and only on a finger or two or a few spots on her legs. February 2016: 1-2 x daily on one ankle and bottom. Every 2 nd day on knees and wrists only. Use on flares when needed. July 2015: 1 x daily all over. 2 x daily– one finger, knees, ankles Mix of steroid, antibiotic and moisturiser creams
	Any hospital emergency or elective admissions related to atopic eczema since commencing Aron Regimen?	No
	Any absences from school due to eczema (other than clinic appointments or initial week of Aron Regimen)?	N/A

Case study 34 – female, aged 3 years

Photos before commencing Aron Regimen

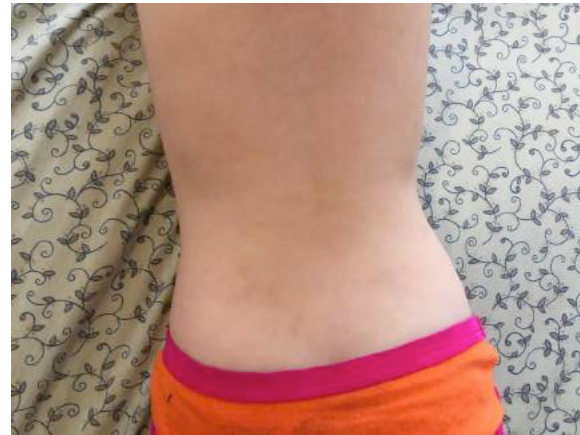
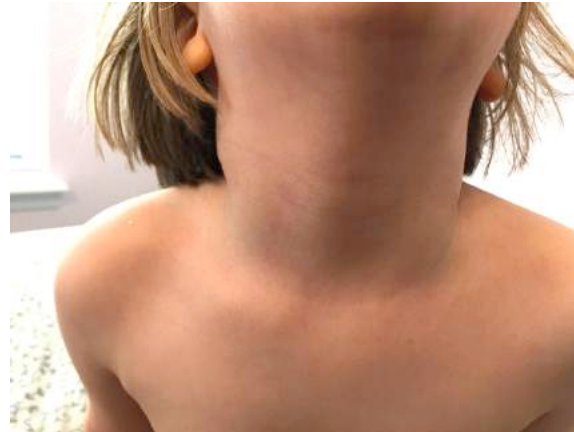
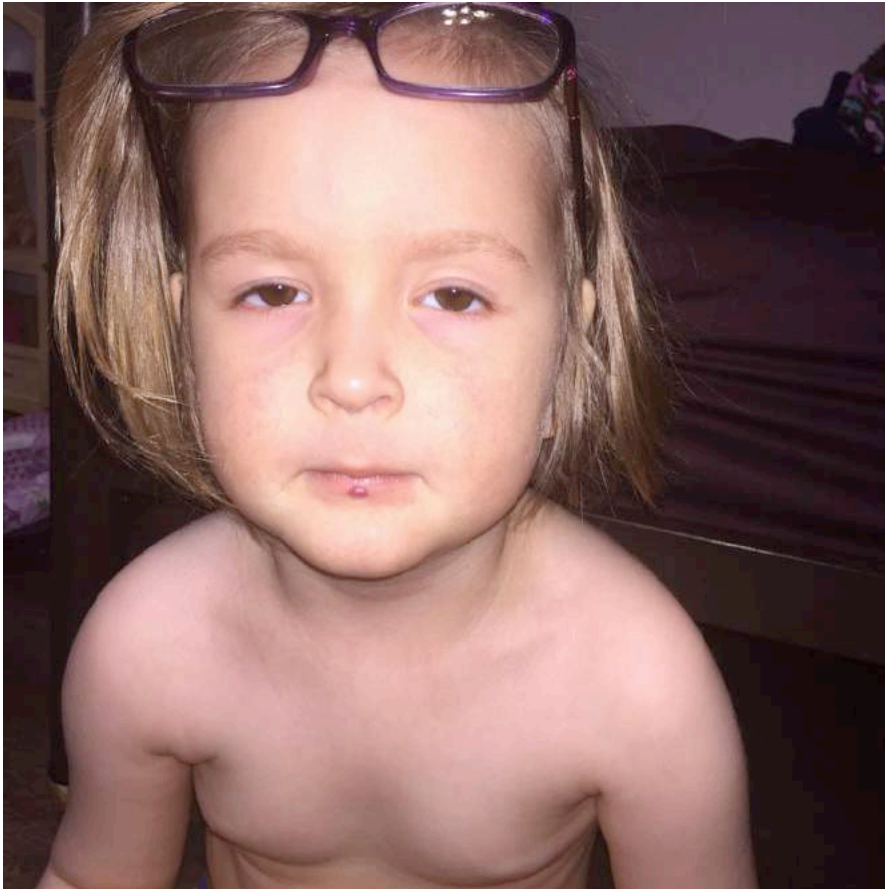Note from parents:

Even the best days were a constant succession of baths, wet wraps, lotions, deciding which steroid was needed where and how often, wondering what had triggered the latest flare, and watching my daughter itch. Sometimes I thought of leaving and not coming back.

Case study 34 – female, aged 3 years

Photos after commencing Aron Regimen



Note from parents:

She sleeps through the night, rarely scratches, flares that do happen are minimal and easily controlled. My mind isn't constantly trying to figure out triggers and come up with better tapering methods.

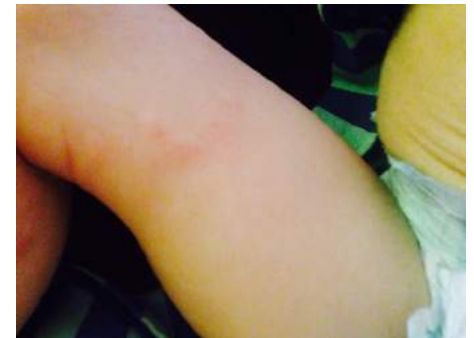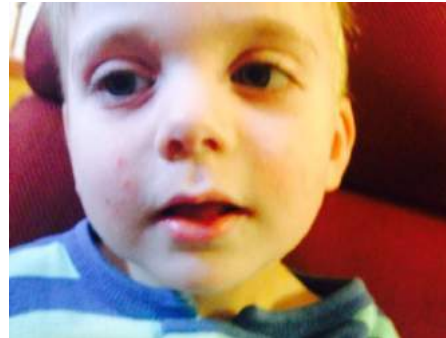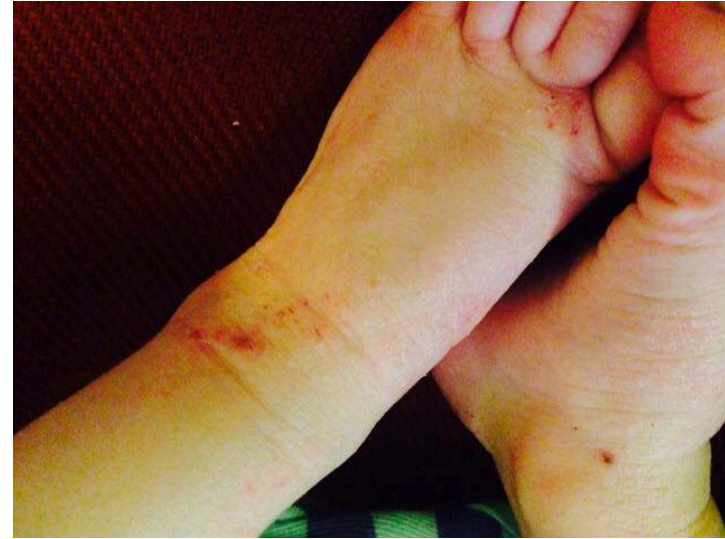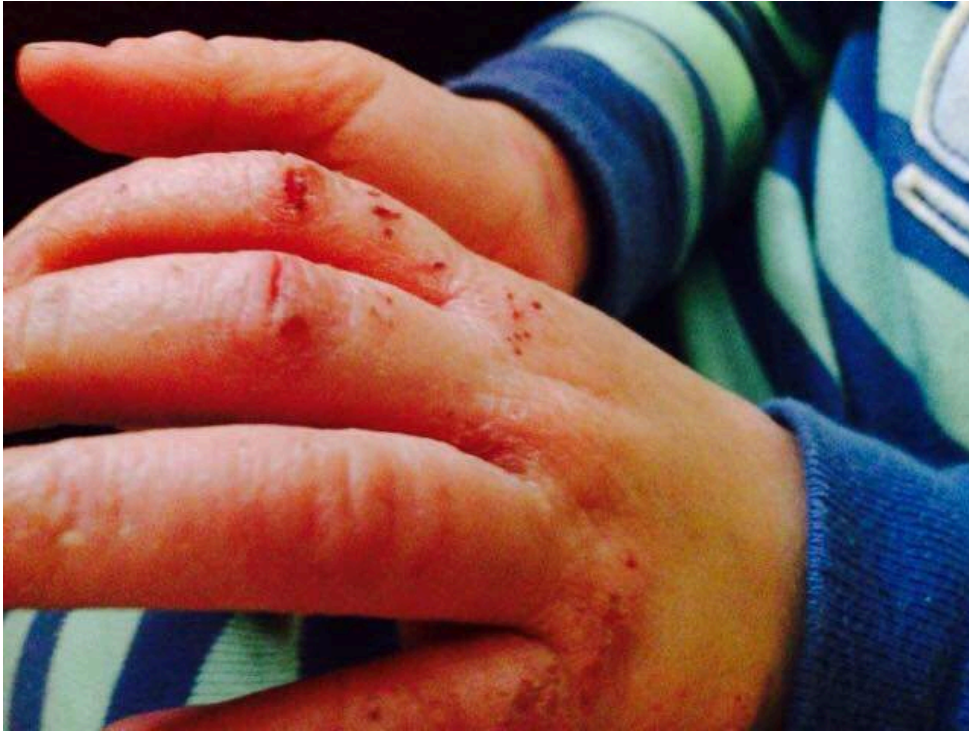Case study 35 (July 2015)

Male, aged 2 years when started on Aron Regimen

Prior to commencing Aron Regimen	Age when diagnosed with atopic eczema	12 weeks
	Under treatment of GP or Dermatologist prior to commencing Aron Regimen	GP
	Most recent treatment prior to commencing Aron Regimen (immunosuppressants: any time; rest: previous year)	Topical steroids: Hydrocortisone 1% Oral steroids: Yes Topical immunosuppressants: No Oral immunosuppressants: No Antihistamines: Yes
	Any hospital emergency or elective admissions related to atopic eczema since diagnosis? If yes, how many?	No
	Any absences from school due to eczema (other than clinic appointments)?	N/A
Since commencing Aron Regimen	Date started the Aron Regimen	May 2015
	Current treatment	September 2016: as below, applications of mix ceased, only used if flaring November 2015: applications of mix ceased, only used if flaring. July 2015: 3 x weekly Mix of steroid, antibiotic and moisturiser creams
	Any hospital emergency or elective admissions related to atopic eczema since commencing Aron Regimen?	No
	Any absences from school due to eczema (other than clinic appointments or initial week of Aron Regimen)?	N/A

Case study 35 – male, aged 2 years

Photos before commencing Aron Regimen



Note from parents:

Did not sleep more than 15 mins before Dr Aron
No shorts, sandals or short sleeves due to itching and scratching

Case study 35 – male, aged 2 years
Photos after commencing Aron Regimen



Note from parents:

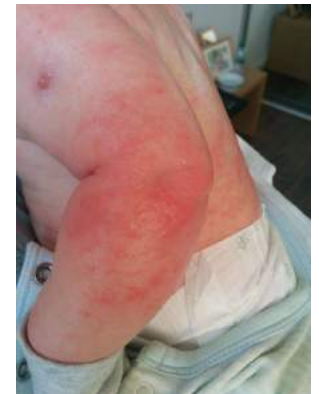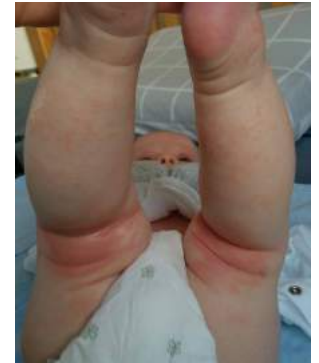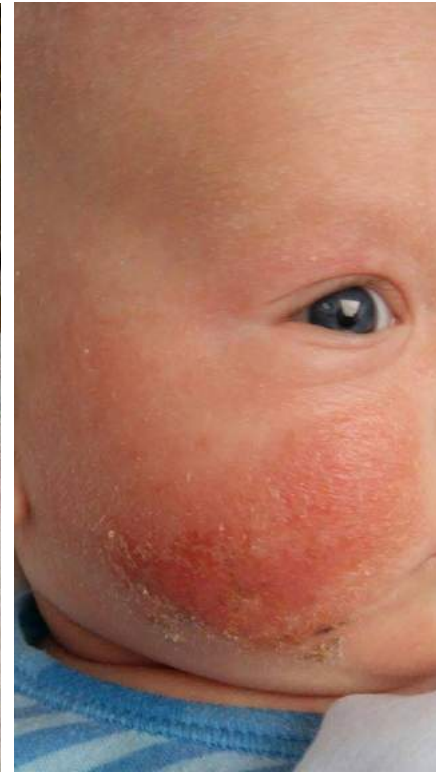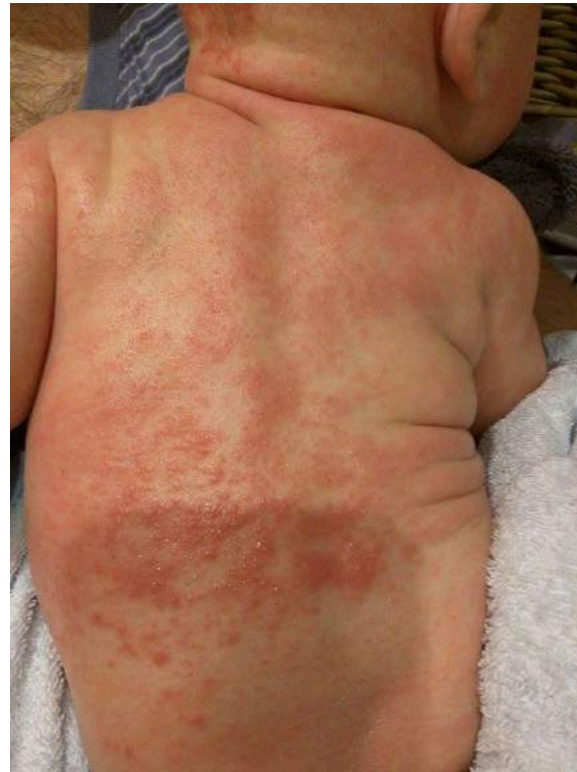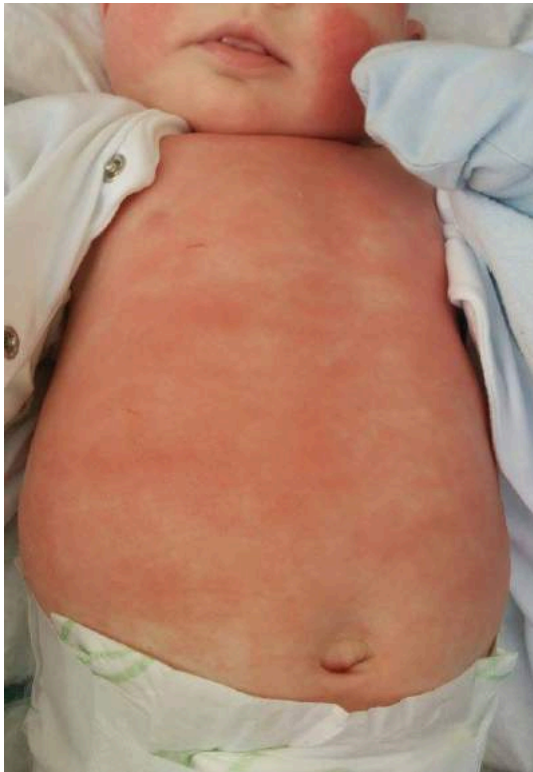Sleeps through the night. Very limited scratching, wears shorts and sandals and very happy.

Case study 36 (August 2015)

Male, aged 4 months when started on Aron Regimen

Prior to commencing Aron Regimen	Age when diagnosed with atopic eczema	2 months
	Under treatment of GP or Dermatologist prior to commencing Aron Regimen	Dermatologist
	Most recent treatment prior to commencing Aron Regimen (immunosuppressants: any time; rest: previous year)	Topical steroids: Hydrocortisone 0,5 % Hydrocortisone 1 %, Eumovate Oral steroids: No Topical immunosuppressants: No Oral immunosuppressants: No Antihistamines: Yes
	Any hospital emergency or elective admissions related to atopic eczema since diagnosis? If yes, how many?	Yes – 3 times
	Any absences from school due to eczema (other than clinic appointments)?	N/A
Since commencing Aron Regimen	Date started the Aron Regimen	March 2015
	Current treatment	September 2017: Spot treatment probably 1-2 x per month on fingers only. Nothing on the rest of the body. September 2016: As before. 1 x every 10 days approx. Spot treatment and used for flares only. February 2016: 1 x every 10 days approx. Spot treatment and used for flares only. Antibiotic being removed. August 2015: 1 x daily Mix of steroid, antibiotic and moisturiser creams Other treatment: antihistamine
	Any hospital emergency or elective admissions related to atopic eczema since commencing Aron Regimen?	No
	Any absences from school due to eczema (other than clinic appointments or initial week of Aron Regimen)?	N/A

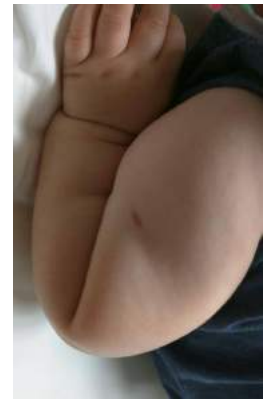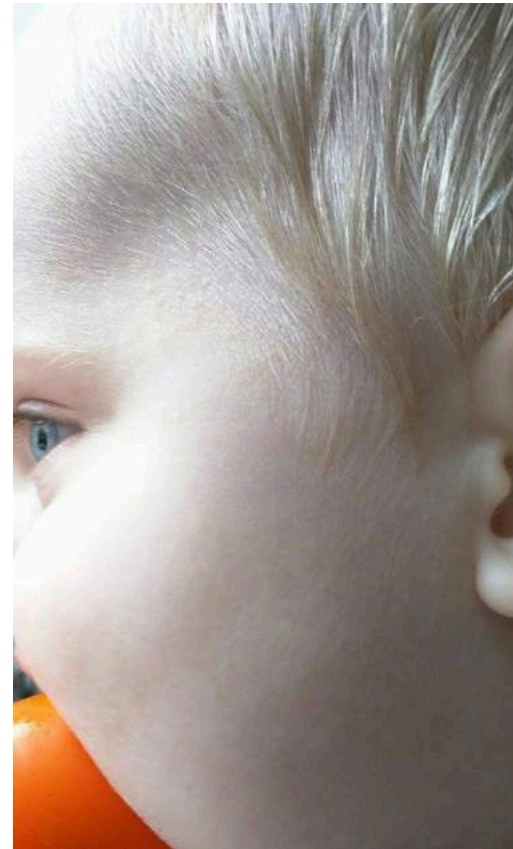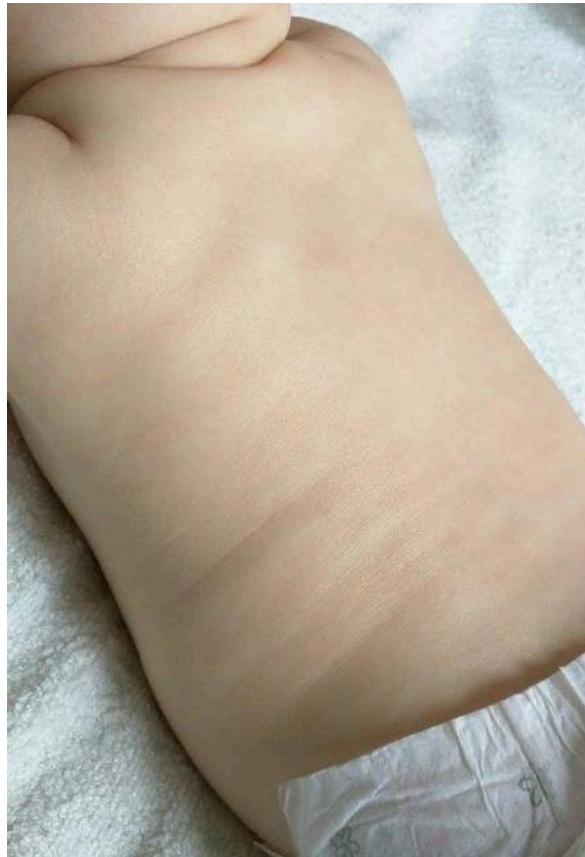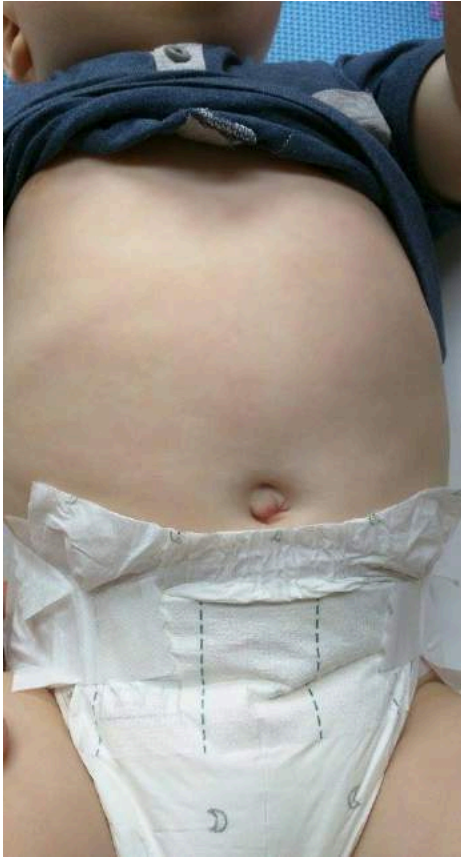Case study 36 – male, aged 4 months
Photos before commencing Aron Regimen



Note from parents:

Lack of sleep, extreme itch - scratching to blood, poor quality of life, failure to thrive, unhappiness of the whole family.

Case study 36 – male, aged 4 months
Photos after commencing Aron Regimen



Note from parents:

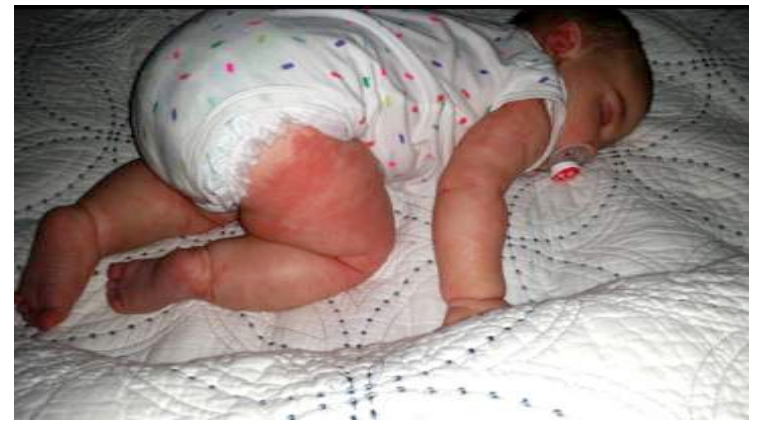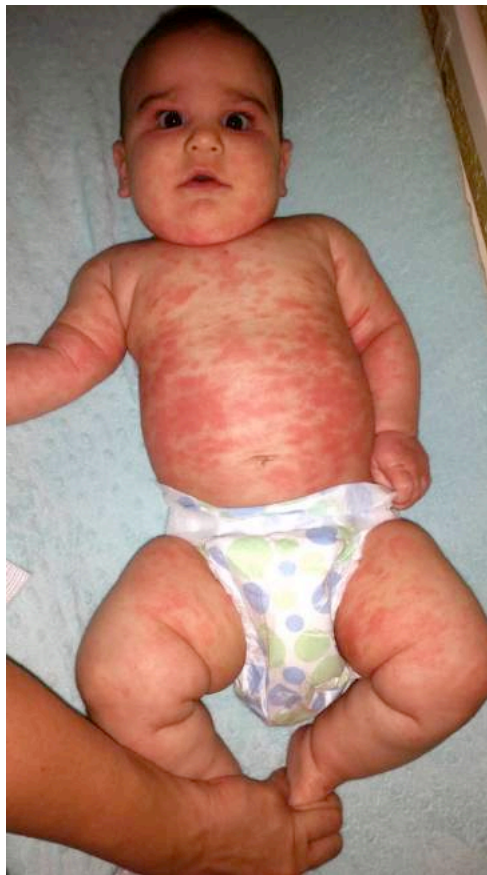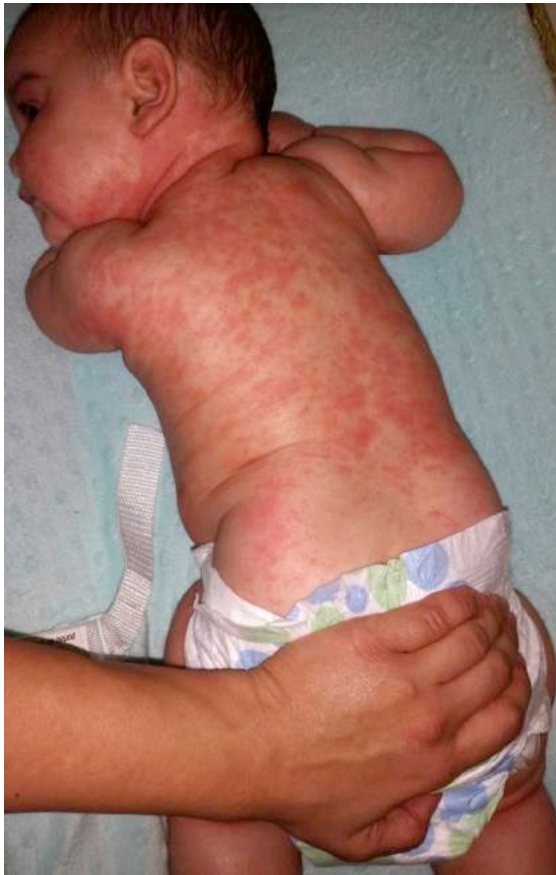Free from itch, normal, happy life, good sleep, no major health problems, success in finding triggers of eczema (cow's milk proteins allergy).

Case study 37 (August 2015)

Female, aged 7 months when started on Aron Regimen

Prior to commencing Aron Regimen	Age when diagnosed with atopic eczema	4 months
	Under treatment of GP or Dermatologist prior to commencing Aron Regimen	GP
	Most recent treatment prior to commencing Aron Regimen (immunosuppressants: any time; rest: previous year)	Topical steroids: Hydrocortisone 1 % Oral steroids: Yes Topical immunosuppressants: No Oral immunosuppressants: No Antihistamines: Yes
	Any hospital emergency or elective admissions related to atopic eczema since diagnosis? If yes, how many?	No
	Any absences from school due to eczema (other than clinic appointments)?	N/A
Since commencing Aron Regimen	Date started the Aron Regimen	May 2015
	Current treatment	September 2017: Not used on most of body for 6 months, small spot on inner thighs treated infrequently September 2016: spot treating, inside of elbows only 3 x per week February 2016: 3 to 4 apps per week August 2015: 1 x daily Mix of steroid, antibiotic and moisturiser creams
	Any hospital emergency or elective admissions related to atopic eczema since commencing Aron Regimen?	No
	Any absences from school due to eczema (other than clinic appointments or initial week of Aron Regimen)?	N/A

Case study 37 – female, aged 7 months
Photos before commencing Aron Regimen

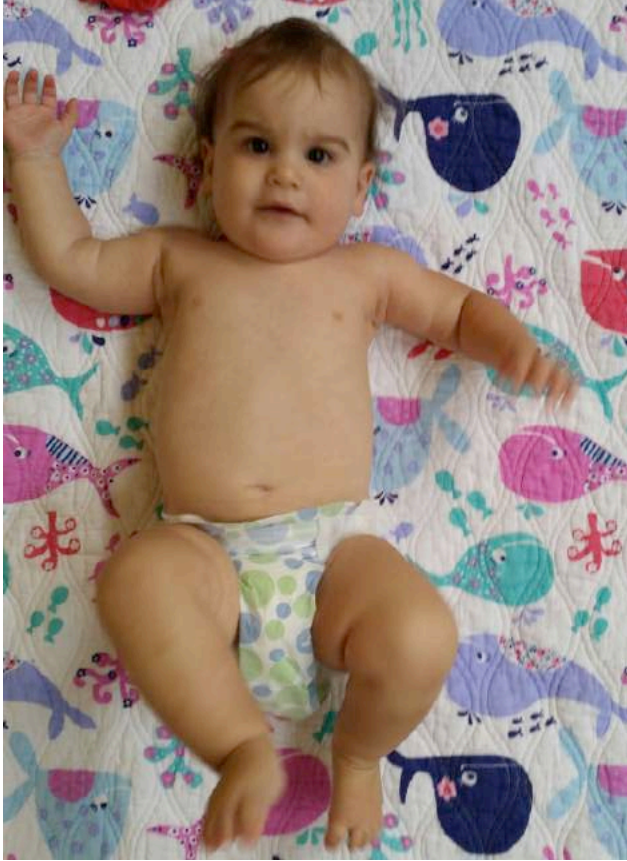

Note from parents:

Lack of sleep, itch, not being her happy self.

Case study 37 – female, aged 7 months

Photos after commencing Aron Regimen



Note from parents:

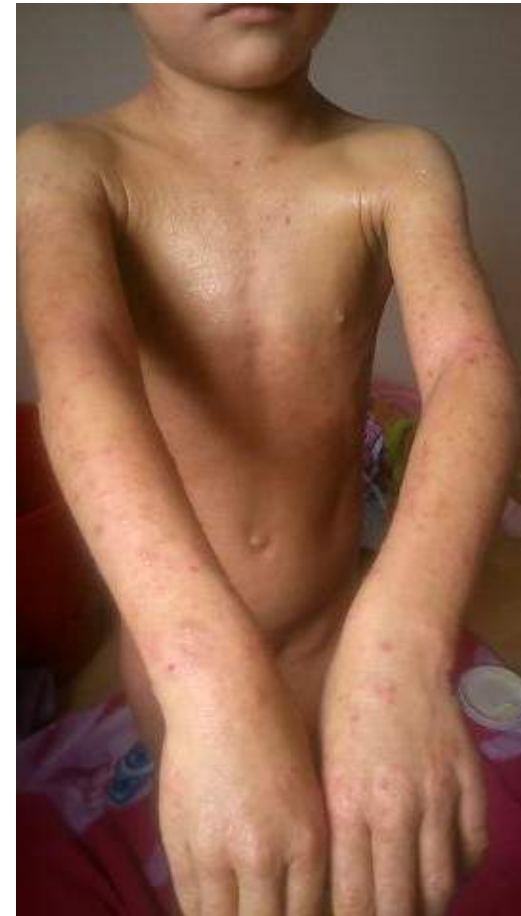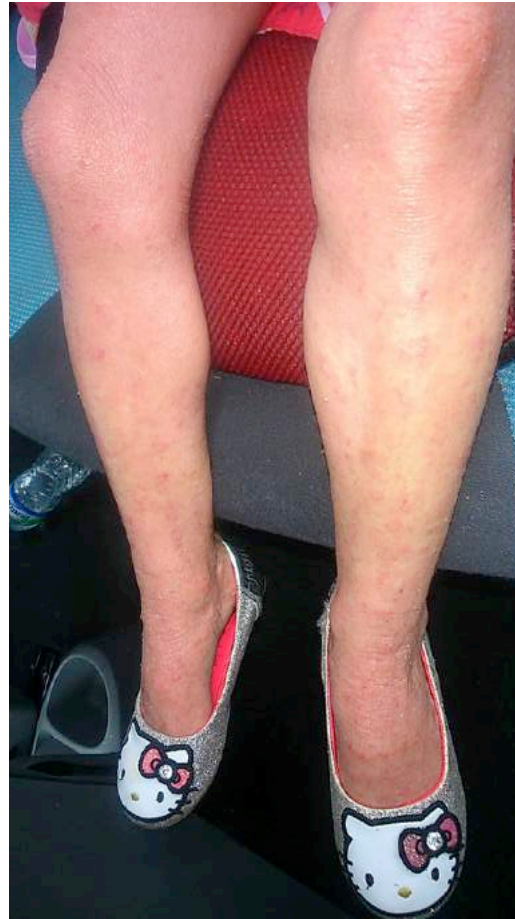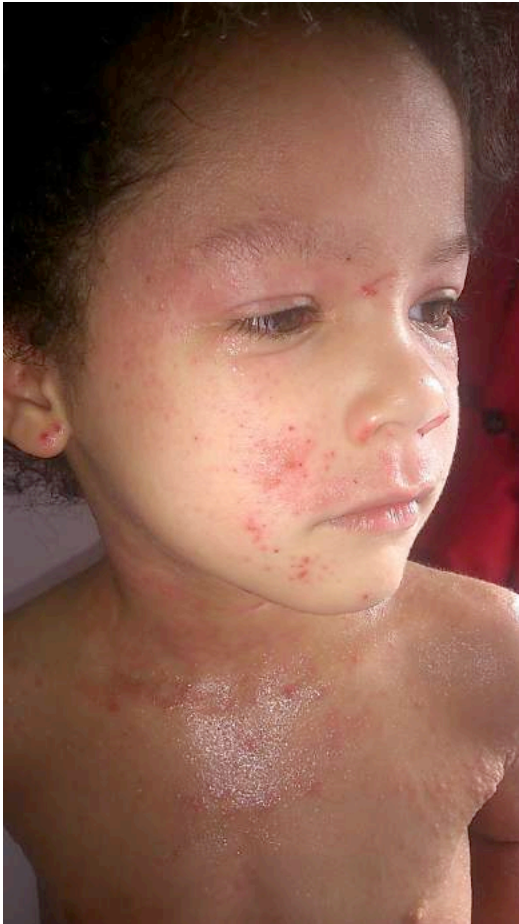She's almost like a normal child. Still has allergies to food but we just avoid those.

Case study 38 (August 2015)

Female, aged 5 years when started on Aron Regimen (twin of Case Study 39)

Prior to commencing Aron Regimen	Age when diagnosed with atopic eczema	5 months
	Under treatment of GP or Dermatologist prior to commencing Aron Regimen	Dermatologist
	Most recent treatment prior to commencing Aron Regimen (immunosuppressants: any time; rest: previous year)	Topical steroids: Eumovate 0.05% cream, Fusidic acid 2% cream, Betnovate Oral steroids: No Topical immunosuppressants: No Oral immunosuppressants: No Antihistamines: Yes
	Any hospital emergency or elective admissions related to atopic eczema since diagnosis? If yes, how many?	Yes – 4 or more admissions
	Any absences from school due to eczema (other than clinic appointments)?	Yes
Since commencing Aron Regimen	Date started the Aron Regimen	Sept 2014
	Current treatment	September 2017: Hardly ever used except rare flares September 2016: Not used except for flares February 2016: 1 – 2 apps per week, eyelids and mouth can sometimes be more August 2015: 2 applications one day, 1 application the next Mix of steroid, antibiotic and moisturiser creams
	Any hospital emergency or elective admissions related to atopic eczema since commencing Aron Regimen?	No
	Any absences from school due to eczema (other than clinic appointments or initial week of Aron Regimen)?	No

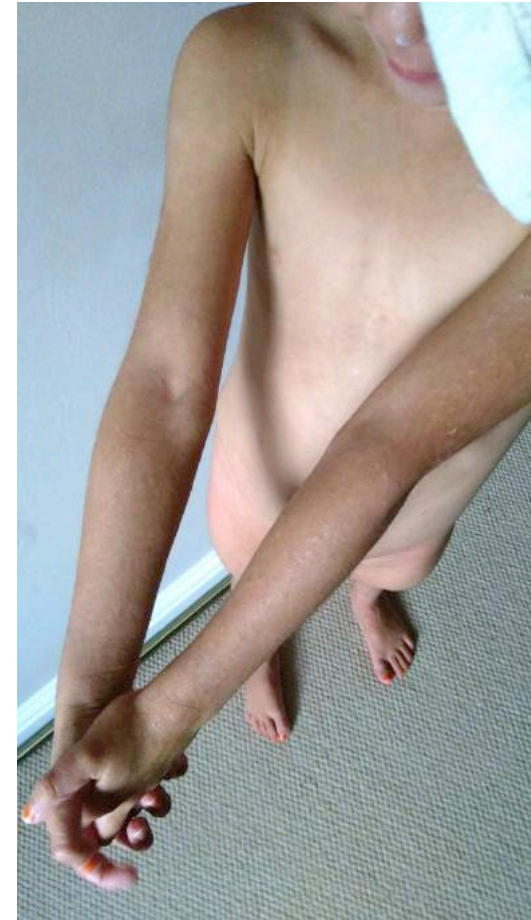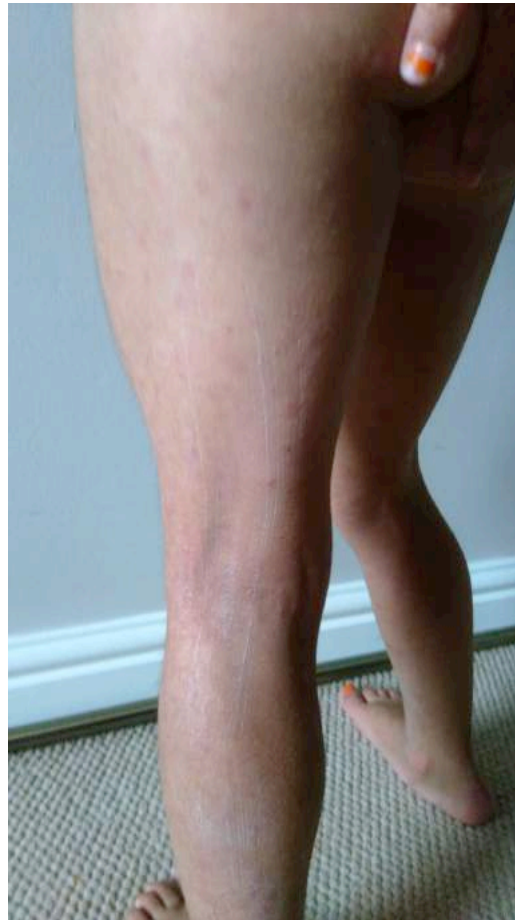Case study 38 – female, aged 5 years
Photos before commencing Aron Regimen



Note from parents:

We had no quality of life at all with broken nights' sleep and a minimum of 2 complete bed sheet changes each night each child. I could not leave my daughters unattended for a second as they would scratch themselves bloody and raw.

Case study 38 – female, 5 years
Photos after commencing Aron Regimen



Note from parents:

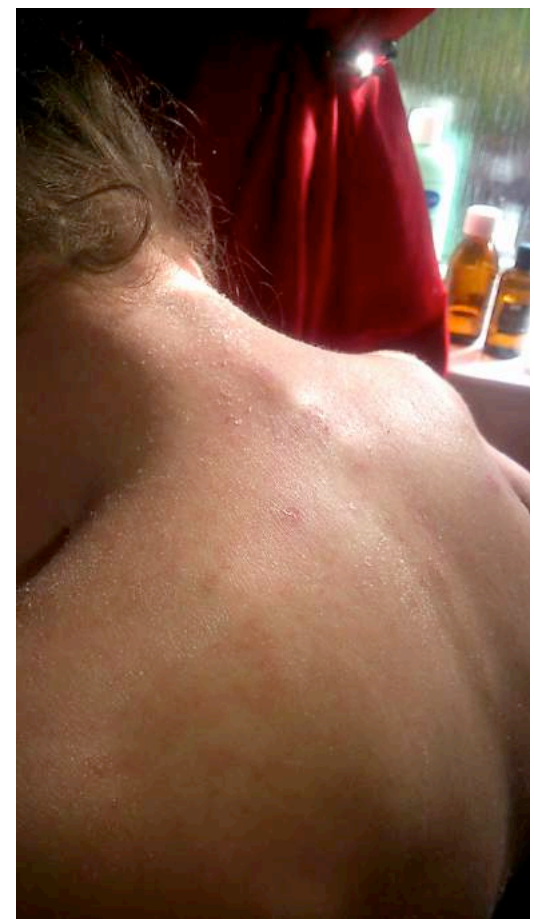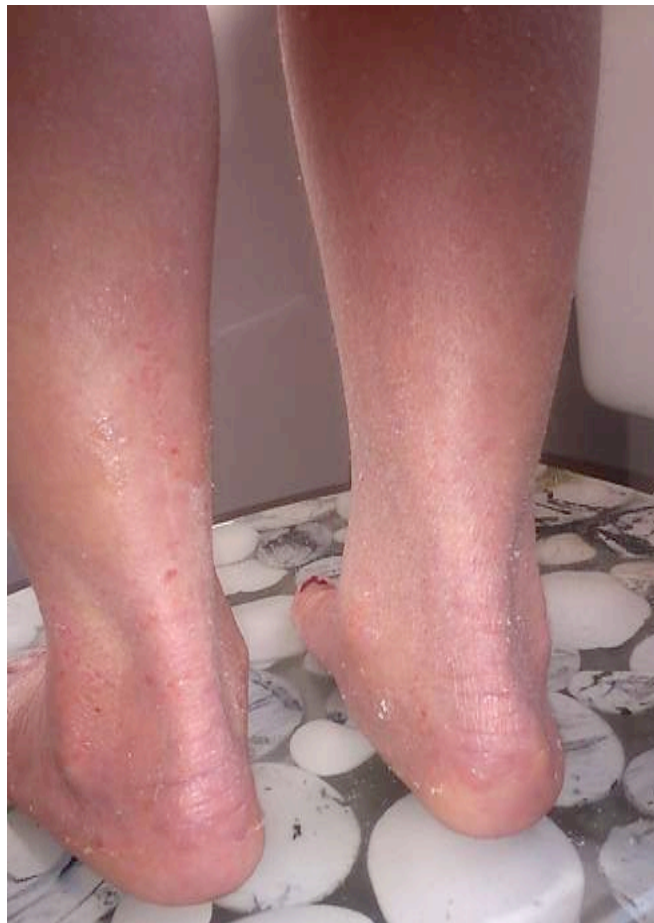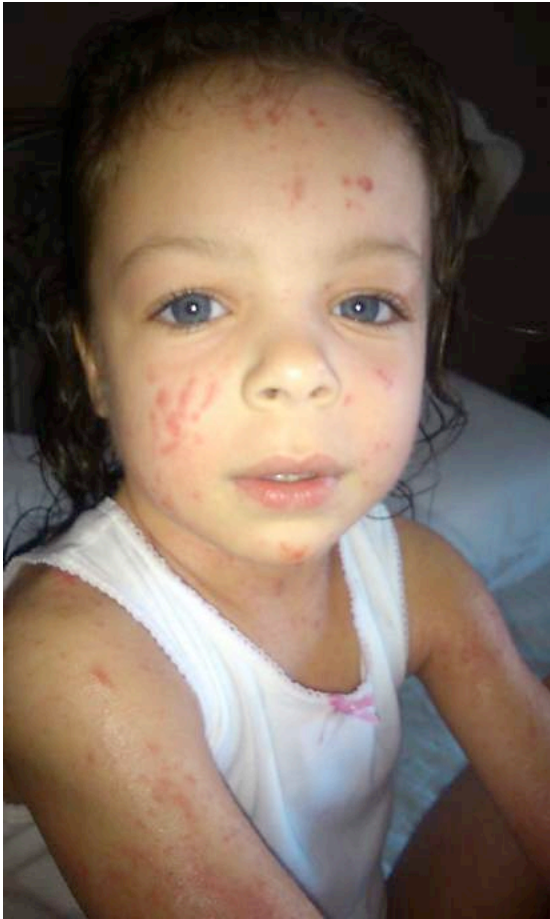My daughters started sleeping through the night on the second night after starting treatment and hardly scratched at all. Even the teachers commented on their dramatic change after just 24 hours.

Case study 39 (August 2015)

Female, aged 5 years when started on Aron Regimen (twin of Case Study 38)

Prior to commencing Aron Regimen	Age when diagnosed with atopic eczema	5 months
	Under treatment of GP or Dermatologist prior to commencing Aron Regimen	Dermatologist
	Most recent treatment prior to commencing Aron Regimen (immunosuppressants: any time; rest: previous year)	Topical steroids: Eumovate 0.05% cream, Fusidic acid 2% cream, Betnovate Oral steroids: No Topical immunosuppressants: No Oral immunosuppressants: No Antihistamines: Yes
	Any hospital emergency or elective admissions related to atopic eczema since diagnosis? If yes, how many?	Yes – 4 or more admissions
	Any absences from school due to eczema (other than clinic appointments)?	Yes
Since commencing Aron Regimen	Date started the Aron Regimen	Sept 2014
	Current treatment	September 2017: Only used for flares mainly only on torso September 2016: 1 application daily on arms, hand and feet February 2016: 1 – 2 apps per week, 1 application per day on hands August 2015: 2 applications one day, 1 application the next Mix of steroid, antibiotic and moisturiser creams
	Any hospital emergency or elective admissions related to atopic eczema since commencing Aron Regimen?	No
	Any absences from school due to eczema (other than clinic appointments or initial week of Aron Regimen)?	No

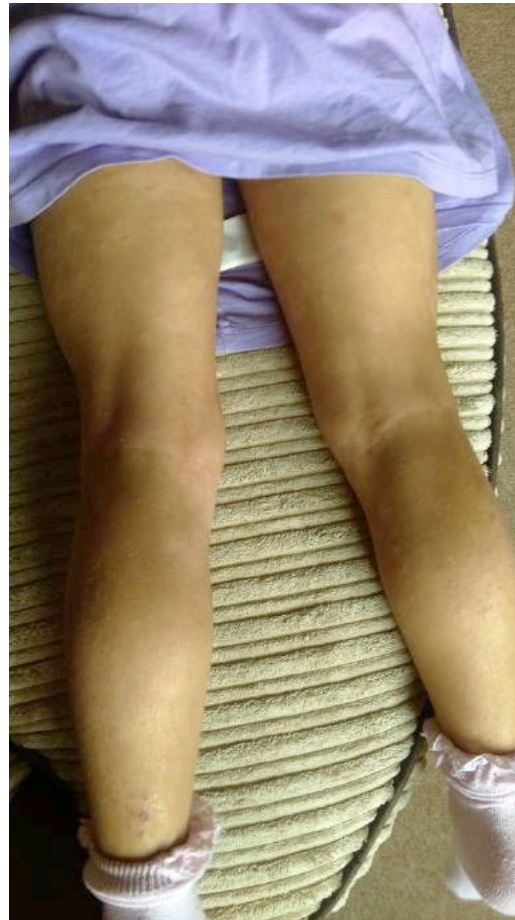Case study 39 – female, aged 5 years
Photos before commencing Aron Regimen



Note from parents:

We had no quality of life at all with broken nights' sleep and a minimum of 2 complete bed sheet changes each night each child. I could not leave my daughters unattended for a second as they would scratch themselves bloody and raw.

Case study 39 – female, 5 years
Photos after commencing Aron Regimen



Note from parents:

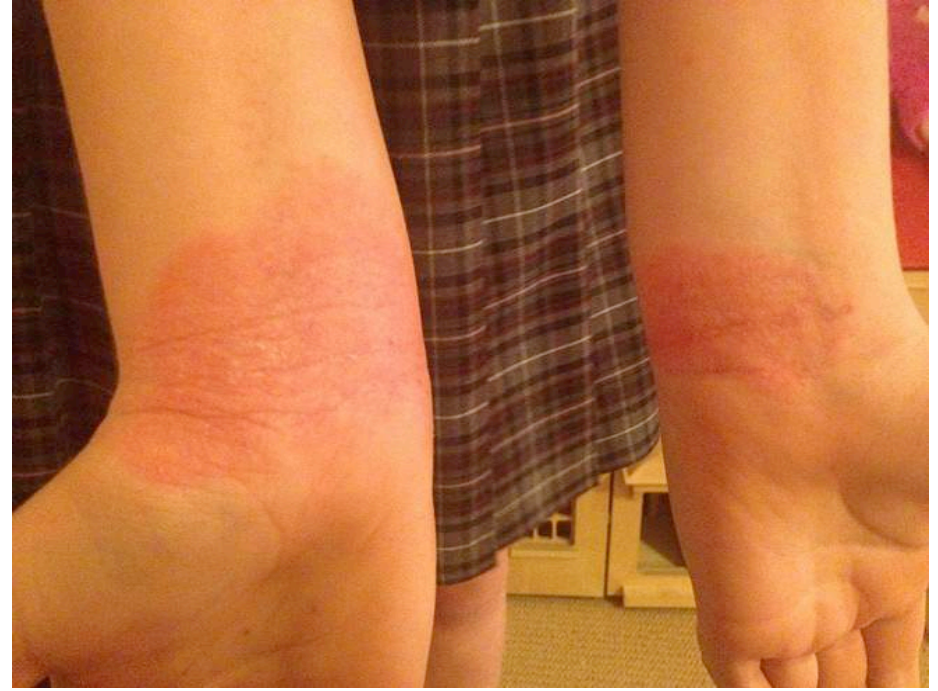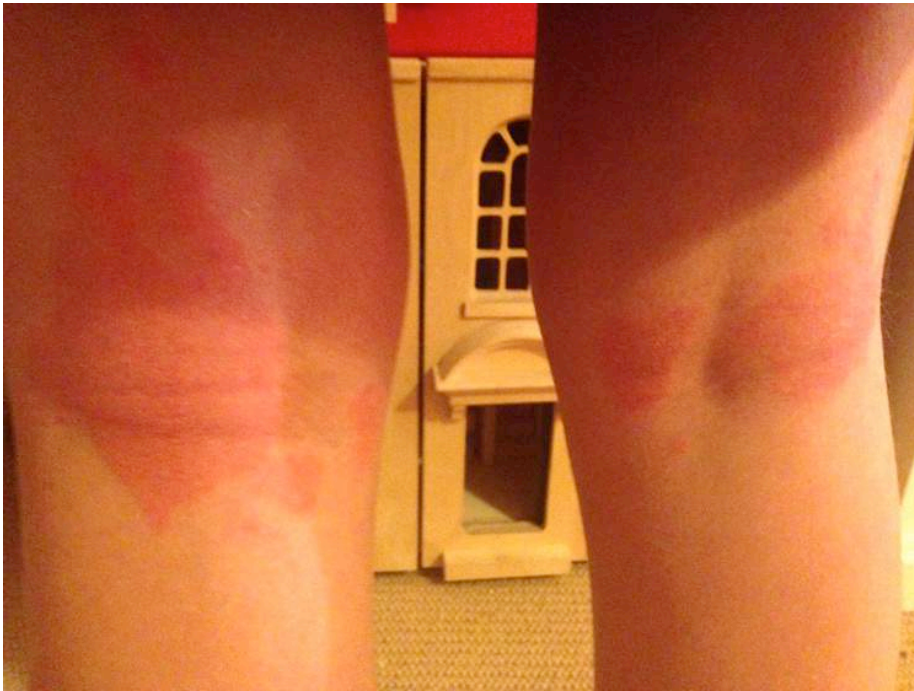My daughters started sleeping through the night on the second night after starting treatment and hardly scratched at all. Even the teachers commented on their dramatic change after just 24 hours.

Case study 40 (August 2015)

Female, aged 12 years when started on Aron Regimen

Prior to commencing Aron Regimen	Age when diagnosed with atopic eczema	2 months old
	Under treatment of GP or Dermatologist prior to commencing Aron Regimen	GP
	Most recent treatment prior to commencing Aron Regimen (immunosuppressants: any time; rest: previous year)	Topical steroids: Hydrocortisone Oral steroids: No Topical immunosuppressants: No Oral immunosuppressants: No Antihistamines: No
	Any hospital emergency or elective admissions related to atopic eczema since diagnosis? If yes, how many?	No
	Any absences from school due to eczema (other than clinic appointments)?	No
Since commencing Aron Regimen	Date started the Aron Regimen	Nov 2014
	Current treatment	September 2017: still maintenance 3 apps per week September 2016: maintenance 3 apps per week March 2016: maintenance 4 apps per week August 2015: 4 applications per week Mix of steroid, antibiotic and moisturiser creams
	Any hospital emergency or elective admissions related to atopic eczema since commencing Aron Regimen?	No
	Any absences from school due to eczema (other than clinic appointments or initial week of Aron Regimen)?	No

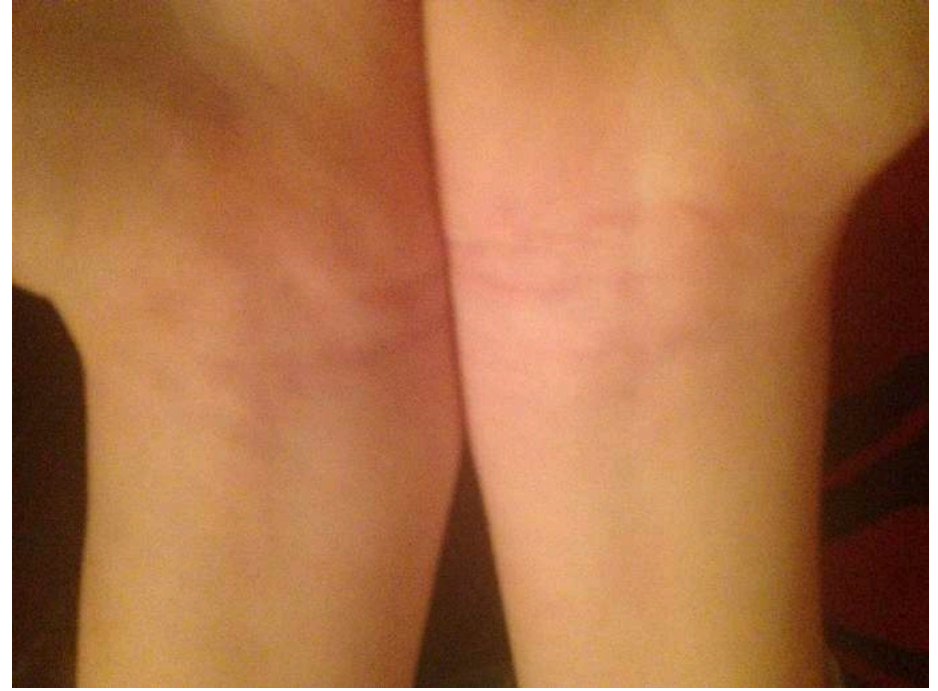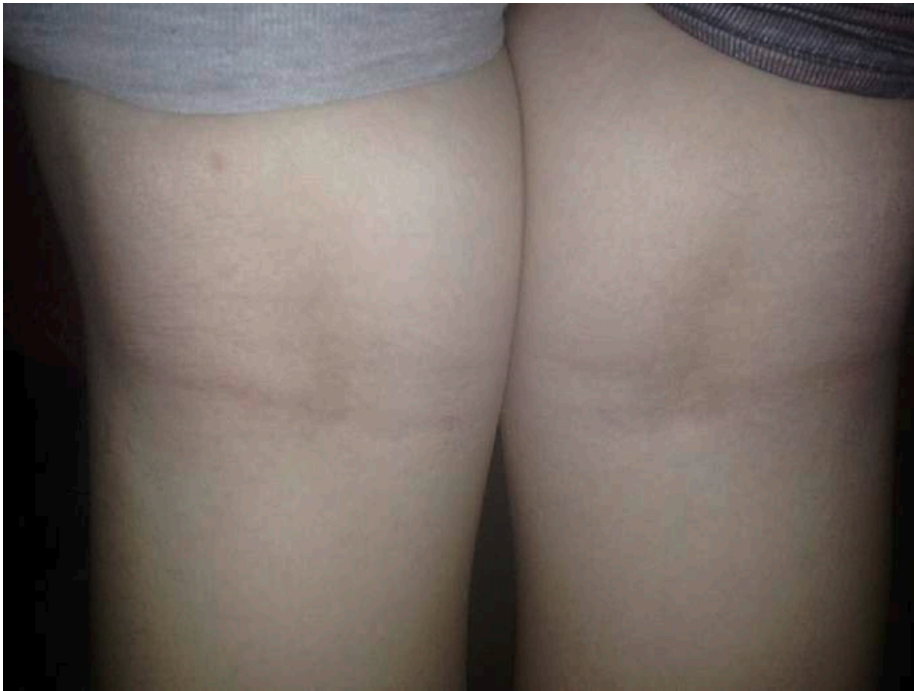Case study 40 – female, aged 12 years
Photos before commencing Aron Regimen



Note from parents:

Very itchy especially at night impacting on sleep. Daughter was self conscious about appearance of eczema affecting self esteem.

Case study 40 – female, 12 years
Photos after commencing Aron Regimen



Note from parents:

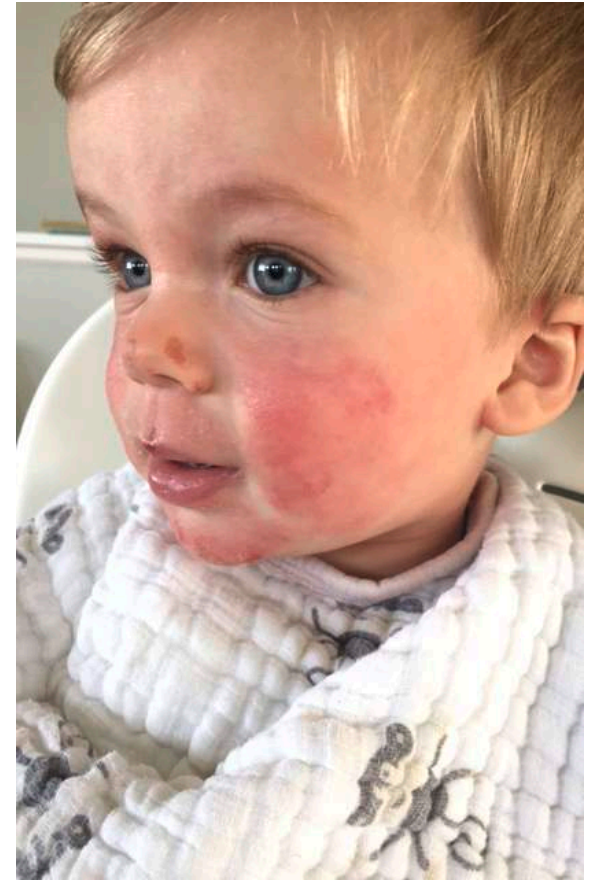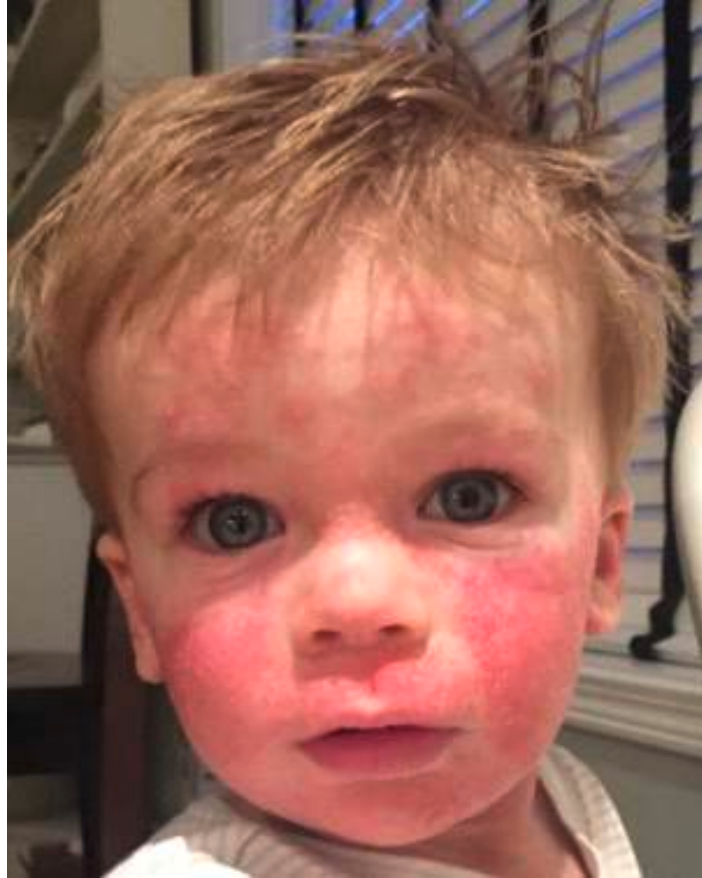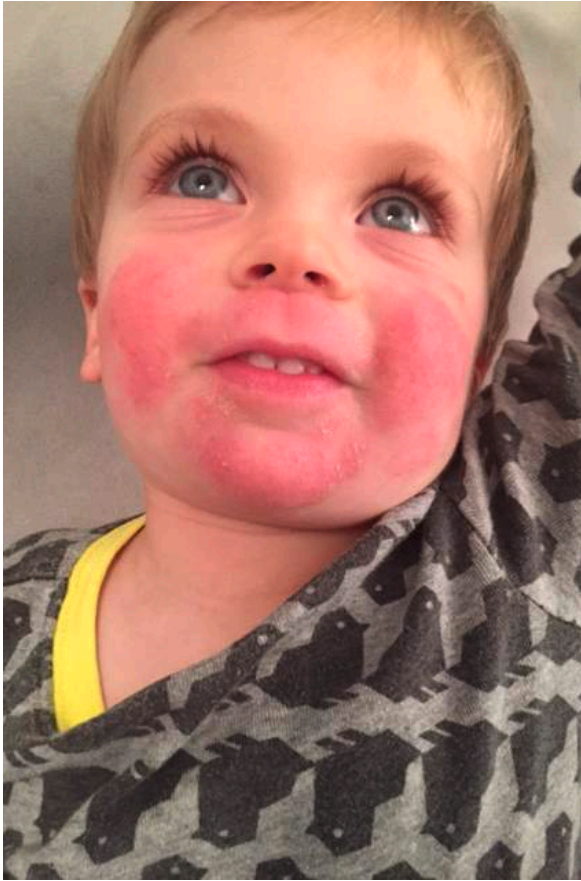Eczema is now clear with no itch meaning much better sleep and improved confidence.

Case study 41 (August 2015)

Male, aged 20 months when started on Aron Regimen

Prior to commencing Aron Regimen	Age when diagnosed with atopic eczema	3 months old
	Under treatment of GP or Dermatologist prior to commencing Aron Regimen	Dermatologist
	Most recent treatment prior to commencing Aron Regimen (immunosuppressants: any time; rest: previous year)	Topical steroids: Desonide .05% ointment & cream Fluorometholone Ophthalmic ointment .1% (eyes), Lotemax Ophthalmic ointment .5% (eyes) 1% hydrocortisone Oral steroids: Yes Topical immunosuppressants: Yes - Protopic Oral immunosuppressants: No Antihistamines: Yes
	Any hospital emergency or elective admissions related to atopic eczema since diagnosis? If yes, how many?	Yes – 1 admission
	Any absences from school due to eczema (other than clinic appointments)?	N/A
Since commencing Aron Regimen	Date started the Aron Regimen	May 2015
	Current treatment	September 2017: only small spots needing treating if required September 2016: spot treating if required February 2016: 2 apps per week for body, 1 x app per day for face August 2015: 1 application per day Mix of steroid, antibiotic and moisturiser creams
	Any hospital emergency or elective admissions related to atopic eczema since commencing Aron Regimen?	No
	Any absences from school due to eczema (other than clinic appointments or initial week of Aron Regimen)?	N/A

Case study 41 – male, aged 20 months
Photos before commencing Aron Regimen

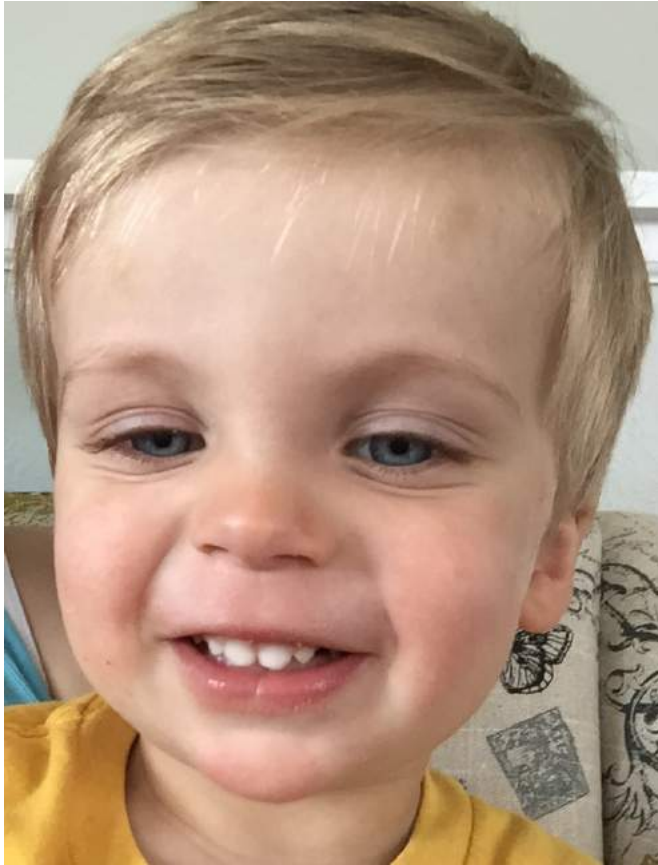


Note from parents:

Constant itching and oozing, bleeding skin. Many missed days of daycare. Poor quality sleep and very distracted by itching.

Case study 41 – male, 20 months

Photos after commencing Aron Regimen



Note from parents:

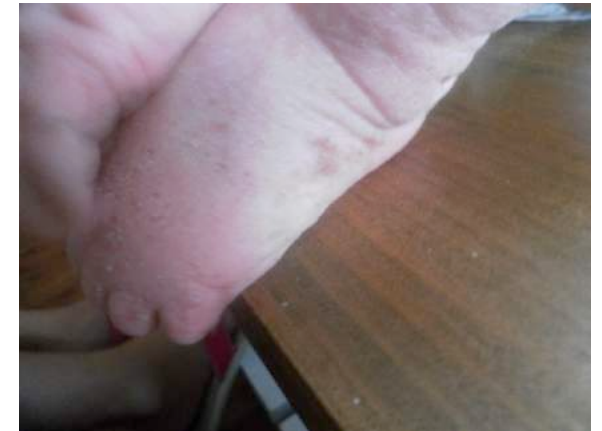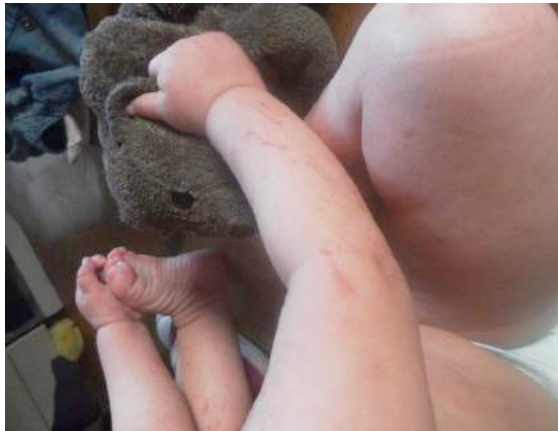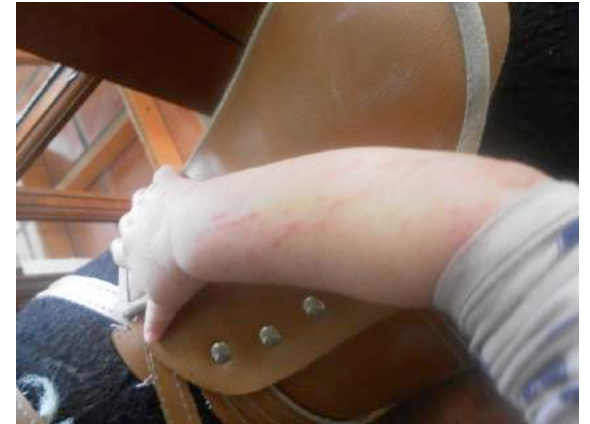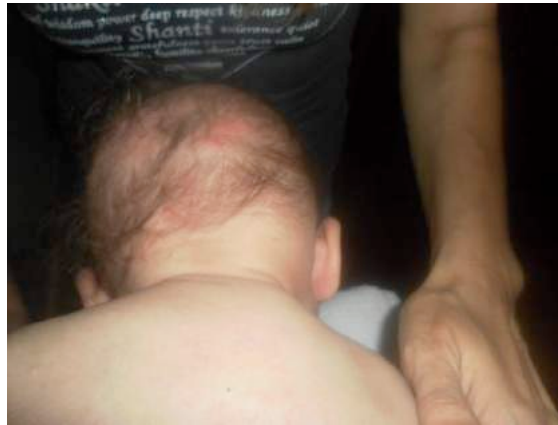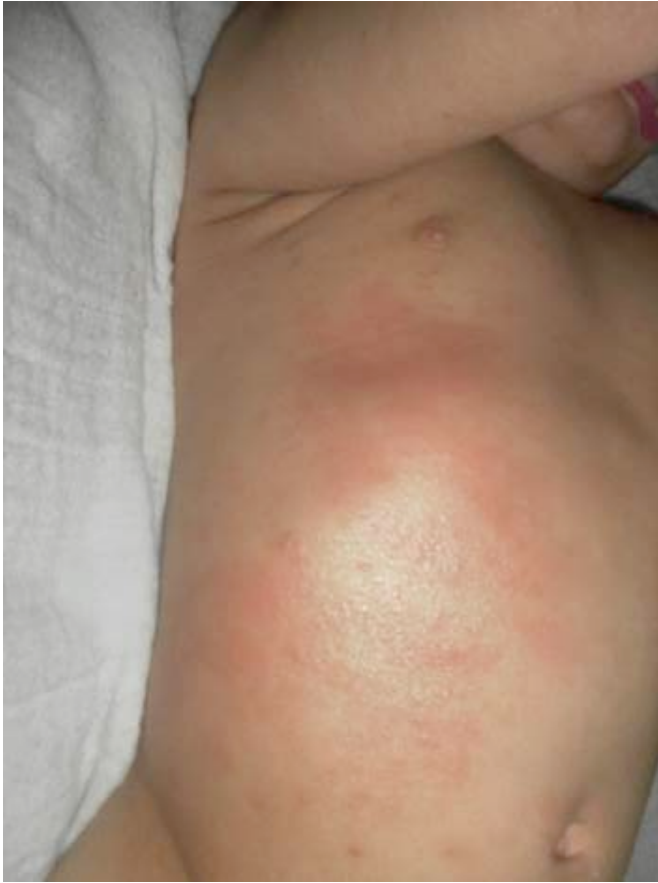Sleeps soundly through the night each night. No itching. No missed daycare. Very normal, happy toddler with beautiful skin!

Case study 42 (August 2015)

Female, aged almost 2 years when started on Aron Regimen

Prior to commencing Aron Regimen	Age when diagnosed with atopic eczema	3 months
	Under treatment of GP or Dermatologist prior to commencing Aron Regimen	Dermatologist
	Most recent treatment prior to commencing Aron Regimen (immunosuppressants: any time; rest: previous year)	Topical steroids: Myprocol Oral steroids: No Topical immunosuppressants: No Oral immunosuppressants: No Antihistamines: Yes
	Any hospital emergency or elective admissions related to atopic eczema since diagnosis? If yes, how many?	No
	Any absences from school due to eczema (other than clinic appointments)?	N/A
Since commencing Aron Regimen	Date started the Aron Regimen	April 2012
	Current treatment	August 2015: Skin completely clear in summer no use of mix. In winter skin is dry every second or third day on rough patches only. April 2013: Antibiotic removed Mix of steroid, antibiotic and moisturiser creams
	Any hospital emergency or elective admissions related to atopic eczema since commencing Aron Regimen?	No
	Any absences from school due to eczema (other than clinic appointments or initial week of Aron Regimen)?	N/A

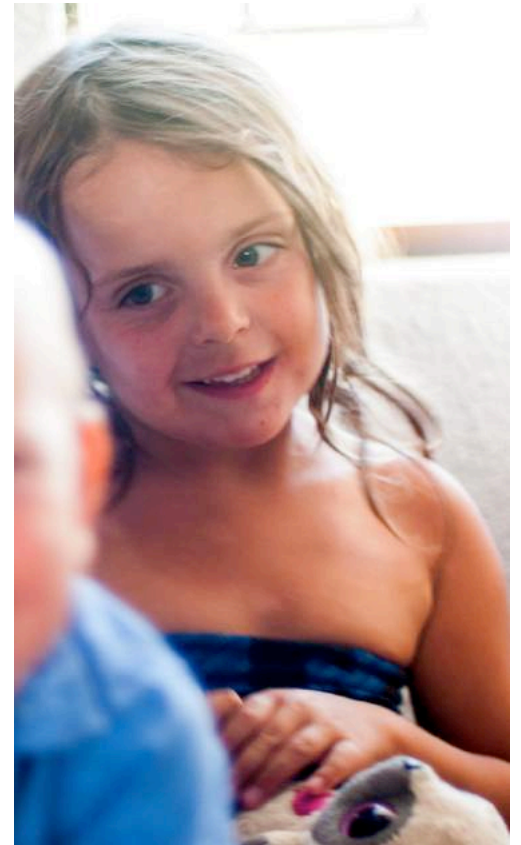
Case study 42 – female, aged almost 2 years
Photos before commencing Aron Regimen



Note from adult:

No sleep for 8 months. Bloody bed sheets and skin scratched away totally on whole body. No quality of life and no hair on head.

Case study 42 – female, aged almost 2 years
Photos after commencing Aron Regimen



Note from adult:

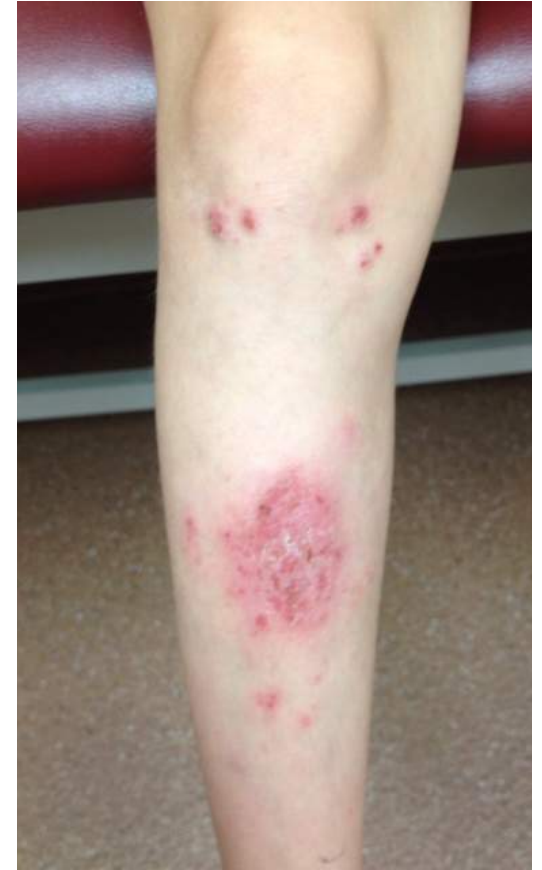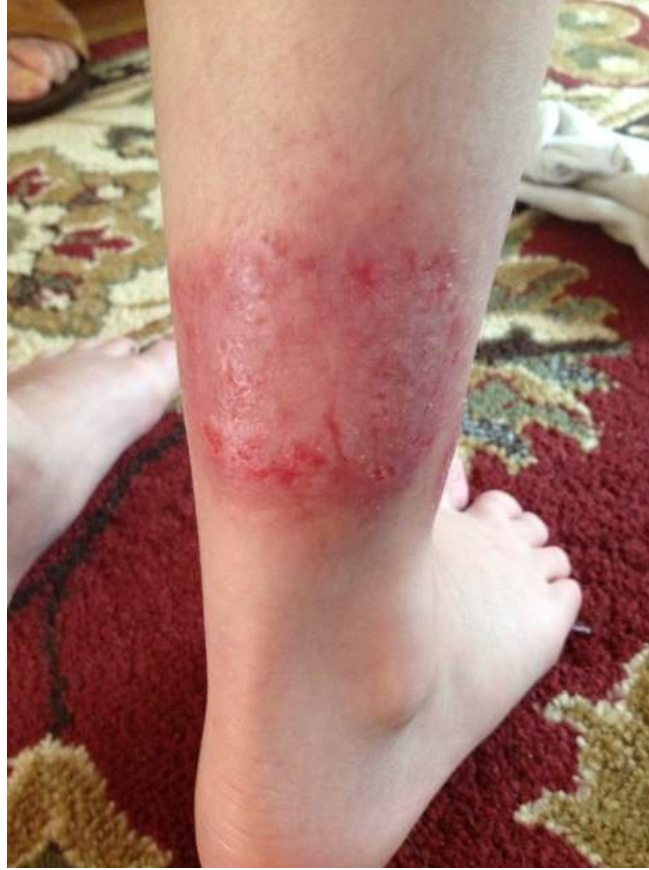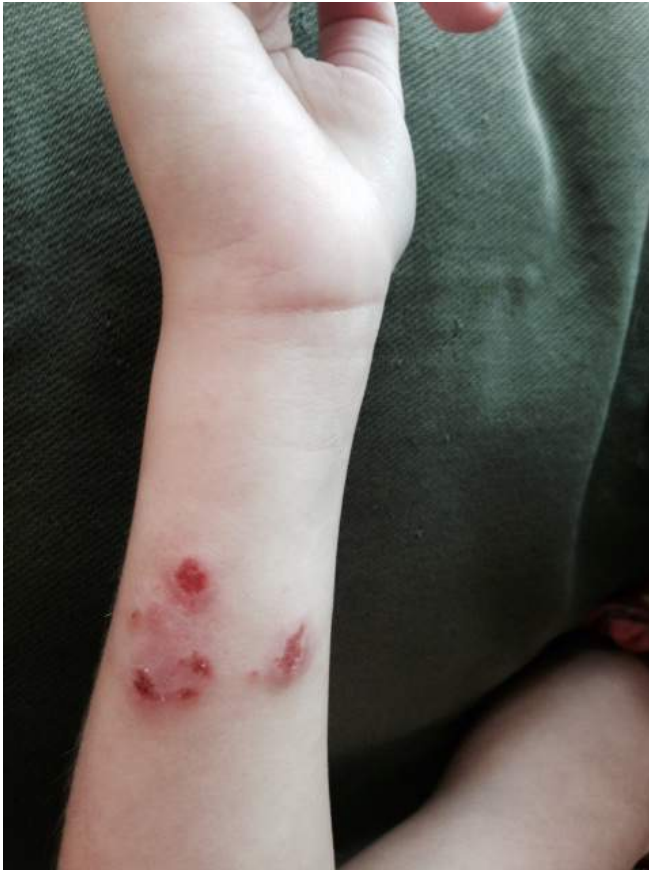She stopped scratching immediately. Slept through after 3 days of starting the treatment.

Case study 43 (August 2015)

Female, aged 7 years when started on Aron Regimen

Prior to commencing Aron Regimen	Age when diagnosed with atopic eczema	1 month
	Under treatment of GP or Dermatologist prior to commencing Aron Regimen	Dermatologist
	Most recent treatment prior to commencing Aron Regimen (immunosuppressants: any time; rest: previous year)	Topical steroids: Clobetasol, hydrocortisone valerate, triamcinolone, Halog, desonide Oral steroids: Yes Topical immunosuppressants: Yes, Elidel Oral immunosuppressants: No Antihistamines: Yes
	Any hospital emergency or elective admissions related to atopic eczema since diagnosis? If yes, how many?	No
	Any absences from school due to eczema (other than clinic appointments)?	Yes
Since commencing Aron Regimen	Date started the Aron Regimen	July 2014
	Current treatment	September 2017: Spot treatment on infrequent flares. Antibiotic/steroid only September 2016: Spot treatment in 4 small areas: 1-2 applications 4-5 x per week May 2015: Nothing now used, except if there is a flare, then 1-2 x daily on affected area only. Mix of steroid, antibiotic and moisturiser creams
	Any hospital emergency or elective admissions related to atopic eczema since commencing Aron Regimen?	No
	Any absences from school due to eczema (other than clinic appointments or initial week of Aron Regimen)?	No

Case study 43 – female, aged 7 years
Photos before commencing Aron Regimen

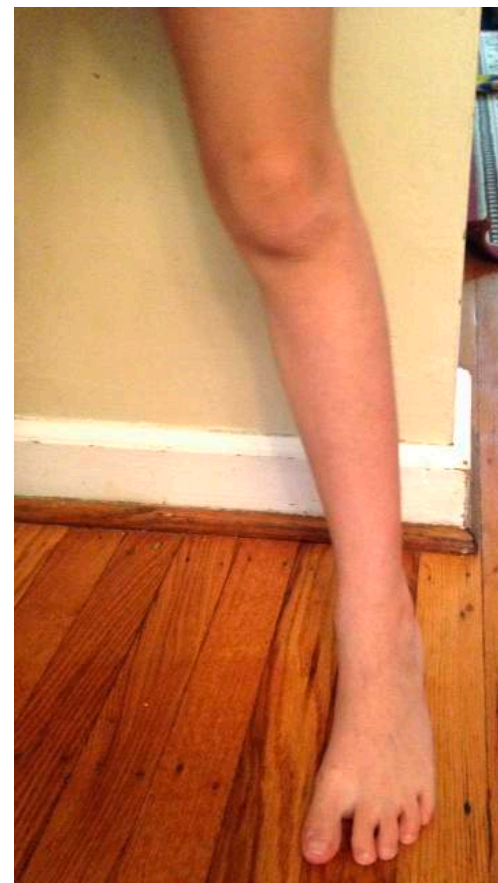
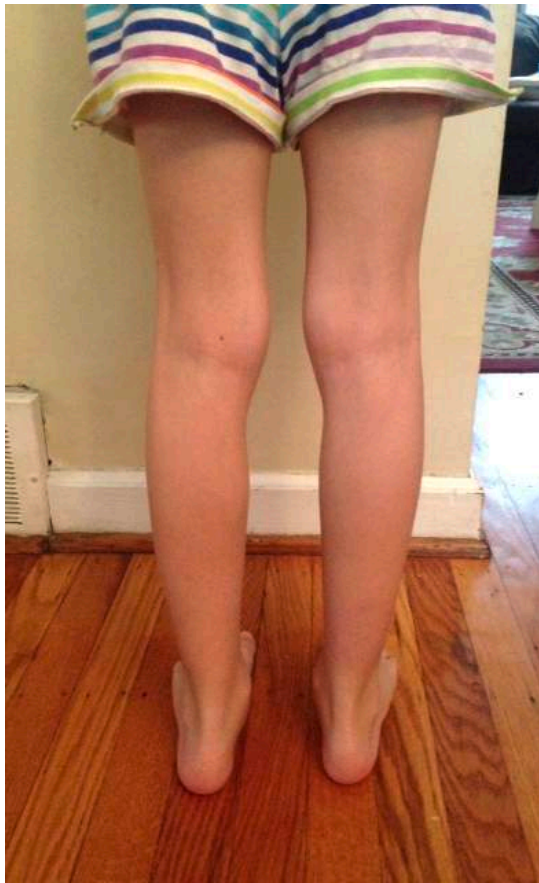
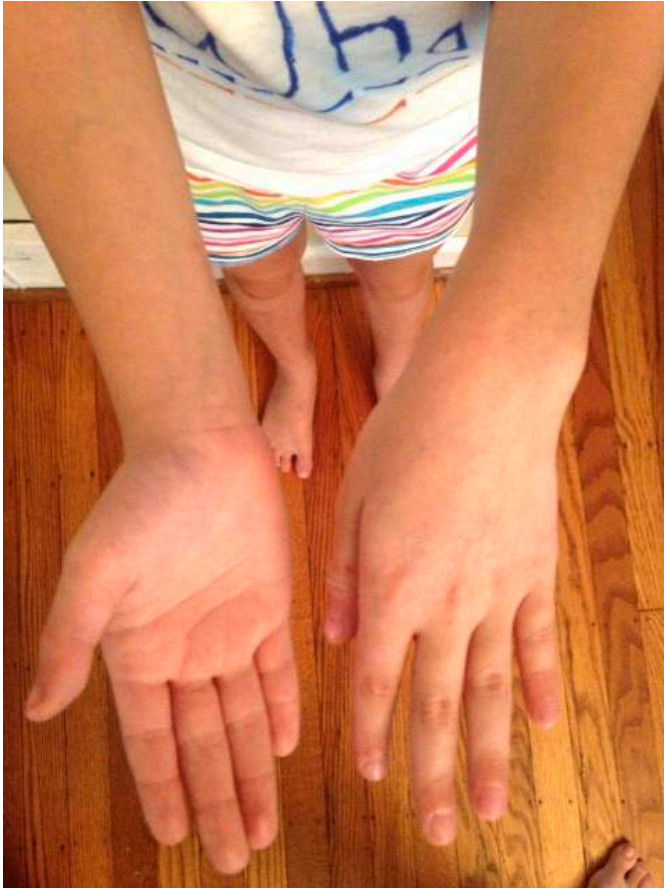
Note from adult:

Constant itching, infections and open patches prevented us from doing normal things such as the beach, pool, parks etc. She was also unable to wear normal kid attire such as shorts, skirts, flip flops and constantly was wrapped up in bandages.

Case study 43 – female, aged 7 years

Photos after commencing Aron Regimen



Note from adult:

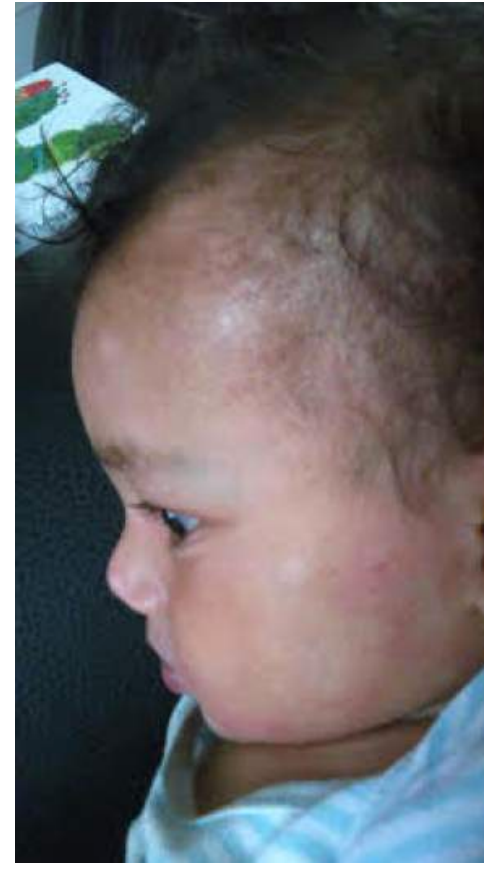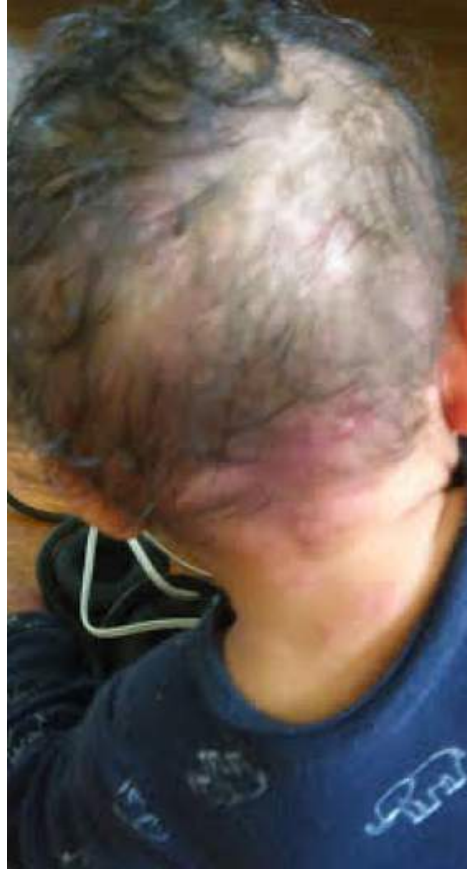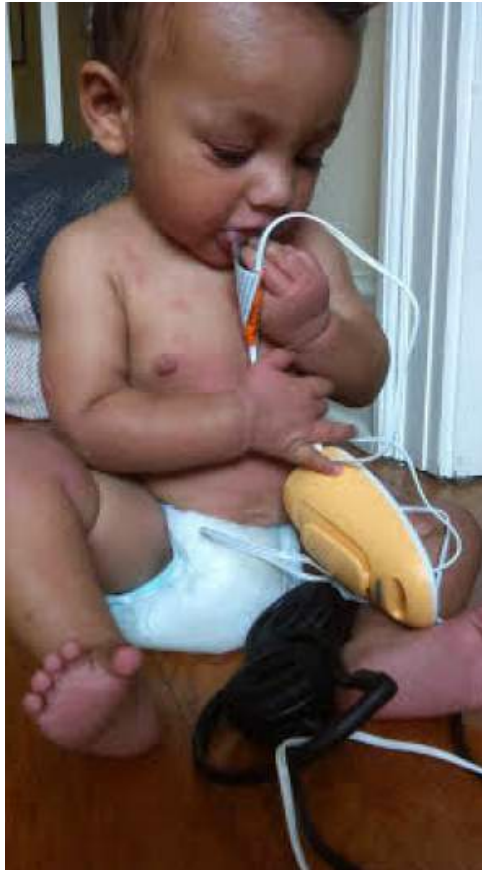Able to sleep, play sports, go swimming and to the beach/ park without itching and flaring up. Eczema really isn't a factor in our daily lives anymore, where as it ruled our lives the 7 years prior to this treatment.

Case study 44 (October 2015)

Male, aged 8 months when started on Aron Regimen

Prior to commencing Aron Regimen	Age when diagnosed with atopic eczema	2 months
	Under treatment of GP or Dermatologist prior to commencing Aron Regimen	GP
	Most recent treatment prior to commencing Aron Regimen (immunosuppressants: any time; rest: previous year)	Topical steroids: Hydrocortisone, Triamcinolone acetonide Oral steroids: No Topical immunosuppressants: Yes, Atarax Oral immunosuppressants: No Antihistamines: Yes
	Any hospital emergency or elective admissions related to atopic eczema since diagnosis? If yes, how many?	No
	Any absences from school due to eczema (other than clinic appointments)?	N/A
Since commencing Aron Regimen	Date started the Aron Regimen	Sept 2015
	Current treatment	September 2017: Only needed for flares now, no antibiotic September 2016: Still application every 2nd day March 2016: Application every 2nd day, antibiotic to be removed October 2015: 2 x daily Mix of steroid, antibiotic and moisturiser creams
	Any hospital emergency or elective admissions related to atopic eczema since commencing Aron Regimen?	No
	Any absences from school due to eczema (other than clinic appointments or initial week of Aron Regimen)?	N/A

Case study 44 – male, aged 8 months
Photos before commencing Aron Regimen



Note from adult:

No sleep and fatigue poor weight gain

Case study 44 – male, aged 8 months
Photos after commencing Aron Regimen



Note from adult:

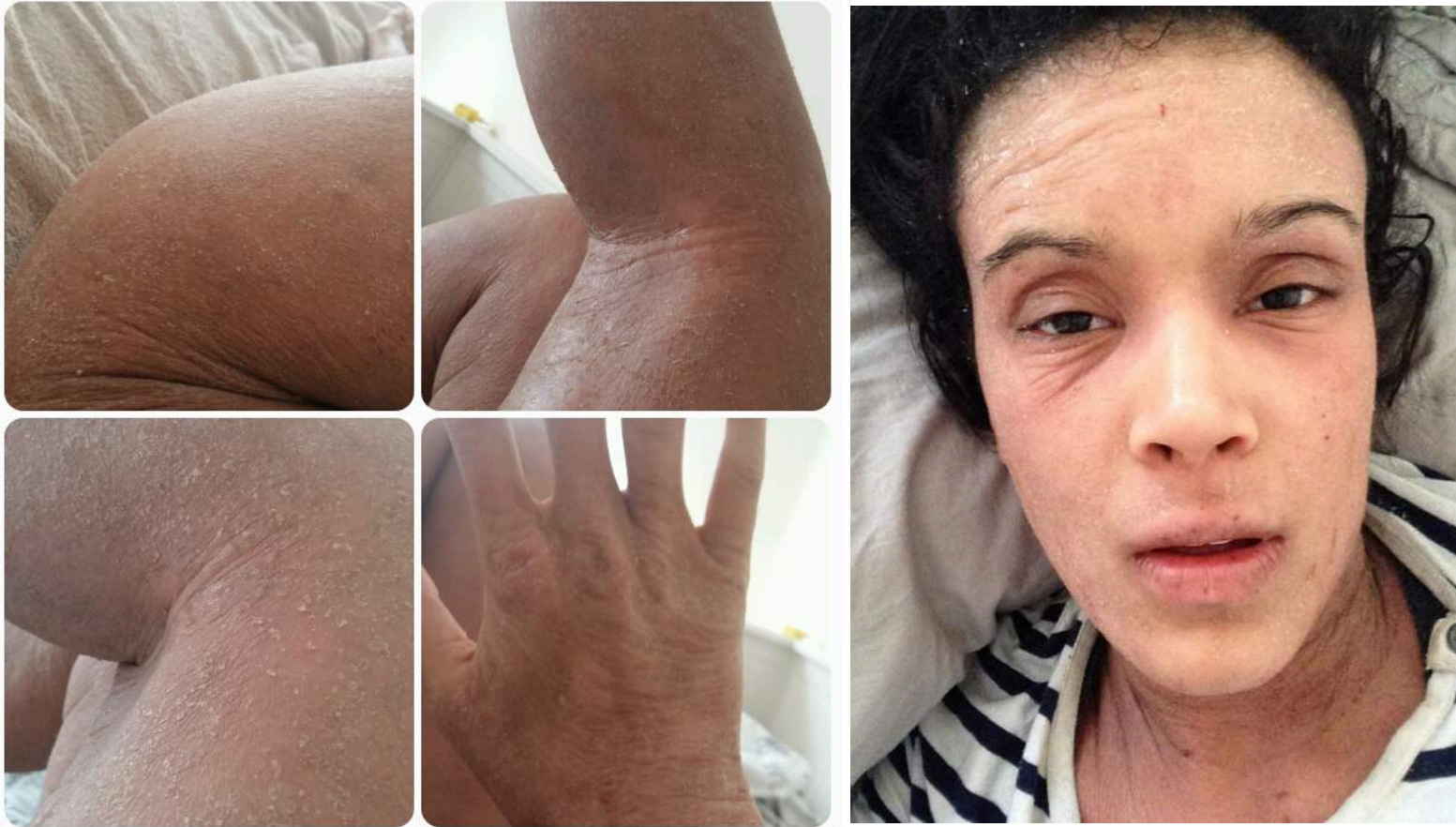Cheerful focused and happy

Case study 45 (November 2015)

Female, aged 24 years when started on Aron Regimen

Prior to commencing Aron Regimen	Age when diagnosed with atopic eczema	7 years
	Under treatment of GP or Dermatologist prior to commencing Aron Regimen	Dermatologist
	Most recent treatment prior to commencing Aron Regimen (immunosuppressants: any time; rest: previous year)	Topical steroids: Eumovate, elecon Oral steroids: No Topical immunosuppressants: Yes, Protopic 0.1% and 0.03% Oral immunosuppressants: No Antihistamines: Yes
	Any hospital emergency or elective admissions related to atopic eczema since diagnosis? If yes, how many?	Yes – 1 admission
	Any absences from school/or missing days of work, (other than clinic appointments)?	Yes
Since commencing Aron Regimen	Date started the Aron Regimen	July 2015
	Current treatment	September 2017: spot treating on body, face and neck 1 app every 2 days September 2016: 1 application per week on body, max 2 applications per week on face March 2016: 1 application every 2 nd day November 2015: Face: 1 application per day. Body: 2 application per day. Also body and face 2 x extra applications of just Diprobase Mix of steroid, antibiotic and moisturiser creams
	Any hospital emergency or elective admissions related to atopic eczema since commencing Aron Regimen?	No
	Any absences from school/or missing days of work due to eczema (other than clinic appointments or initial week of Aron Regimen)?	No

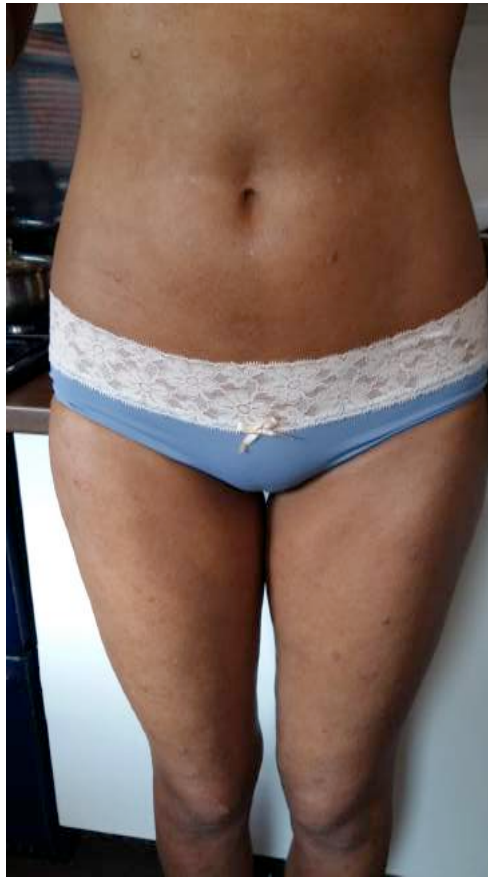Case study 45 – female, aged 24 years
Photos before commencing Aron Regimen



Note from adult:

Before Dr A, no more than 3/4 hours sleep a night. Constant itching and deep pain. Pain showering and dressing.

Case study 45 – female, aged 24 years
Photos after commencing Aron Regimen



Note from adult:

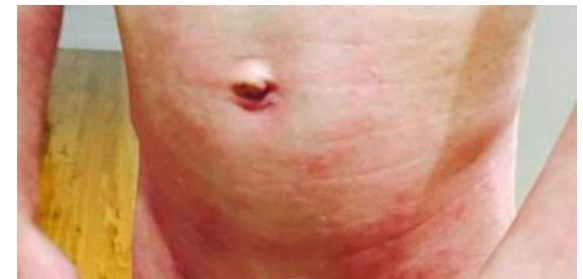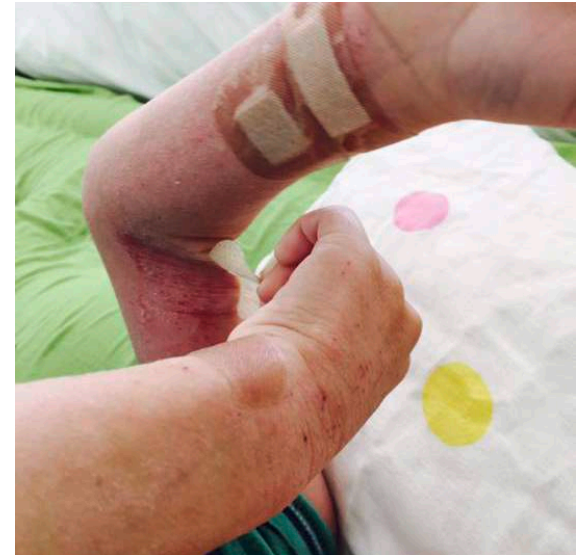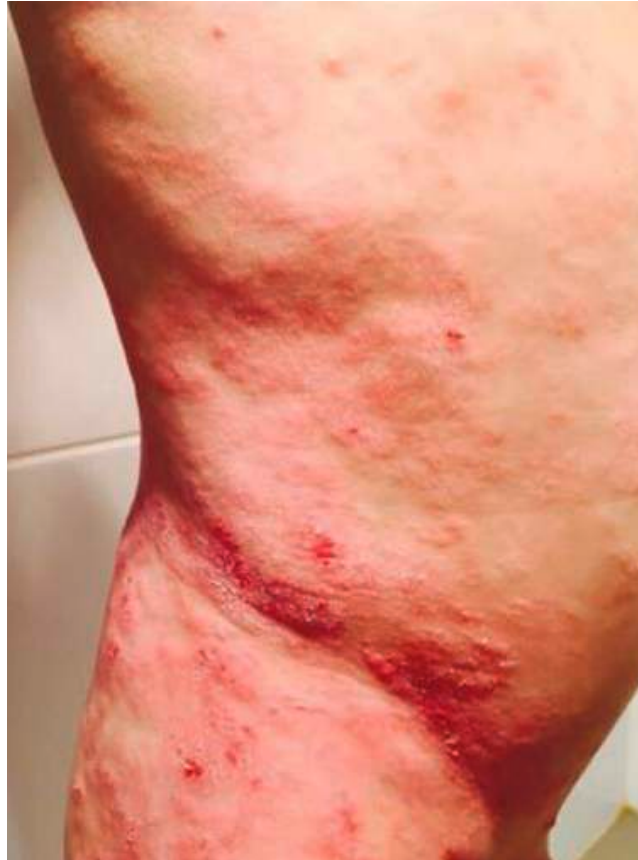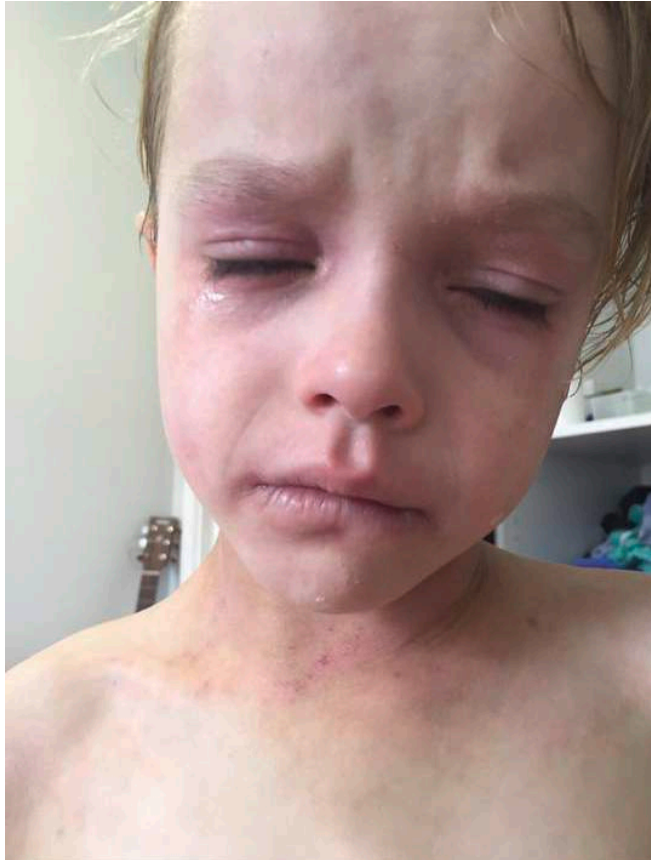FULL LONG nights sleep. No pain, bleeding, oozing, dryness or discomfort. Sporadic mild itching. So so happy and excited for life. Stubborn parts are still scarred but healing well.

Case study 46 (December 2015)

Male, aged 5 years when started on Aron Regimen

Prior to commencing Aron Regimen	Age when diagnosed with atopic eczema	9 months old
	Under treatment of GP or Dermatologist prior to commencing Aron Regimen	GP, Clinical immunologist and Paediatric immunologist
	Most recent treatment prior to commencing Aron Regimen (immunosuppressants: any time; rest: previous year)	Topical steroids: Advantan Fatty Ointment on body Elidel on face Oral steroids: Yes Topical immunosuppressants: Yes Oral immunosuppressants: Yes, Redipred Antihistamines: Yes
	Any hospital emergency or elective admissions related to atopic eczema since diagnosis? If yes, how many?	Yes – 1 admission
	Any absences from school/or missing days of work, (other than clinic appointments)?	Yes
Since commencing Aron Regimen	Date started the Aron Regimen	Oct 2015
	Current treatment	September 2017: 1 application per day September 2016: 2 applications per day March 2016: 3 applications per day December 2015: 4 applications per day Mix of steroid, antibiotic and moisturiser creams
	Any hospital emergency or elective admissions related to atopic eczema since commencing Aron Regimen?	No
	Any absences from school/or missing days of work due to eczema (other than clinic appointments or initial week of Aron Regimen)?	No

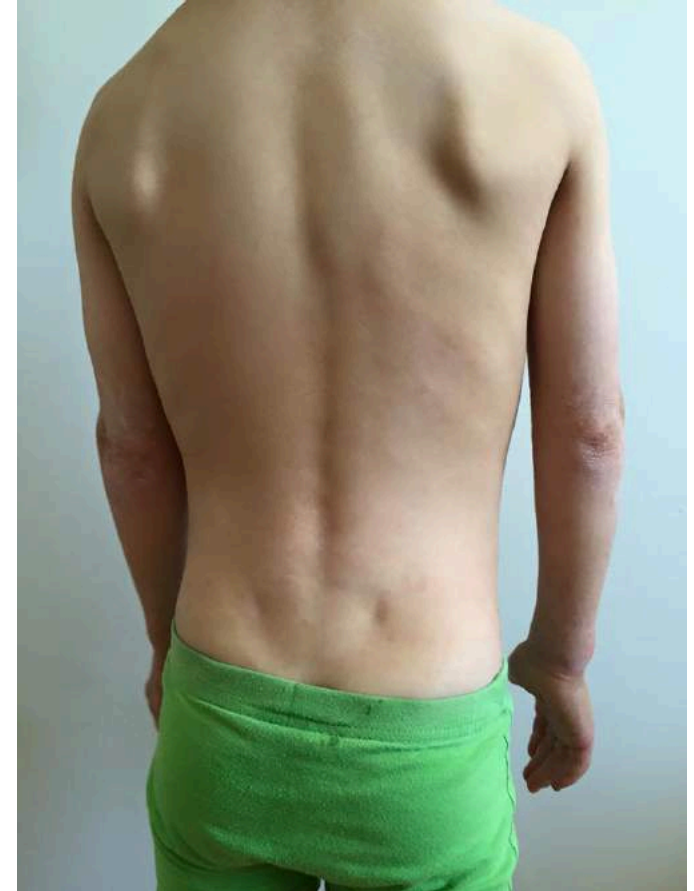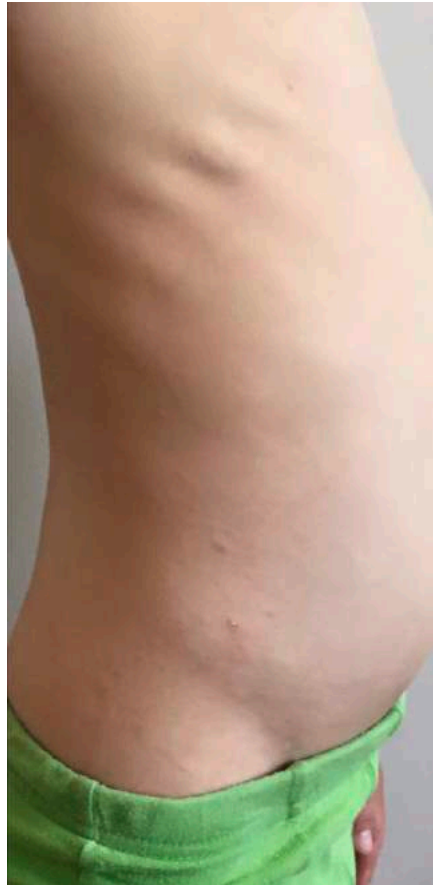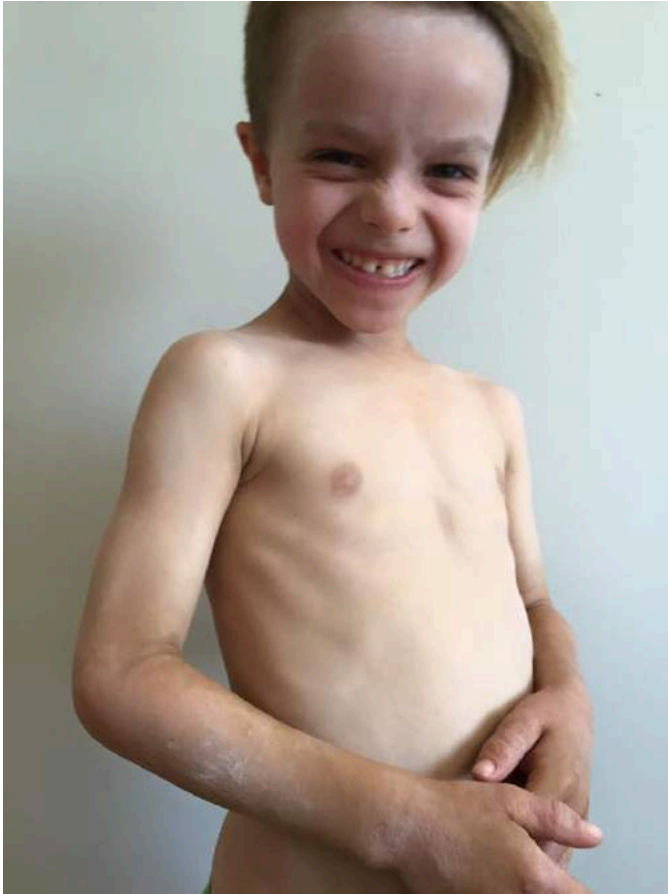Case study 46 – male, aged 5 years
Photos before commencing Aron Regimen



Note from adult:

No quality of life. Worst thing I've ever been through as a parent.

Case study 46 – male, aged 5 years
Photos after commencing Aron Regimen



Note from adult:

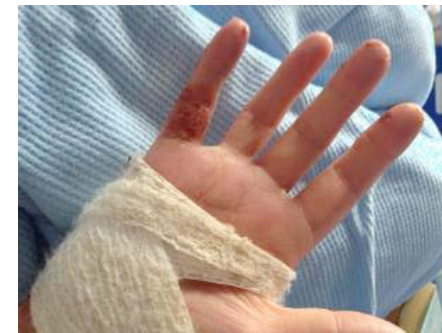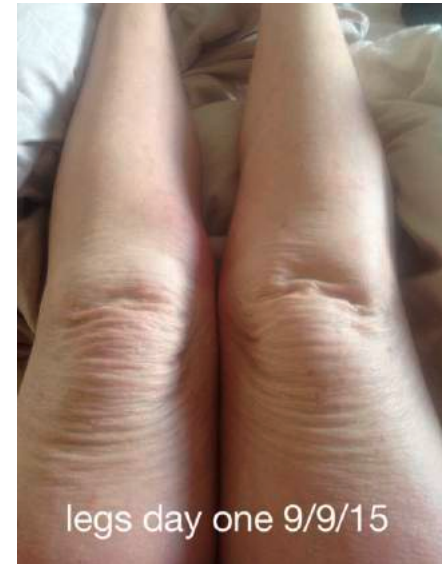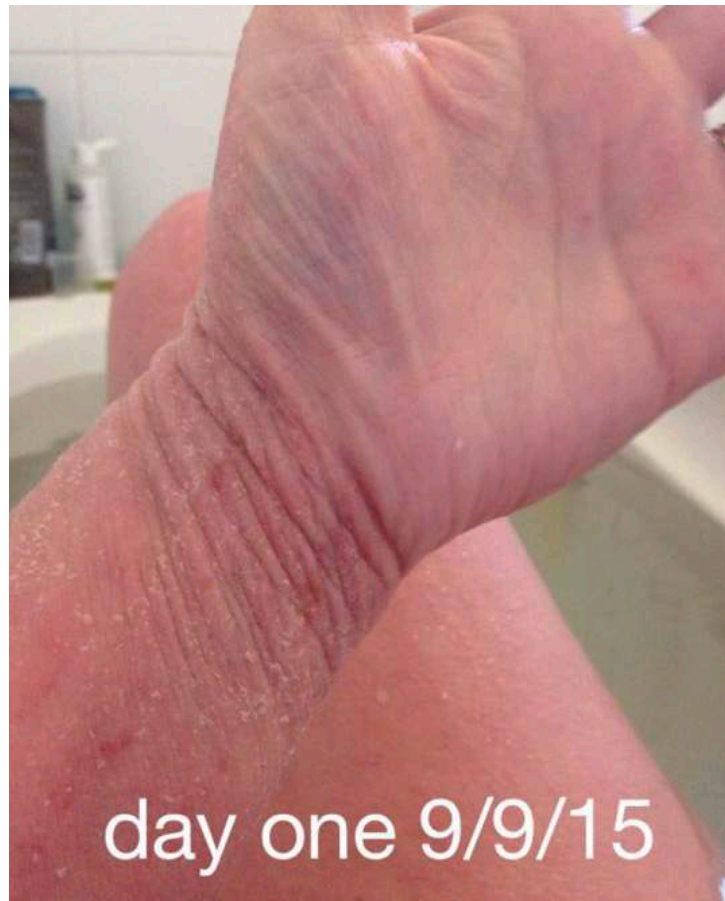Itch has now stopped for the first time in my son's entire life. He is now able to function & isn't constantly controlled by eczema. It's a miracle.

Case study 47 (January 2016)

Female, aged 32 years when started on Aron Regimen

Prior to commencing Aron Regimen	Age when diagnosed with atopic eczema	6 months old
	Under treatment of GP or Dermatologist prior to commencing Aron Regimen	Dermatologist
	Most recent treatment prior to commencing Aron Regimen (immunosuppressants: any time; rest: previous year)	Topical steroids: Dermovate Betnovate Eumovate Diprosone Hydrocortisone Oral steroids: Yes Topical immunosuppressants: Yes, Protopic Oral immunosuppressants: Yes Antihistamines: Yes
	Any hospital emergency or elective admissions related to atopic eczema since diagnosis? If yes, how many?	Yes – 4 or more admission
	Any absences from school/or missing days of work, (other than clinic appointments)?	Yes
Since commencing Aron Regimen	Date started the Aron Regimen	Sept 2015
	Current treatment	September 2017: 1 app every 10 days to hands arms and lower face. Not needed on torso or legs for months now. September 2016: 1 application per week March 2016: 1 application per day to face, arms and ankles; every 2 nd day to legs and torso, 2 applications to hands per day January 2016: 2 applications per day Mix of steroid, antibiotic and moisturiser creams
	Any hospital emergency or elective admissions related to atopic eczema since commencing Aron Regimen?	No
	Any absences from school/or missing days of work due to eczema (other than clinic appointments or initial week of Aron Regimen)?	No

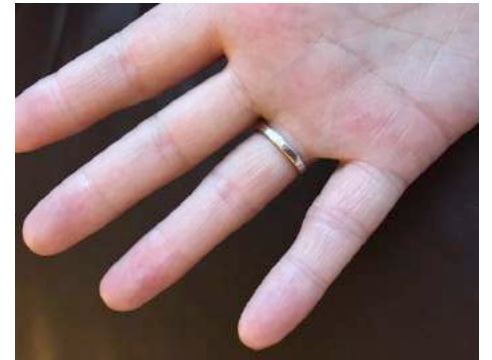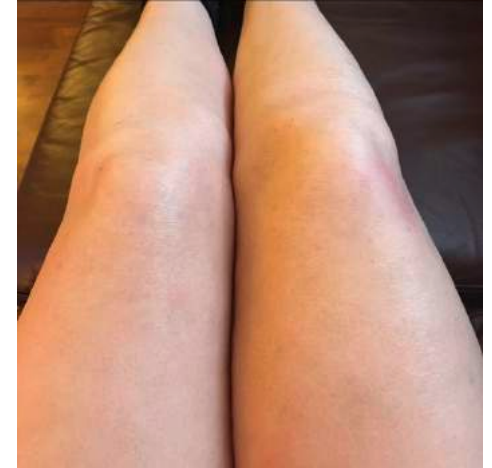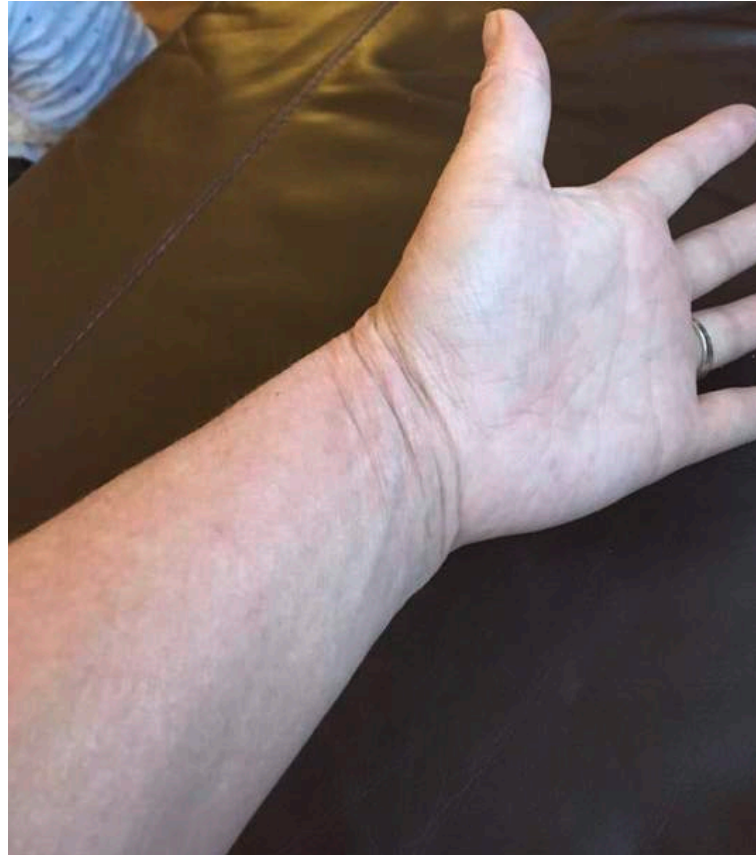Case study 47 – female, aged 32 years
Photos before commencing Aron Regimen



Note from adult:

Massively impactful. Lack of sleep due to incessant itch. Weeping skin and tremors. Always feeling cold and generally unwell. Unable to pick up twin babies due to cracked and bleeding fingers. Depression.

Case study 47 – female, aged 32 years
Photos after commencing Aron Regimen



Note from adult:

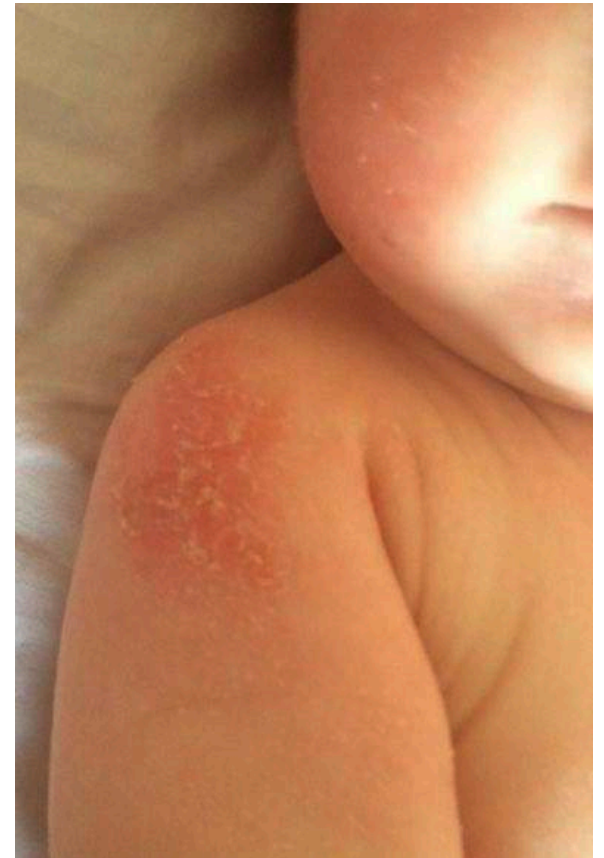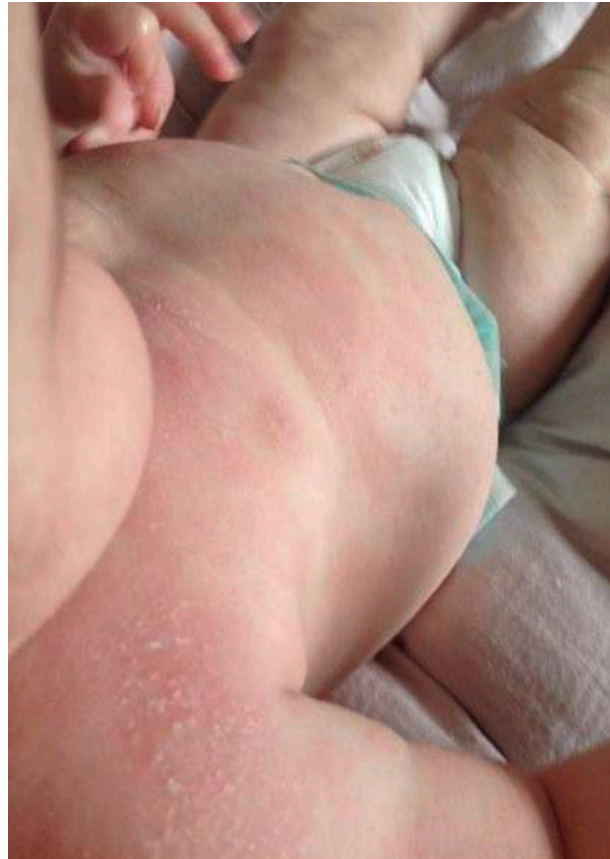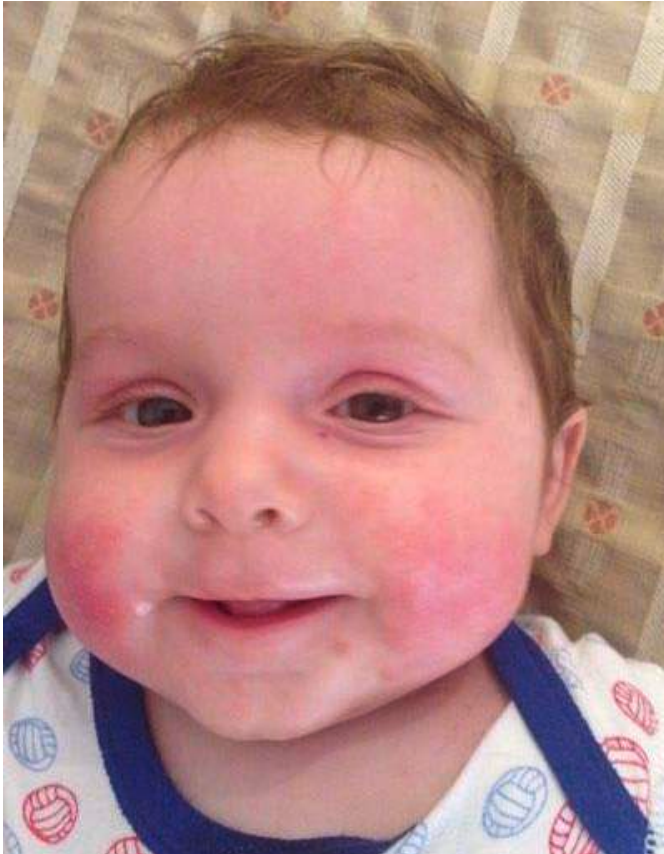Life changing. Living an eczema free existence. Quality sleep. No oral meds AT ALL. Minimal itch and only when in contact with known allergen. Much much happier.

Case study 48 (January 2016)

Male, aged 7 months when started on Aron Regimen

Prior to commencing Aron Regimen	Age when diagnosed with atopic eczema	4 months old
	Under treatment of GP or Dermatologist prior to commencing Aron Regimen	GP
	Most recent treatment prior to commencing Aron Regimen (immunosuppressants: any time; rest: previous year)	Topical steroids: None Oral steroids: No Topical immunosuppressants: No Oral immunosuppressants: No Antihistamines: Yes
	Any hospital emergency or elective admissions related to atopic eczema since diagnosis? If yes, how many?	No
	Any absences from school/or missing days of work, (other than clinic appointments)?	N/A
Since commencing Aron Regimen	Date started the Aron Regimen	Sept 2015
	Current treatment	September 2017: 2 apps per day of neat antibiotic and steroid for now September 2016: 2 applications per day January 2016: 2 applications per day Mix of steroid, antibiotic and moisturiser creams
	Any hospital emergency or elective admissions related to atopic eczema since commencing Aron Regimen?	No
	Any absences from school/or missing days of work due to eczema (other than clinic appointments or initial week of Aron Regimen)?	N/A

Case study 48 – male, aged 7 months
Photos before commencing Aron Regimen

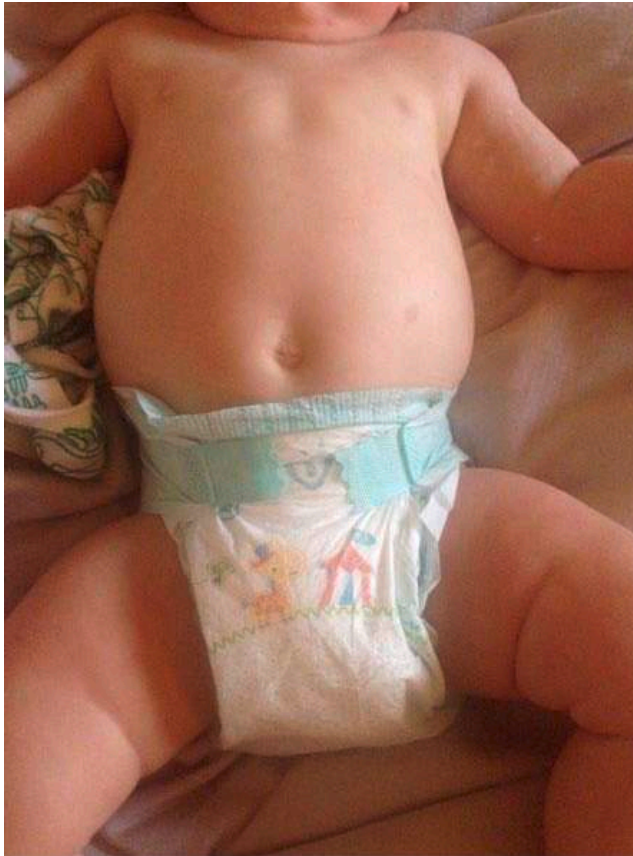


Note from adult:

Eczema developed after ceasing breastfeeding. Started off as dry coarse skin. Developed into large patches of red flaky (sometimes weepy sores. Big red patches on cheeks.

Case study 48 – male, aged 7 months

Photos after commencing Aron Regimen



Note from adult:

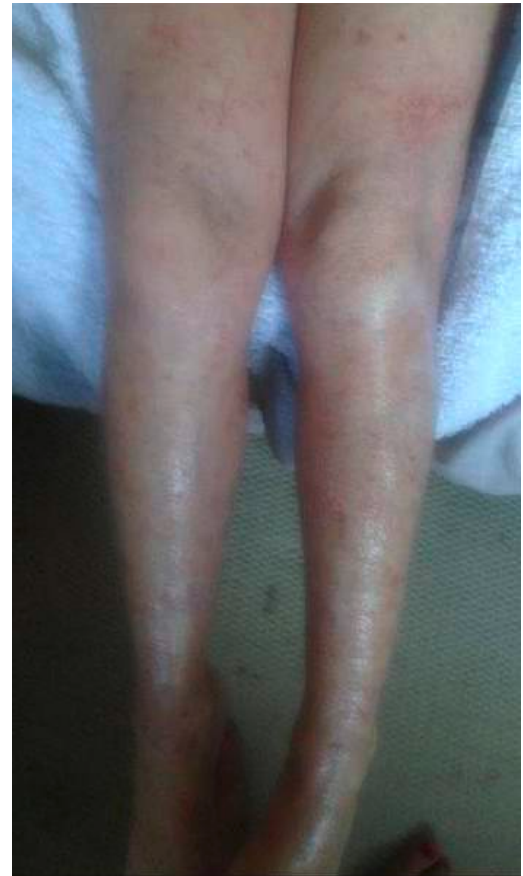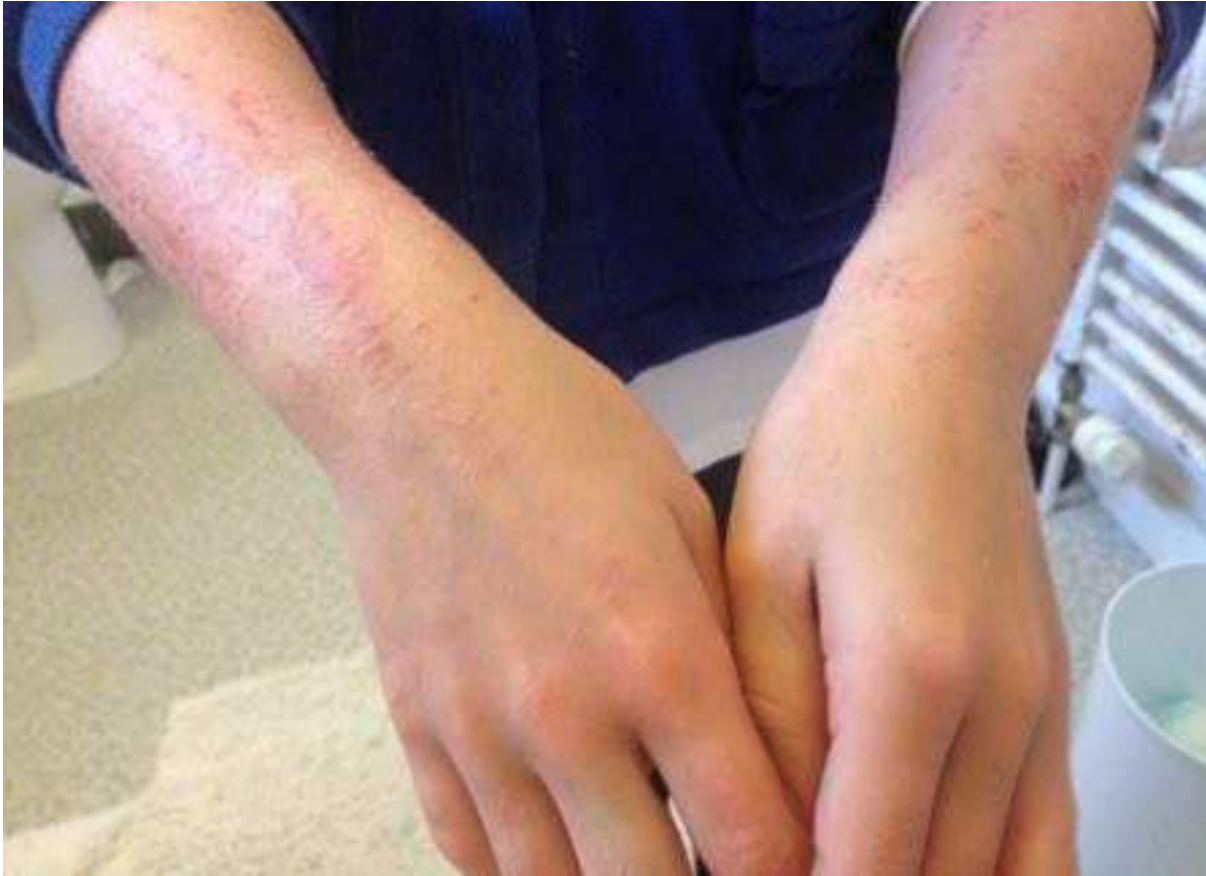Skin is calm and clear. His whole personality seemed to calm as he is less irritable. Still gets small patches on cheeks when teething/unwell. Sleeps soundly. No scratching at all! Happy baby :)

Case study 49 (January 2016)

Female, aged 3 years when started on Aron Regimen

Prior to commencing Aron Regimen	Age when diagnosed with atopic eczema	3 years old
	Under treatment of GP or Dermatologist prior to commencing Aron Regimen	GP
	Most recent treatment prior to commencing Aron Regimen (immunosuppressants: any time; rest: previous year)	Topical steroids: Eumovate, Hydrocortisone, Betnovate Oral steroids: Yes Topical immunosuppressants: No Oral immunosuppressants: No Antihistamines: Yes
	Any hospital emergency or elective admissions related to atopic eczema since diagnosis? If yes, how many?	No
	Any absences from school/or missing days of work, (other than clinic appointments)?	N/A
Since commencing Aron Regimen	Date started the Aron Regimen	Sept 2015
	Current treatment	September 2017: Currently flaring so on 3 apps per day (was on 1 app per day ankles and wrists only) September 2016: 2 applications per day March 2016: no Fucibet required now January 2016: 2 applications per day. Steroid/antibiotic for feet Mix of steroid, antibiotic and moisturiser creams
	Any hospital emergency or elective admissions related to atopic eczema since commencing Aron Regimen?	No
	Any absences from school/or missing days of work due to eczema (other than clinic appointments or initial week of Aron Regimen)?	N/A

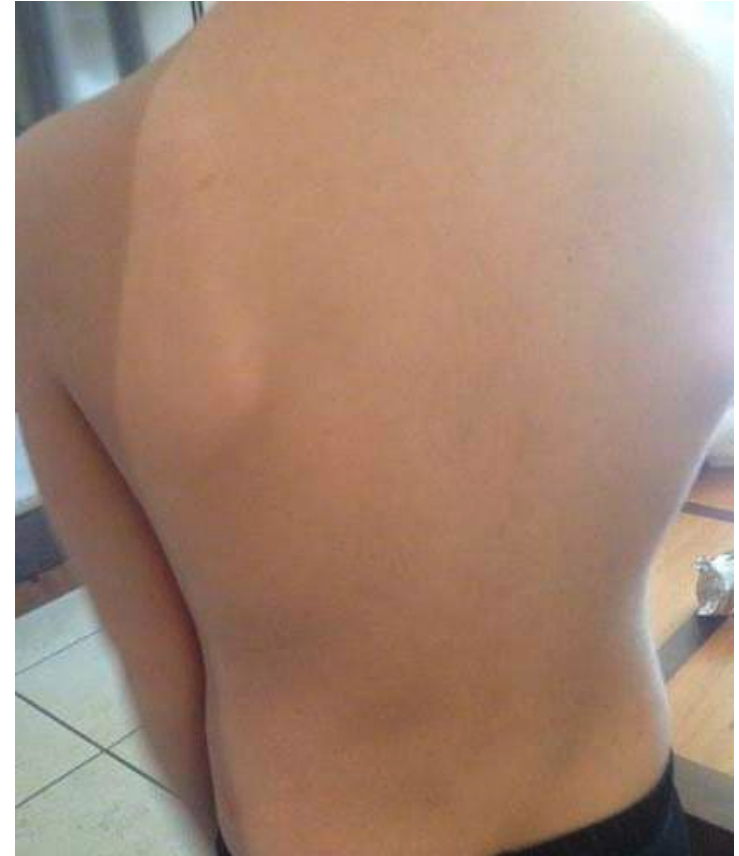
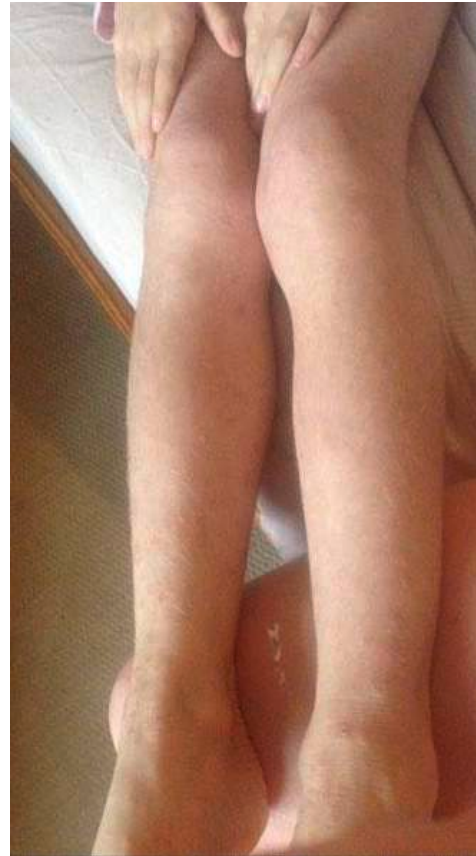Case study 49 – female, aged 3 years
Photos before commencing Aron Regimen



Note from adult:

Sophia was really miserable and down with her eczema. itchy sleepless nights. Used scratch sleeves and daily antihistamines. Never sat still. Always scratching. Very shy and worried about people looking.

Case study 49 – female, aged 3 years
Photos after commencing Aron Regimen



Note from adult:

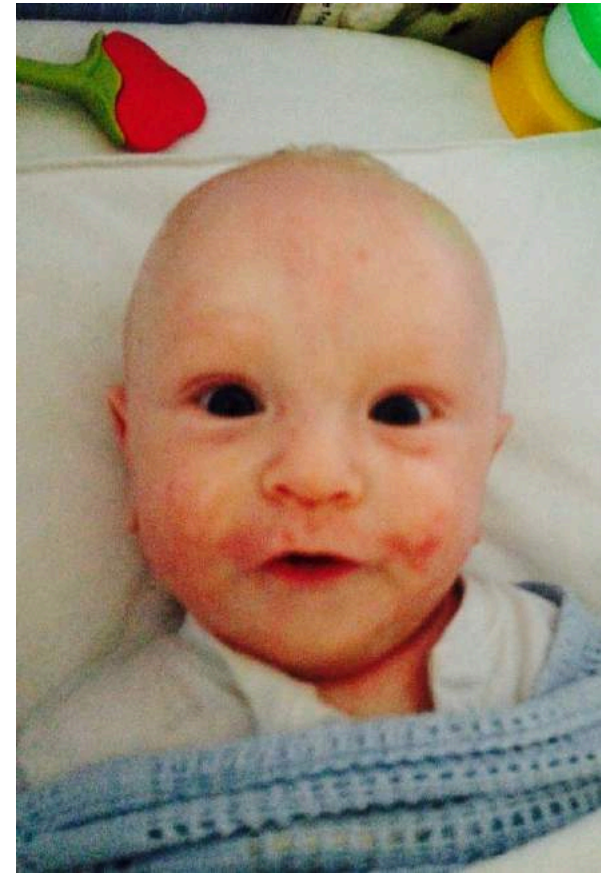
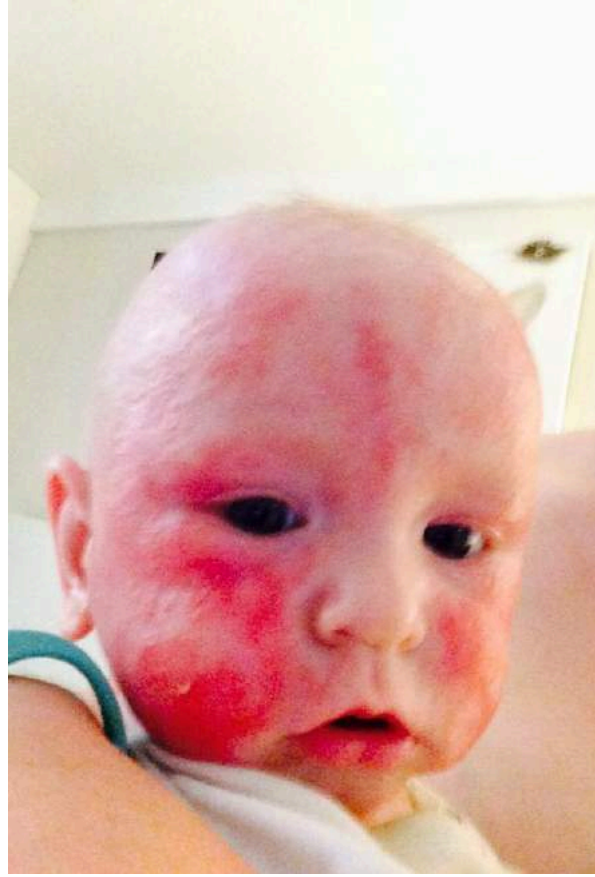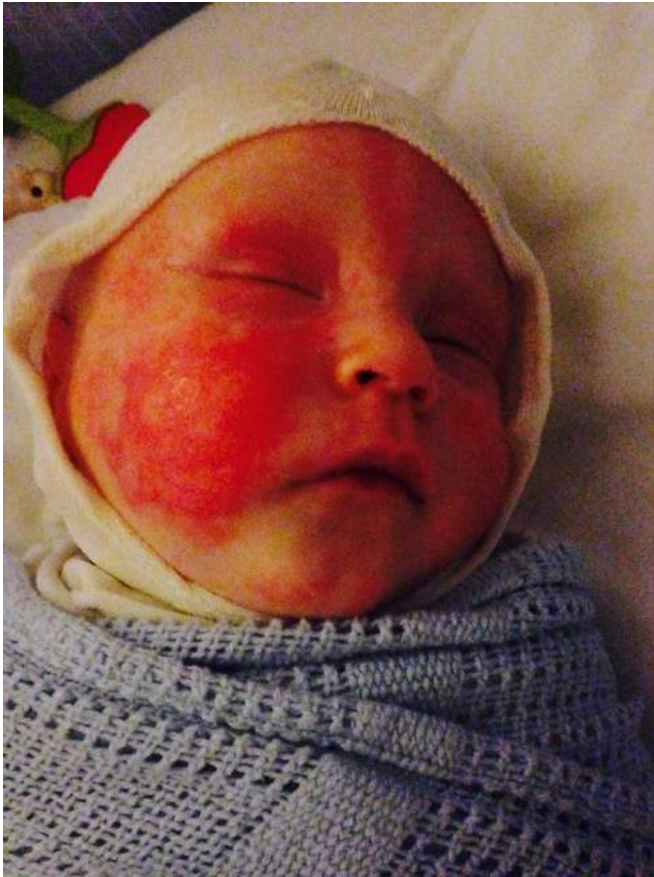Slept through from first night! Barely itches anymore. No antihistamine anymore. Confident and very happy little girl :)

Case study 50 (January 2016)

Male, aged 6 months when started on Aron Regimen

Prior to commencing Aron Regimen	Age when diagnosed with atopic eczema	2 months old
	Under treatment of GP or Dermatologist prior to commencing Aron Regimen	Dermatologist
	Most recent treatment prior to commencing Aron Regimen (immunosuppressants: any time; rest: previous year)	Topical steroids: Hydrocortisone 1 % Oral steroids: No Topical immunosuppressants: No Oral immunosuppressants: No Antihistamines: Yes
	Any hospital emergency or elective admissions related to atopic eczema since diagnosis? If yes, how many?	No
	Any absences from school/or missing days of work, (other than clinic appointments)?	N/A
Since commencing Aron Regimen	Date started the Aron Regimen	Sept 2015
	Current treatment	September 2017: 2 x apps per day, starting to settle now summer is ending September 2016: spot treating 1-2 x per day January 2016: 1 application per day, stubborn areas only Mix of steroid, antibiotic and moisturiser creams
	Any hospital emergency or elective admissions related to atopic eczema since commencing Aron Regimen?	No
	Any absences from school/or missing days of work due to eczema (other than clinic appointments or initial week of Aron Regimen)?	N/A

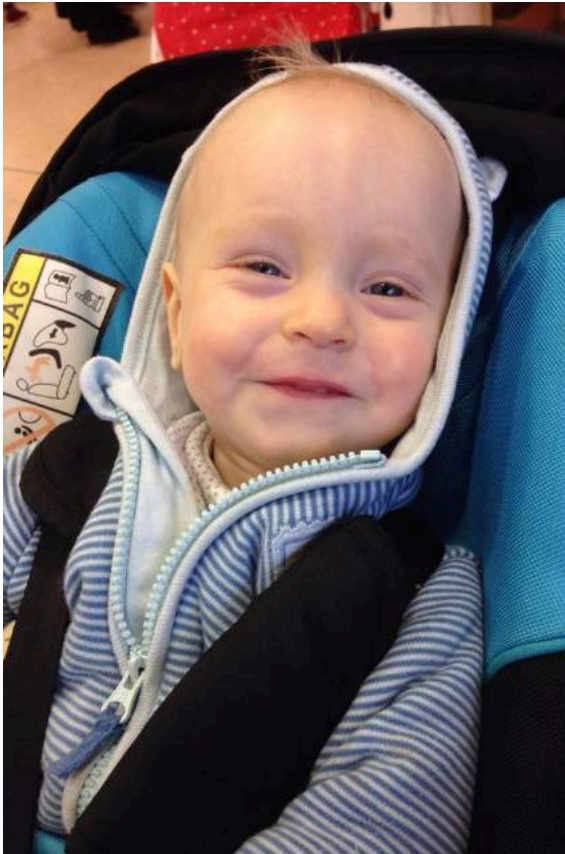
Case study 50 – male, aged 6 months
Photos before commencing Aron Regimen



Note from adult:

As parents were stressed, arguing and sleep deprived. Our son was constantly itching and grumpy and would flare at anything it seemed, his skin regime took up hours and we were afraid to go out the house.

Case study 50 – male, aged 6 months
Photos after commencing Aron Regimen



Note from adult:

Happy family with a happy itch free child with minimal small flares. We can all lead a normal life now.

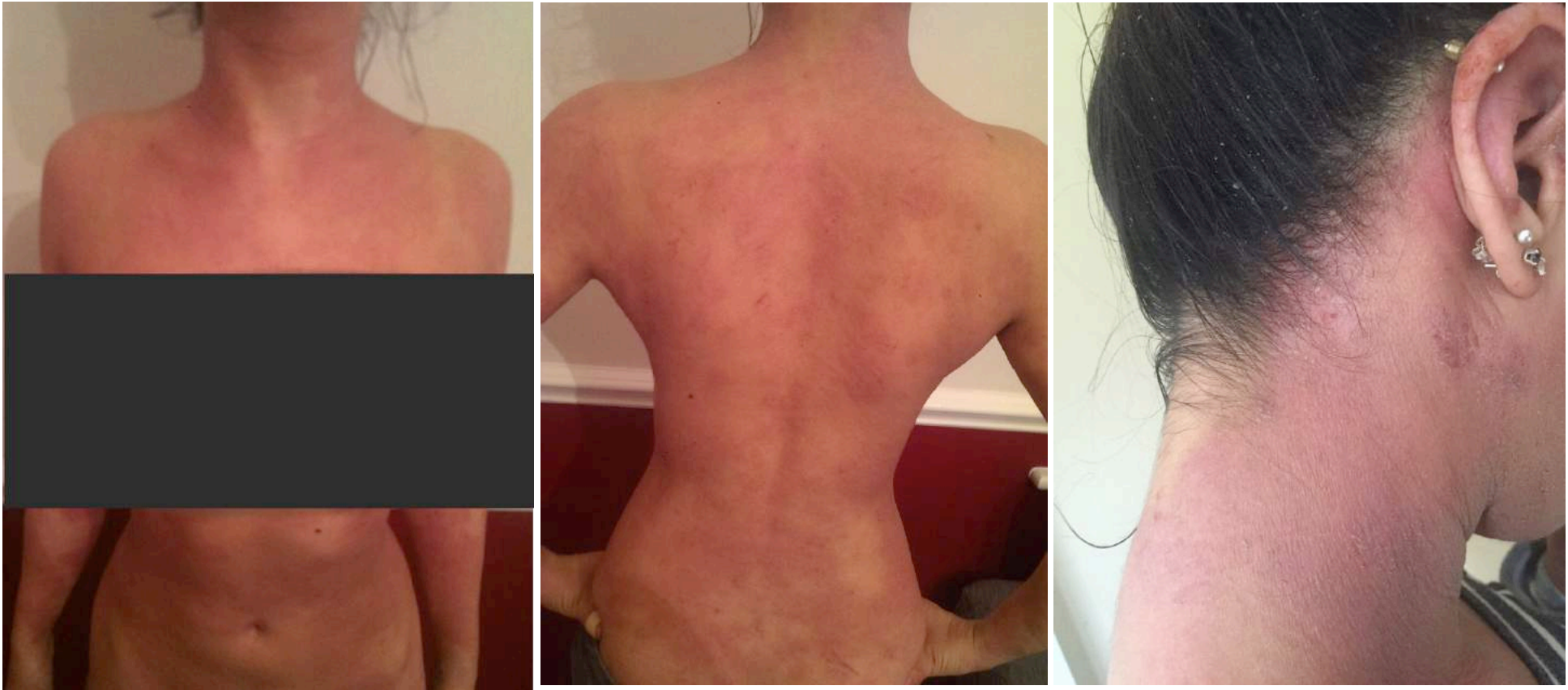Case study 51 (June 2016)

Female, aged 24 years when started on Aron Regimen

Prior to commencing Aron Regimen	Age when diagnosed with atopic eczema	19 years old
	Under treatment of GP or Dermatologist prior to commencing Aron Regimen	Dermatologist
	Most recent treatment prior to commencing Aron Regimen (immunosuppressants: any time; rest: previous year)	Topical steroids: No Oral steroids: No Topical immunosuppressants: Protopic 0.1% 2x daily for 4 years Oral immunosuppressants: No Antihistamines: Yes
	Any hospital emergency or elective admissions related to atopic eczema since diagnosis? If yes, how many?	No
	Any absences from school/or missing days of work, (other than clinic appointments)?	Yes
Since commencing Aron Regimen	Date started the Aron Regimen	May 2015
	Current treatment	September 2017: Every 3 weeks on legs, once x per week on scalp and 1 x app daily everywhere else September 2016: Legs and face: once every other day ; Stomach, chest and back: 1x a day; 1-1-2 on arms; 2 apps on neck; Protopic on forehead: 1x a day; steroid on scalp: every 7-9 days; Trimovate on groin and mouth: 2x a day June 2016: Legs and face: once every other day Stomach, chest and back: 1x a day ; Arms and neck: 2x a day; Protopic on forehead: 1x a day; Steroid on scalp: once every 3 days Trimovate on groin and mouth: 2x a day Mix of steroid, antibiotic and moisturiser creams
	Any hospital emergency or elective admissions related to atopic eczema since commencing Aron Regimen?	No
	Any absences from school/or missing days of work due to eczema (other than clinic appointments or initial week of Aron Regimen)?	No

Case study 51 – female, aged 25 years

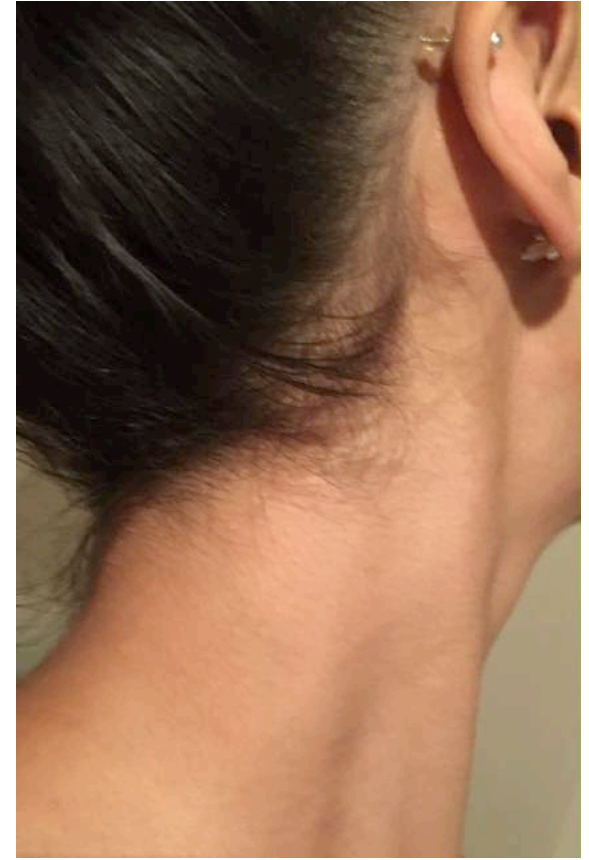
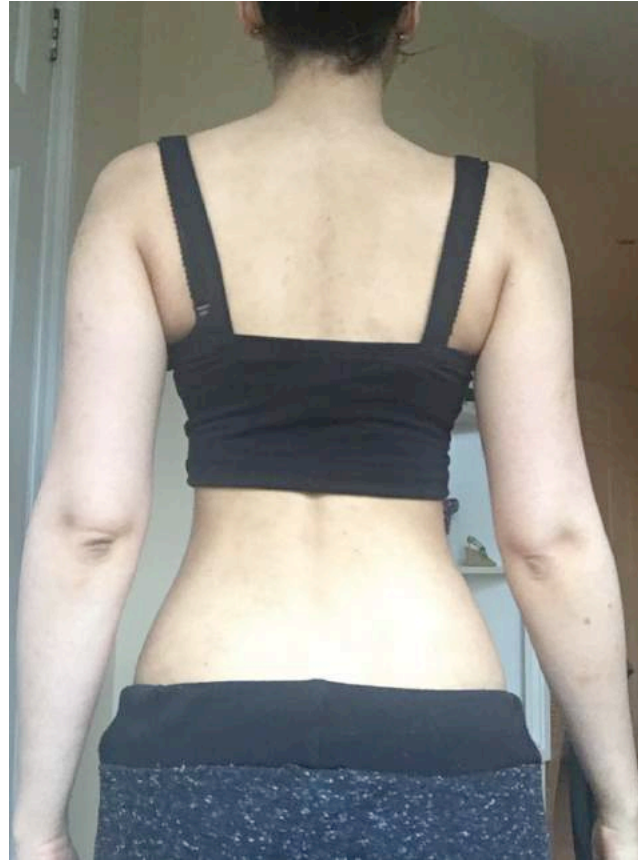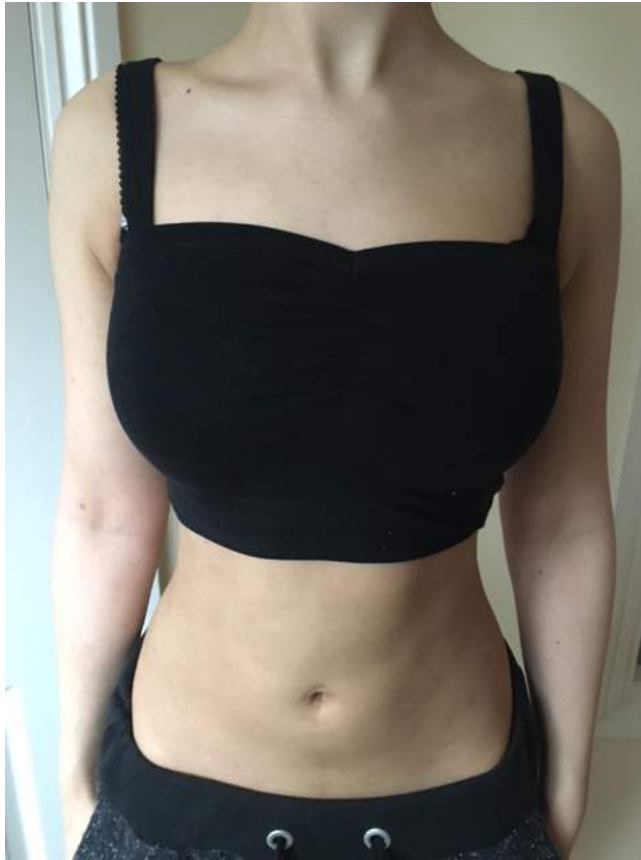Photos before commencing Aron Regimen



Note from adult:

I was a mess; I was constantly in agony, depressed, aqua-phobic and regularly going to work on 1 hour of sleep. Feeling so disfigured shattered my self-esteem, so much so that I struggled to even make eye contact with 'normal' people.

Case study 51 – female, aged 25 years
Photos after commencing Aron Regimen



Note from adult:

Life is worth living again! I no longer itch, no longer struggle to sleep, no longer sob in the shower, no longer have to use a towel to soak up weeping... I no longer worry about my skin!